

Original Article



Diagnostic value of integrated ^{18}F -fluoro-2-deoxyglucose positron emission tomography/computed tomography in recurrent epithelial ovarian cancer: accuracy of patient selection for secondary cytoreduction in 134 patients

OPEN ACCESS

Received: Sep 26, 2017

Revised: Dec 27, 2017

Accepted: Jan 26, 2018

Correspondence to

Yong-Man Kim

Department of Obstetrics and Gynecology,
University of Ulsan College of Medicine,
Asan Medical Center, 88 Olympic-ro 43-gil,
Songpa-gu, Seoul 05505, Korea.
E-mail: amcymkim@gmail.com

Copyright © 2018. Asian Society of
Gynecologic Oncology, Korean Society of
Gynecologic Oncology
This is an Open Access article distributed
under the terms of the Creative Commons
Attribution Non-Commercial License (<https://creativecommons.org/licenses/by-nc/4.0/>)
which permits unrestricted non-commercial
use, distribution, and reproduction in any
medium, provided the original work is properly
cited.

ORCID iDs

Young-Jae Lee 
<https://orcid.org/0000-0001-6557-2454>
Yong-Man Kim 
<https://orcid.org/0000-0003-3225-5748>
Jong-Jin Lee 
<https://orcid.org/0000-0002-3184-2409>
Jeong-Kon Kim 
<https://orcid.org/0000-0002-8101-8135>
Young-Tak Kim 
<https://orcid.org/0000-0002-2126-8503>
Joo-Hyun Nam 
<https://orcid.org/0000-0002-8440-3370>

Young-Jae Lee ¹, Yong-Man Kim ¹, Phill-Seung Jung ¹, Jong-Jin Lee ²,
Jeong-Kon Kim ³, Young-Tak Kim ¹, Joo-Hyun Nam ¹

¹Department of Obstetrics and Gynecology, University of Ulsan College of Medicine, Asan Medical Center, Seoul, Korea

²Department of Nuclear Medicine, University of Ulsan College of Medicine, Asan Medical Center, Seoul, Korea

³Department of Radiology, University of Ulsan College of Medicine, Asan Medical Center, Seoul, Korea

ABSTRACT

Objective: The aim of this study was to evaluate the diagnostic value of integrated ^{18}F -fluoro-2-deoxyglucose-positron emission tomography/computed tomography (^{18}F -FDG-PET/CT) for suspected recurrence of epithelial ovarian cancer (EOC) with non-disseminated lesions.

Methods: We retrospectively reviewed the medical records of recurrent EOC patients who underwent secondary cytoreduction from January 2000 to December 2013. A total of 134 patients underwent secondary cytoreduction after imaging with either ^{18}F -FDG-PET/CT or contrast-enhanced computed tomography (CECT).

Results: In a patient-based analysis of 134 patients, 124 (92.5%) were confirmed to be positive for malignancy. Among 72 patients with suspected non-disseminated recurrence on ^{18}F -FDG-PET/CT, 65 (89.0%) were confirmed to have recurrence, giving 98.5% sensitivity, 87.7% accuracy, and 88.9% positive predictive value (PPV). In the 65 patients with recurrence, residual tumor remained in 14 patients, giving an accuracy of patient selection for secondary cytoreduction of 69.4% (50/72) and it is higher than that of CECT (64.0%). In 169 lesions removed from patients who underwent preoperative ^{18}F -FDG-PET/CT, 135 (79.9%) were confirmed to be positive for malignancy and 124 were accurately detected by ^{18}F -FDG-PET/CT, giving 91.9% sensitivity, 81.1% accuracy, and 85.5% PPV. Foreign body granuloma was found in 33.3% of 21 lesions with false-positive ^{18}F -FDG-PET/CT findings (7/21). The mean preoperative cancer antigen 125 (CA-125) level in false-positive patients was 28.8 U/mL.

Conclusion: Compared with CECT, ^{18}F -FDG-PET/CT shows higher sensitivity in lesion-based analysis and better accuracy of patient selection for secondary cytoreduction. However, there is still a need for integration of the results of ^{18}F -FDG-PET/CT, CECT, and CA-125 levels to aid treatment planning.

Keywords: Positron Emission Tomography Computed Tomography; Ovarian Neoplasms; Cytoreduction Surgical Procedures; Granuloma, Foreign-Body

Conflict of Interest

No potential conflicts of interest relevant to this article was reported.

Author Contributions

Conceptualization: K.Y.M., J.P.S.; Data curation: L.Y.J., K.Y.M., L.J.J., K.J.K.; Formal analysis: L.Y.J., K.Y.M., J.P.S.; Funding acquisition: L.Y.J., K.Y.M.; Investigation: L.Y.J.; Methodology: L.Y.J., K.Y.M., J.P.S., L.J.J., K.J.K.; Resources: K.Y.T., N.J.H.; Software: L.Y.J., J.P.S.; Supervision: K.Y.T., N.J.H.; Validation: L.Y.J., J.P.S.; Visualization: L.Y.J.; Writing - original draft: L.Y.J., J.P.S.; Writing - review & editing: L.Y.J., K.Y.M.

INTRODUCTION

Ovarian cancer is the sixth most common cancer in women and the leading cause of death in gynecologic malignancies [1]. Most women with advanced ovarian cancer experience recurrence within 5 years of diagnosis, despite previously achieving complete remission with cytoreductive surgery and adjuvant chemotherapy [2]. To detect cancer recurrence, various surveillance methods after the completion of primary treatment have been proposed, including periodic evaluation of tumor marker levels and the use of imaging modalities, such as ultrasonography, computed tomography (CT), and integrated ^{18}F -fluoro-2-deoxyglucose-positron emission tomography/computed tomography (^{18}F -FDG-PET/CT) [3]. In previous studies, serial monitoring of the cancer antigen 125 (CA-125) level showed a sensitivity of 79% to 95% and a positive predictive value (PPV) close to 100% [4-6]. However, unlike tumor marker levels, imaging modalities can assess the site of recurrence, disease volume, and spread extent, which can help gynecology oncologists to decide on a treatment plan [7]. Rapid identification of recurrence and its range through these imaging modalities can improve survival in patients who undergo complete resection through secondary cytoreduction, but there is no benefit in survival when residual tumor remains [8,9].

Recently, ^{18}F -FDG-PET/CT has become widely used to determine whether secondary cytoreduction in patients with suspected recurrence of epithelial ovarian cancer (EOC) [10,11]. Compared with CT, positron emission tomography/computed tomography (PET/CT) may be able to detect recurrence earlier through detect hypermetabolic uptake of ^{18}F -fluoro-2-deoxyglucose (^{18}F -FDG) when localized recurrent tumors smaller than 1 cm occur. However, limited data are available on the diagnostic accuracy of ^{18}F -FDG-PET/CT in suspected recurrent EOC with non-disseminated lesions, which can be an indication for secondary cytoreduction. In addition, several previous studies were derived from patient-based analysis rather than lesion-based analysis, and only a few of the study patients actually underwent secondary cytoreduction.

Therefore, we investigated the diagnostic value and accuracy of patient selection for secondary cytoreduction of ^{18}F -FDG-PET/CT and compared them with those of contrast-enhanced CT (CECT) in patients with suspected recurrence of EOC with non-disseminated lesions by correlating imaging findings with pathologic diagnosis of secondary cytoreduction.

MATERIALS AND METHODS

1. Patient population

After obtaining approval from the Institutional Review Board at Asan Medical Center (IRB No. 2017-0481), we retrospectively reviewed the medical records of recurrent EOC patients who received primary therapy at Asan Medical Center from January 2000 to December 2013. Secondary cytoreduction was performed only when complete resection was deemed possible for the targeted tumor burden in patients with suspected non-disseminated recurrent EOC. "Non-disseminated" recurrence refers to local recurrence of cancer in 3 or fewer sites. We excluded patients who did not have secondary cytoreduction, who underwent palliative surgery for symptom relief such as colostomy-only surgery, who underwent surgery less than 6 months after primary treatment, who underwent preoperative imaging studies more than

6 weeks prior to surgery, who were lost to follow-up. Through the above criteria, 134 patients who underwent secondary cytoreduction after imaging with ^{18}F -FDG-PET/CT or CECT were identified and we collected clinicopathologic data.

2. Imaging protocol

^{18}F -FDG-PET/CT scanning was performed after at least 6 hours of fasting. Metformin was discontinued for 48 hours before the study because it could increase the amount of FDG within the bowel. One hour prior to scanning, 370–555 MBq (10–15 mCi) of ^{18}F -FDG was intravenously injected into patients with a blood glucose level less than 150 mg/dL. We start the acquisition of the positron emission tomography (PET) images at about 60 to 90 minutes after ^{18}F -FDG administration. PET/CT scans from the skull base to the proximal femur were performed using a Discovery STE (GE Healthcare, Waukesha, WI, USA), a Biograph Truepoint 16 (Siemens/CTI, Knoxville, TN, USA), or a Biograph Truepoint 40 (Siemens/CTI) scanner. CT images were obtained for attenuation correction and image fusion with all PET images, followed by 3-dimensional caudocranial PET scanning.

CECT scanning was also performed after at least 6 hours of fasting, and intravenous or oral contrast media was administered immediately before scanning. The CT scanning was performed on 4-, 16-, or 64-multidetector CT scanners (LightSpeed Plus, LightSpeed 16, or LightSpeed VCT, GE Healthcare; Somatom Sensation 16 or 64 or Somatom Definition, Siemens Medical Systems, Erlangen, Germany). Contrast media were either iopromide (Ultravist 370, Bayer Schering Pharma, Berlin, Germany) or iohexol (Omnipaque 300, GE Healthcare, Chalfont St Giles, UK) at a dose of 2–2.5 mL/kg.

All images were interpreted by experts from each division; ^{18}F -FDG-PET/CT images were interpreted by experts in nuclear medicine, and CECT images were interpreted by experts in radiology. More than 2 physicians of each department were involved in the interpretation of each patient's images. According to the results of previous reports, when the standardized uptake values were higher than 3.0, they were regarded as indicative of malignancy [11,12].

3. Data analysis

Data were analyzed based on 2 different categories: patient-based and lesion-based data. In patient-based data, a true positive was defined as at least 1 hypermetabolic focus on ^{18}F -FDG-PET/CT or a suspected lesion on CECT that correlated with pathologically confirmed recurrent EOC after the secondary cytoreduction. Because each patient could have multiple lesions, to evaluate the diagnostic value of the imaging tools for each lesion, lesion-based data were also analyzed. All suspected recurrent lesions on imaging and all newly detected lesions during the surgery were removed during the secondary cytoreduction and their data were included in the lesion-based analysis. We estimated the sensitivity, accuracy, and PPV of ^{18}F -FDG-PET/CT imaging and compared the values with those of CECT via correlation with the pathologic result of the secondary cytoreduction. Additionally, we estimated the accuracy of patient selection for secondary cytoreduction. This refers to the ability of imaging modalities to accurately select patients who can undergo complete resection of recurrent cancer masses through secondary cytoreduction. This accuracy was calculated as the percentage of the total number of surgery patients minus the number of patients diagnosed with a false-positive after surgery or with residual tumor. All statistical analyses were performed using SPSS software, version 21.0 (SPSS Inc., Chicago, IL, USA).

RESULTS

The patients' baseline characteristics are described in **Table 1**. The median interval between primary treatment and secondary cytoreduction was 38.2 months (range, 7.1–136.6). The median overall survival after secondary cytoreduction was 39.1 months (range, 2.1–126.1). At the end of follow-up, 23 patients (17.2%) had achieved complete remission, 23 patients (17.2%) were alive with disease, and 88 patients (65.7%) had died of disease.

1. Patient-based analysis

Among the 134 patients, 73 underwent ¹⁸F-FDG-PET/CT, 129 underwent CECT, and 68 underwent both imaging tools before secondary cytoreduction (**Table 2**). Overall, 124 patients (92.5%) were confirmed to have recurrence by pathologic diagnosis after secondary cytoreduction. In the 73 patients who underwent preoperative ¹⁸F-FDG-PET/CT, 65 (89.0%) were confirmed to be positive for malignancy, giving 98.5% sensitivity (95% confidence interval [CI]=91.8%–99.7%), 87.7% accuracy (95% CI=80.1%–95.2%), and 88.9% PPV (95% CI=79.6%–94.3%). In the 129 patients who underwent CECT, 119 (92.2%) were diagnosed

Table 1. Baseline characteristics of the study cohort (n=134)

Variables	Median	Range or No. (%)
Age (yr)	47	17–76
CA-125 level before secondary cytoreduction (U/mL)	186.2	3.2–3,240.0
Median interval between primary treatment and secondary cytoreduction (mo)	38.2	7.1–136.6
Overall survival after secondary cytoreduction (mo)	39.1	2.1–126.1
Stage at initial diagnosis	I	18 (13.5)
	II	11 (8.2)
	III	86 (64.1)
	IV	19 (14.2)
Histologic type	Papillary serous carcinoma	86 (64.1)
	Endometrioid adenocarcinoma	17 (12.7)
	Mucinous adenocarcinoma	9 (6.7)
	Clear cell carcinoma	8 (6.0)
	Others	14 (10.5)
Result of secondary cytoreduction	Residual tumor (–)	90 (67.2)
	Residual tumor (+)	34 (25.4)
	No recurrence	10 (7.5)
Final status of patients	Complete remission	23 (17.2)
	Alive with disease	23 (17.2)
	Died of disease	88 (65.7)

CA-125, cancer antigen 125.

Table 2. Patient-based analysis (n=134)

Variables	Pathology		Sensitivity (95% CI)	Accuracy (95% CI)	PPV (95% CI)
	Positive	Negative			
PET/CT (n=73)					
Positive	64	8	98.5%	87.7%	88.9%
Negative	1	0	(91.8%–99.7%)	(80.1%–95.2%)	(79.6%–94.3%)
CECT (n=129)					
Positive	115	10	96.6%	89.1%	92.0%
Negative	4	0	(91.7%–98.7%)	(83.8%–94.5%)	(85.9%–95.6%)
Both PET/CT & CECT (n=68)					
PET/CT					
Positive	59	8	98.3%	86.8%	88.1%
Negative	1	0	(91.1%–99.7%)	(78.7%–94.8%)	(78.2%–93.8%)
CECT					
Positive	60	8	100%	88.2%	88.2%
Negative	0	0	(94.0%–100.0%)	(80.6%–95.9%)	(78.5%–93.9%)

CECT, contrast-enhanced computed tomography; CI, confidence interval; PET/CT, positron emission tomography/computed tomography; PPV, positive predictive value.

with recurrence after secondary cytoreduction, giving 96.6% sensitivity (95% CI=91.7%–98.7%), 89.1% accuracy (95% CI=83.8%–94.5%), and 92.0% PPV (95% CI=85.9%–95.6%). In the 68 patients who underwent both imaging tools, 60 (88.2%) were confirmed to have recurrence. Among these, 59 patients were accurately detected by ¹⁸F-FDG-PET/CT, with 98.3% sensitivity (95% CI=91.1%–99.7%), 86.8% accuracy (95% CI=78.7%–94.8%), and 88.1% PPV (95% CI=78.2%–93.8%), whereas 60 patients were detected by CECT, with 100% sensitivity (95% CI=94.0%–100.0%), 88.2% accuracy (95% CI=80.6%–95.9%), and 88.2% PPV (95% CI=78.5%–93.9%).

The mean preoperative CA-125 level in the 10 false-positive patients was very low, at 28.8 U/mL (range, 3.2–81.8). Seven patients had less than 35 U/mL and only 3 patients had a 10 U/mL or more increase compared with the previous CA-125. Secondary cytoreduction according to ¹⁸F-FDG-PET/CT readings revealed false positives in 8 patients and residual tumor in 14 patients, giving an accuracy of patient selection for secondary cytoreduction of 69.4% (50 of 72). Secondary cytoreduction according to CECT readings revealed false positives in 10 patients and residual tumor in 35 patients, giving an accuracy of patient selection for secondary cytoreduction of 64.0% (80 of 125). Secondary cytoreduction according to ¹⁸F-FDG-PET/CT and CECT readings revealed false positives in 8 patients and residual tumor in 14 patients, giving an accuracy of patient selection for secondary cytoreduction of 67.2% (45 of 67). Most patients with residual tumor were found to have peritoneal disseminated recurrence smaller than 1 cm during surgery. The average treatment-free interval of these patients was 24.9 months.

2. Lesion-based analysis

A total of 313 macroscopic localized lesions with suspected recurrence by preoperative imaging tools or intraoperative findings were resected during the secondary cytoreduction and submitted for pathologic examination (**Table 3**); 169 lesions were removed from patients who underwent preoperative ¹⁸F-FDG-PET/CT, 304 lesions were removed from patients who underwent preoperative CECT, and 160 lesions were removed from patients who preoperatively underwent both ¹⁸F-FDG-PET/CT and CECT. Overall, 254 of the 313 lesions (81.2%) were confirmed to be recurrence. In the 169 lesions removed from patients who underwent preoperative ¹⁸F-FDG-PET/CT, 135 lesions (79.9%) were confirmed to be recurrence and 124 lesions were accurately detected by ¹⁸F-FDG-PET/CT, giving 91.9% sensitivity (95% CI=86.0%–95.4%), 81.1% accuracy (95% CI=75.2%–87.0%), and 85.5% PPV

Table 3. Lesion-based analysis (n=313)

Variables	Pathology		Sensitivity (95% CI)	Accuracy (95% CI)	PPV (95% CI)
	Positive	Negative			
PET/CT (n=169)					
Positive	124	21	91.9%	81.1%	85.5%
Negative	11	13	(86.0%–95.4%)	(75.2%–87.0%)	(78.9%–90.3%)
CECT (n=304)					
Positive	212	30	85.8%	78.6%	87.6%
Negative	35	27	(80.9%–89.6%)	(74.0%–83.2%)	(82.9%–91.2%)
Both PET/CT & CECT (n=160)					
PET/CT					
Positive	119	21	93.0%	81.3%	85.0%
Negative	9	11	(87.2%–96.3%)	(75.2%–87.3%)	(78.2%–90.0%)
CECT					
Positive	109	17	85.2%	77.5%	86.5%
Negative	19	15	(78.0%–90.3%)	(71.0%–84.0%)	(79.5%–91.4%)

CECT, contrast-enhanced computed tomography; CI, confidence interval; PET/CT, positron emission tomography/computed tomography; PPV, positive predictive value.

Table 4. Characteristics of 21 lesions with false-positive ^{18}F -FDG-PET/CT findings

Sites	No.	Mean maxSUV	Pathologic findings	No.	Mean maxSUV
Pelvic cavity mass or nodule	7	5.5	Foreign body granuloma	7	4.4
Lymph node	5	6.3	Lymph nodes only	5	6.3
Abdominopelvic peritoneum	5	4.2	Fibrous (fibroadipose) tissue	6	5.9
Hypermetabolic cystic lesion in pelvic area	2	6.3	Fibrous adhesion band with lymphocele	2	6.3
Mesentery nodule	1	5.4	Fat necrosis	1	5.4
Diaphragm	1	5.9	-	-	-
Total	21	5.6	-	21	5.6

 ^{18}F -FDG-PET/CT, ^{18}F -fluoro-2-deoxyglucose-positron emission tomography/computed tomography; maxSUV, maximum standardized uptake value.

Table 5. Characteristics of 11 lesions with false-negative ^{18}F -FDG-PET/CT findings

Sites	No.
Abdominopelvic peritoneum	5
Bowel serosa	2
Paraortic lymph node	1
Diaphragm	1
Omentum	1
Pelvic mass	1
Total	11

 ^{18}F -FDG-PET/CT, ^{18}F -fluoro-2-deoxyglucose-positron emission tomography/computed tomography.

(95% CI=78.9%–90.3%). The mean of the maximum standardized uptake value (maxSUV) of the hypermetabolic lesions was 6.92 (range, 1.6–26.7). The mean maxSUV of false-positive sites and recurrence sites were 5.60 and 6.85, respectively. The p-value in logistic regression analysis of the maxSUV was 0.216. In the 304 lesions removed from patients who underwent preoperative CECT, 247 lesions (81.2%) were positive for malignancy and 212 lesions were accurately detected by preoperative CECT, giving 85.8% sensitivity (95% CI=80.9%–89.6%), 78.6% accuracy (95% CI=74.0%–83.2%), and 87.6% PPV (95% CI=82.9%–91.2%). In the 160 lesions removed from patients who preoperatively underwent both imaging tools, 128 lesions (80.0%) were diagnosed to be recurrence after secondary cytoreduction. Of these, 119 lesions were accurately detected by ^{18}F -FDG-PET/CT, giving 93.0% sensitivity (95% CI=87.2%–96.3%), and 109 lesions were accurately detected by CECT, giving 85.2% sensitivity (95% CI=78.0%–90.3%). The characteristics of the 21 false-positive lesions and the 11 false-negative lesions on ^{18}F -FDG-PET/CT are summarized in **Tables 4** and **5**.

DISCUSSION

In the current study, we evaluated the diagnostic value of ^{18}F -FDG-PET/CT and CECT for detecting the recurrence of EOC with non-disseminated lesions. In patient-based analysis, we found no significant difference in the diagnostic ability of the 2 imaging tools. In lesion-based analysis, ^{18}F -FDG-PET/CT tended to have higher sensitivity than CECT, suggesting the possibility of early diagnosis and treatment before lesion dissemination. However, in terms of accuracy and PPV, there was no significant difference in ability compared with CECT, and the combination of both imaging tools showed no superiority in diagnostic value compared with ^{18}F -FDG-PET/CT alone.

There have been several reports on the diagnostic value of ^{18}F -FDG-PET/CT in patients with suspected recurrent EOC [12–16]. In these studies, ^{18}F -FDG-PET/CT showed a sensitivity of 82%–100%, a PPV of 93.8%–100%, and an accuracy of 80%–97.7%. However, most previous studies involved patient-based analysis rather than lesion-based analysis. In patient-based analysis of patients with multiple lesions, even if the predictions of individual lesions are

somewhat incorrect, any malignant lesions are considered to indicate an accurate prediction. Accurate detection of each lesion is essential for precise surgical range determination and prevention of unprofitable surgery. In one lesion-based analysis in 2012, the approach showed a sensitivity of 80.8% [17]. A prospective lesion-based study of 22 patients published in 2009 determined a sensitivity of 60.5% and accuracy of 72.4% [18]. Although these studies were performed on a small number of patients, the overall diagnostic values were much lower than those of patient-based studies. We performed both patient-based and lesion-based analyses. The diagnostic value of the lesion-based analysis was lower than that of the patient-based analysis, but the difference was not as marked as in previous studies.

There have been 2 meta-analyses, with sensitivities of 88.6% and 91% and specificities of 90.3% and 88%, respectively [19,20]. Gu et al. [19] demonstrates that AUC of an ROC curve is greater for PET/CT than that of CT or magnetic resonance imaging (MRI) and that this difference is statistically significant. However, they had many limitations, such as considerable variations between the included studies in terms of patient population, data presentation, and insufficient numbers of high-quality and large-scale prospective studies, and a mixture of patient-based and lesion-based analyses. Above all, only a few studies were focused on the diagnostic accuracy of ^{18}F -FDG-PET/CT in suspected recurrent EOC with “non-disseminated lesions.” The most important goal of the rapid detection of recurrence using ^{18}F -FDG-PET/CT is to promptly detect a non-disseminated status, which can be expected to improve the survival rate by performing complete resection through secondary cytoreduction. In recurrent EOC cases, local recurrence of cancer enough to perform secondary cytoreduction is very rare. Our study focused on non-disseminated recurrent EOC. And this is the only study we know of to only include patients who underwent secondary cytoreduction rather than ascites analysis or interventional pathologic confirmations such as fine needle biopsy.

Most previous studies were performed on less than 50 patients and there was no study included more than 100 patients. Our study is based on long-term data from a relatively large number of patients. We also attempted to increase the reliability of the data by excluding patients who were lost to follow-up.

In this study, the mean preoperative CA-125 level was as low as 28.8 U/mL (range, 3.2–81.8) in 10 patients with false-positive ^{18}F -FDG-PET/CT findings and the preoperative increase was not clear. Based on this finding, patients with a CA-125 of less than 35 U/mL and no significant increase compared with previous tests should consider short-term follow-up without surgery if the imaging findings are uncertain because they are more likely to undergo unnecessary surgery.

Among 21 lesions with false-positive ^{18}F -FDG-PET/CT findings, foreign body granuloma was found in 33.3% (7 of 21). Foreign body granuloma is a rare benign tumor caused by an inflammatory response of biological tissue to any exogenous substance in the tissue. If there is an implant, the healing reaction is different and it is called foreign body reaction. Foreign body reaction involves protein adsorption, fibroblasts, macrophages, multinucleated foreign body giant cells (macrophage fusion), and angiogenesis [21]. In women who have undergone surgery for ovarian cancer, foreign body granulomas mainly formed around the suture materials or clips. Silk sutures cause more allergic reactions and infections than monofilament sutures, and foreign body granulomas occur more frequently in Asia where silk sutures are used more frequently [22]. Foreign body granuloma is not well detected on CT or MRI because it is radiopaque. However, it has an inflammatory nature that can be

detected as a local hypermetabolic lesion in ^{18}F -FDG-PET/CT and thus increases its false-positive rate (**Fig. 1**). In our results, the mean maxSUV of foreign body granuloma was 4.41 (range, 2.2–7.2). A number of case reports have been published on this entity in various carcinomas [23–25]. However, only 1 or 2 cases were reported in each study and no large numbers of cases were identified, as in this study.

Of the 11 lesions with false-negative ^{18}F -FDG-PET/CT findings, 9 were less than 1.5 cm in size. This result reconfirms the difficulty of detecting disseminated recurrence lesions smaller than 1 cm on PET/CT or CT [18].

This is the first study to compare the accuracy of patient selection for secondary cytoreduction according to imaging modality. In our present analysis, the accuracy of patient selection for secondary cytoreduction of ^{18}F -FDG-PET/CT was 69.4%, which was higher than

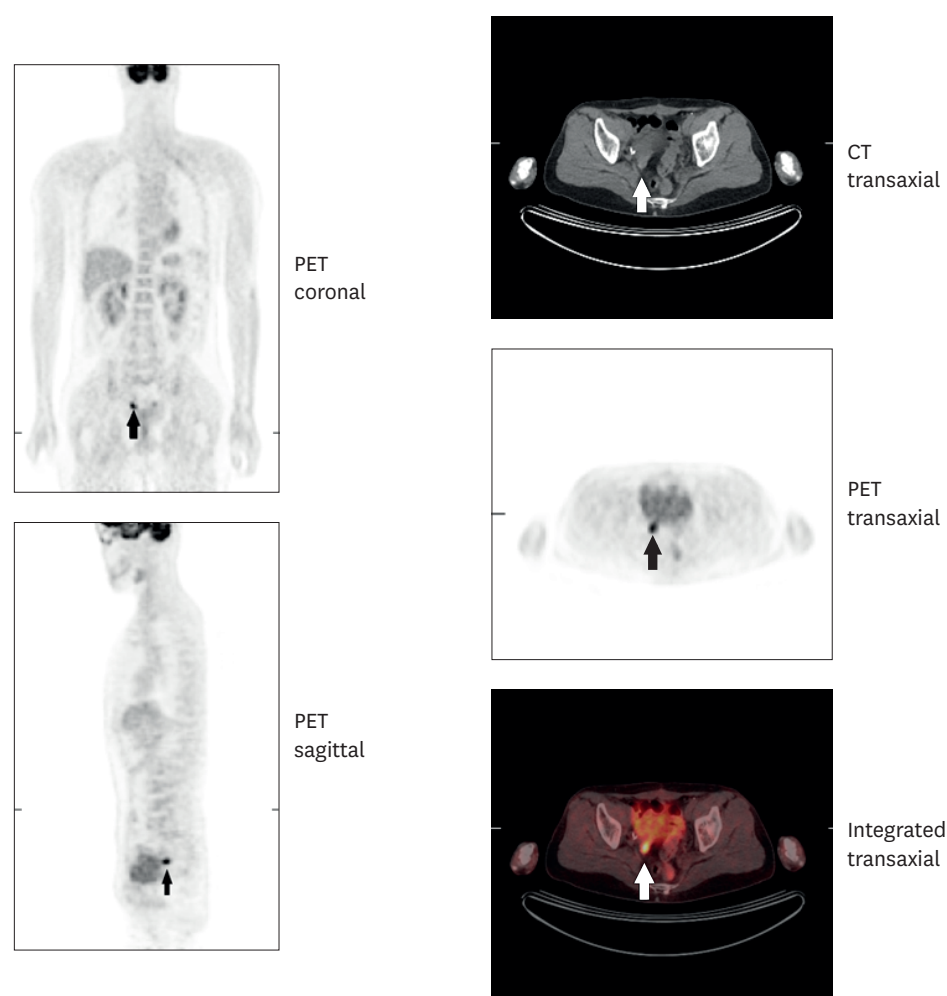


Fig. 1. ^{18}F -FDG-PET/CT images of a 47-year-old woman with stage IV papillary serous carcinoma of the ovary after a staging operation followed by chemotherapy with paclitaxel plus carboplatin for 12 cycles and radiation therapy to the left supraclavicular area. The preoperative CA-125 level before secondary cytoreduction was 8.4 U/mL. These images show a hypermetabolic nodule (maxSUV=7.2) in the right pelvic region (white or black arrows) suggestive of malignancy. After secondary cytoreduction, pathology confirmed foreign body granuloma in the lesion. This patient achieved complete remission with no recurrence for more than 5 years. ^{18}F -FDG-PET/CT, ^{18}F -fluoro-2-deoxyglucose-positron emission tomography/computed tomography; CA-125, cancer antigen 125; CT, computed tomography; maxSUV, maximum standardized uptake value; PET, positron emission tomography.

that of CECT at 64.0%. This accuracy makes it easy to judge whether or not to perform the surgery and will help clinicians to present accurate percentages of the possibility of complete resection in secondary cytoreduction to patients who considering secondary cytoreduction.

This study had some limitations of note. It was a retrospective study and there could be a selection bias by its nature. In our hospital, ^{18}F -FDG-PET/CT is performed in most patients with suspected local recurrence based on CECT findings. Therefore, PET-CT interpretation may not be independent of CECT interpretation. Regarding the accuracy of patient selection for secondary cytoreduction, operators can make incorrect decisions about resectability by not referring to the results of imaging studies and this can act as a confounding factor. We also could not determine the specificity because the study population comprised patients who underwent secondary cytoreduction due to the positive results of an imaging study.

In conclusion, this study shows that ^{18}F -FDG-PET/CT have higher diagnostic utility and the accuracy of patient selection for secondary cytoreduction than CECT. Early identification of recurrence and its range by imaging modalities can lead to higher survival in patients with recurrent EOC by complete resection through secondary cytoreduction. Patients with a CA-125 of less than 35 U/mL with no significant increase compared with previous tests show high risk of false-positive findings. Thus, there is still a need for integration of the results of ^{18}F -FDG-PET/CT, CECT, and CA-125 levels to aid treatment planning and short-term follow-up should be considered instead of an operation if the imaging findings are uncertain.

ACKNOWLEDGMENTS

We would like to thank all of the members of the Department of Obstetrics and Gynecology, University of Ulsan College of Medicine, Asan Medical Center.

REFERENCES

1. Siegel R, Naishadham D, Jemal A. Cancer statistics, 2013. *CA Cancer J Clin* 2013;63:11-30.
[PUBMED](#) | [CROSSREF](#)
2. Damak T, Chargui R, Ben Hassouna J, Hechiche M, Rahal K. Results of second-look laparotomy in advanced ovarian cancer: one single center experience. *ISRN Obstet Gynecol* 2012;2012:849518.
[PUBMED](#) | [CROSSREF](#)
3. Thrall MM, DeLoia JA, Gallion H, Avril N. Clinical use of combined positron emission tomography and computed tomography (FDG-PET/CT) in recurrent ovarian cancer. *Gynecol Oncol* 2007;105:17-22.
[PUBMED](#) | [CROSSREF](#)
4. Niloff JM, Knapp RC, Lavin PT, Malkasian GD, Berek JS, Mortel R, et al. The CA 125 assay as a predictor of clinical recurrence in epithelial ovarian cancer. *Am J Obstet Gynecol* 1986;155:56-60.
[PUBMED](#) | [CROSSREF](#)
5. Högberg T, Kågedal B. Long-term follow-up of ovarian cancer with monthly determinations of serum CA 125. *Gynecol Oncol* 1992;46:191-8.
[PUBMED](#) | [CROSSREF](#)
6. Rustin GJ, Marples M, Nelstrop AE, Mahmoudi M, Meyer T. Use of CA-125 to define progression of ovarian cancer in patients with persistently elevated levels. *J Clin Oncol* 2001;19:4054-7.
[PUBMED](#) | [CROSSREF](#)
7. Murakami M, Miyamoto T, Iida T, Tsukada H, Watanabe M, Shida M, et al. Whole-body positron emission tomography and tumor marker CA125 for detection of recurrence in epithelial ovarian cancer. *Int J Gynecol Cancer* 2006;16 Suppl 1:99-107.
[PUBMED](#) | [CROSSREF](#)

8. Laas E, Luyckx M, De Cuyper M, Selle F, Daraï E, Querleu D, et al. Secondary complete cytoreduction in recurrent ovarian cancer: benefit of optimal patient selection using scoring system. *Int J Gynecol Cancer* 2014;24:238-46.
[PUBMED](#) | [CROSSREF](#)
9. Harter P, du Bois A. The role of surgery in ovarian cancer with special emphasis on cytoreductive surgery for recurrence. *Curr Opin Oncol* 2005;17:505-14.
[PUBMED](#) | [CROSSREF](#)
10. Beyer T, Townsend DW, Brun T, Kinahan PE, Charron M, Roddy R, et al. A combined PET/CT scanner for clinical oncology. *J Nucl Med* 2000;41:1369-79.
[PUBMED](#)
11. Hubner KF, McDonald TW, Niethammer JG, Smith GT, Gould HR, Buonocore E. Assessment of primary and metastatic ovarian cancer by positron emission tomography (PET) using 2-[18F]deoxyglucose (2-[18F]FDG). *Gynecol Oncol* 1993;51:197-204.
[PUBMED](#) | [CROSSREF](#)
12. Chung HH, Kang WJ, Kim JW, Park NH, Song YS, Chung JK, et al. Role of [18F]FDG PET/CT in the assessment of suspected recurrent ovarian cancer: correlation with clinical or histological findings. *Eur J Nucl Med Mol Imaging* 2007;34:480-6.
[PUBMED](#) | [CROSSREF](#)
13. Bhosale P, Peungjesada S, Wei W, Levenback CF, Schmeler K, Rohren E, et al. Clinical utility of positron emission tomography/computed tomography in the evaluation of suspected recurrent ovarian cancer in the setting of normal CA-125 levels. *Int J Gynecol Cancer* 2010;20:936-44.
[PUBMED](#) | [CROSSREF](#)
14. Ebina Y, Watari H, Kaneuchi M, Takeda M, Hosaka M, Kudo M, et al. Impact of FDG PET in optimizing patient selection for cytoreductive surgery in recurrent ovarian cancer. *Eur J Nucl Med Mol Imaging* 2014;41:446-51.
[PUBMED](#) | [CROSSREF](#)
15. Antunovic L, Cimitan M, Borsatti E, Baresic T, Sorio R, Giorda G, et al. Revisiting the clinical value of 18F-FDG PET/CT in detection of recurrent epithelial ovarian carcinomas: correlation with histology, serum CA-125 assay, and conventional radiological modalities. *Clin Nucl Med* 2012;37:e184-8.
[PUBMED](#) | [CROSSREF](#)
16. Takekuma M, Maeda M, Ozawa T, Yasumi K, Torizuka T. Positron emission tomography with 18F-fluoro-2-deoxyglucose for the detection of recurrent ovarian cancer. *Int J Clin Oncol* 2005;10:177-81.
[PUBMED](#) | [CROSSREF](#)
17. Kitajima K, Ueno Y, Suzuki K, Kita M, Ebina Y, Yamada H, et al. Low-dose non-enhanced CT versus full-dose contrast-enhanced CT in integrated PET/CT scans for diagnosing ovarian cancer recurrence. *Eur J Radiol* 2012;81:3557-62.
[PUBMED](#) | [CROSSREF](#)
18. Bristow RE, del Carmen MG, Pannu HK, Cohade C, Zahurak ML, Fishman EK, et al. Clinically occult recurrent ovarian cancer: patient selection for secondary cytoreductive surgery using combined PET/CT. *Gynecol Oncol* 2003;90:519-28.
[PUBMED](#) | [CROSSREF](#)
19. Gu P, Pan LL, Wu SQ, Sun L, Huang G. CA 125, PET alone, PET-CT, CT and MRI in diagnosing recurrent ovarian carcinoma: a systematic review and meta-analysis. *Eur J Radiol* 2009;71:164-74.
[PUBMED](#) | [CROSSREF](#)
20. Limei Z, Yong C, Yan X, Shuai T, Jiangyan X, Zhiqing L. Accuracy of positron emission tomography/computed tomography in the diagnosis and restaging for recurrent ovarian cancer: a meta-analysis. *Int J Gynecol Cancer* 2013;23:598-607.
[PUBMED](#) | [CROSSREF](#)
21. Haley PJ. Mechanisms of granulomatous lung disease from inhaled beryllium: the role of antigenicity in granuloma formation. *Toxicol Pathol* 1991;19:514-25.
[PUBMED](#) | [CROSSREF](#)
22. Matsuura S, Sasaki K, Kawasaki H, Abe H, Nagai H, Yoshimi F. Silk suture granuloma with false-positive findings on PET/CT accompanied by peritoneal metastasis after colon cancer surgery. *Int J Surg Case Rep* 2016;28:22-5.
[PUBMED](#) | [CROSSREF](#)
23. Pantiora EV, Kontis EA, Michalaki V, Primetis E, Vezakis A, Polydorou A, et al. Granuloma mimicking local recurrence on PET/CT after liver resection of colorectal liver metastasis: a case report. *Cureus* 2016;8:e717.
[PUBMED](#) | [CROSSREF](#)

24. Takeshita N, Tohma T, Miyauchi H, Suzuki K, Nishimori T, Ohira G, et al. Suture granuloma with false-positive findings on FDG-PET/CT resected via laparoscopic surgery. *Int Surg* 2015;100:604-7.
[PUBMED](#) | [CROSSREF](#)
25. Dong A, Bai Y, Wang Y, Zuo C. Foreign body granuloma of the epiglottic vallecula mimicking malignancy on MRI and FDG PET/CT. *Clin Nucl Med* 2016;41:227-9.
[PUBMED](#) | [CROSSREF](#)