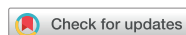

Original Article



Performance of pre-treatment ^{18}F -fluorodeoxyglucose positron emission tomography/computed tomography for detecting metastasis in ovarian cancer: a systematic review and meta-analysis

Sangwon Han ,^{1,2,*} Sungmin Woo ,^{1,3,*} Chong Hyun Suh ,^{1,4} Jong Jin Lee ²

¹Meta-analysis for Imaging studies on Diagnostic Accuracy and prognosis (MIDAS) group.

²Department of Nuclear Medicine, Asan Medical Center, University of Ulsan College of Medicine, Seoul, Korea

³Department of Radiology, Seoul National University College of Medicine, Seoul, Korea

⁴Department of Radiology and Research Institute of Radiology, Asan Medical Center, University of Ulsan College of Medicine, Seoul, Korea

OPEN ACCESS

Received: Apr 1, 2018

Revised: Aug 7, 2018

Accepted: Aug 20, 2018

Correspondence to

Jong Jin Lee

Department of Nuclear Medicine, Asan Medical Center, University of Ulsan College of Medicine, 88 Olympic-ro 43-gil, Songpa-gu, Seoul 05505, Korea.

E-mail: jongjin@gmail.com

*Sangwon Han and Sungmin Woo contributed equally to this work as co-first authors.

Copyright © 2018. Asian Society of Gynecologic Oncology, Korean Society of Gynecologic Oncology

This is an Open Access article distributed under the terms of the Creative Commons Attribution Non-Commercial License (<https://creativecommons.org/licenses/by-nc/4.0/>) which permits unrestricted non-commercial use, distribution, and reproduction in any medium, provided the original work is properly cited.

ORCID iDs

Sangwon Han

<https://orcid.org/0000-0001-8095-0396>

Sungmin Woo

<https://orcid.org/0000-0001-8459-8369>

ABSTRACT

Objective: We describe a systematic review and meta-analysis of the performance of ^{18}F -fluorodeoxyglucose (^{18}F -FDG) positron emission tomography/computed tomography (PET/CT) for detecting metastasis in ovarian cancer.

Methods: MEDLINE and Embase were searched for diagnostic accuracy studies that used ^{18}F -FDG PET or PET/CT for pre-treatment staging, using surgical findings as the reference standard. Sensitivities and specificities were pooled and plotted in a hierarchic summary receiver operating characteristic plot. Potential causes of heterogeneity were explored through sensitivity analyses.

Results: Eight studies with 594 patients were included. The overall pooled sensitivity and specificity for metastasis were 0.72 (95% confidence interval [CI]=0.61–0.81) and 0.93 (95% CI=0.85–0.97), respectively. There was considerable heterogeneity in sensitivity ($I^2=97.57\%$) and specificity ($I^2=96.74\%$). In sensitivity analyses, studies that used laparotomy as the reference standard showed significantly higher sensitivity and specificity (0.77; 95% CI=0.67–0.87 and 0.96; 95% CI=0.92–0.99, respectively) than those including diagnostic laparoscopy (0.62; 95% CI=0.46–0.77 and 0.84; 95% CI=0.69–0.99, respectively). Higher specificity was shown in studies that confirmed surgical findings by pathologic evaluation (0.95; 95% CI=0.90–0.99) than in a study without pathologic confirmation (0.69; 95% CI=0.24–1.00). Studies with a lower prevalence of the FDG-avid subtype showed higher specificity (0.97; 95% CI=0.94–1.00) than those with a greater prevalence (0.89; 95% CI=0.80–0.97).

Conclusion: Pre-treatment ^{18}F -FDG PET/CT shows moderate sensitivity and high specificity for detecting metastasis in ovarian cancer. With its low false-positive rate, it can help select surgical approaches or alternative treatment options.

Keywords: PET Scan; Ovarian Neoplasms; Neoplasm Metastasis; Sensitivity and Specificity; Meta-Analysis

Chong Hyun Suh 
<https://orcid.org/0000-0002-4737-0530>

Jong Jin Lee 
<https://orcid.org/0000-0002-3184-2409>

Conflict of Interest

The authors declare no potential conflict of interest relevant to this article.

Author Contributions

Conceptualization: L.J.J.; Data curation: H.S.; Formal analysis: H.S., W.S., S.C.H.; Investigation: H.S., W.S.; Methodology: H.S., W.S., S.C.H., L.J.J.; Software: S.C.H.; Supervision: L.J.J.; Validation: H.S., L.J.J.; Visualization: H.S.; Writing - original draft: H.S.; Writing - review & editing: H.S., W.S., S.C.H., L.J.J.

INTRODUCTION

Ovarian cancer is the 5th leading cause of death due to cancer in the United States, with an estimated 22,000 new cases developing annually [1]. Proper staging is important for treatment planning and assessing prognosis. Ovarian cancer staging is surgical and based on surgical and pathologic findings; no imaging modality provides conclusive ovarian cancer staging [2]. However, pre-treatment imaging studies are important because their findings help determine the surgical approach or help assess optimal cytoreduction feasibility [3]. They can help with selecting candidates for neoadjuvant treatment. Although ^{18}F -fluorodeoxyglucose (^{18}F -FDG) positron emission tomography/computed tomography (PET/CT) is not recommended for the routine staging of ovarian cancer [4], it can provide additional information before surgery about disease extension and the resection possibility. A comprehensive review of available literature has indicated that ^{18}F -FDG PET/CT has comparable or higher diagnostic accuracy in the staging and pre-treatment evaluation of ovarian cancer than CT and magnetic resonance imaging [5-14]. ^{18}F -FDG PET/CT findings can enhance ovarian cancer staging, largely because of the detection of supra-diaphragmatic metastasis [15].

In recent years, many studies on the utility of pre-treatment ^{18}F -FDG PET/CT have been published. However, differences in study population, design, and methodologic quality between studies have made it difficult to draw evidence-based conclusions. We therefore performed a systematic review and meta-analysis to evaluate the performance of ^{18}F -FDG PET/CT in detecting metastasis in ovarian cancer as a staging imaging modality.

MATERIALS AND METHODS

This meta-analysis adhered to the Preferred Reporting Items for Systematic Reviews and Meta-Analyses (PRISMA) guidelines [16]. A priori study protocol is given in the **Supplemental Material**.

1. Search strategy and study selection

A systematic search of MEDLINE and Embase was performed for articles published before November 9, 2017. Search queries included synonyms and related terms for ovarian cancer, PET, initial staging, and diagnostic accuracy as follows: ("ovarian cancer" OR "ovarian carcinoma" OR "ovarian neoplasm" OR "ovarian tumor" OR "ovarian tumour") AND (PET OR Positron) AND (preoperative OR pretreatment OR primary OR "lymph node" OR nodal OR "peritoneal carcinomatosis" OR "peritoneal seeding" OR distant OR metastasis OR metastases OR staging OR stage) AND (detection OR detectability OR detecting OR positivity OR sensitivity OR specificity OR diagnosis OR diagnostic OR accuracy OR performance). Reference lists of identified articles were checked to find additional relevant papers. No language restriction was placed. The following inclusion criteria were applied: patients with clinically suspected or newly diagnosed ovarian cancer; ^{18}F -FDG PET or PET/CT used as the index test for detecting metastasis; surgical findings used as the reference standard; and sufficient information available to enable 2×2 tables to be reconstructed for diagnostic accuracy. Non-original articles were excluded. When 2×2 tables could not be reconstructed, authors were contacted. Two reviewers independently performed the literature search and selection, and any disagreement was resolved by discussion.

2. Data extraction and quality assessment

A standardized form was used to extract patient, tumor, study, and ^{18}F -FDG PET/CT characteristics from included articles. Histological subtypes were reclassified according to the new World Health Organization classification [17]. Serous, endometrioid, and undifferentiated subtypes were regarded as FDG-avid [18,19]. The methodologic quality of included studies was assessed using Quality Assessment of Diagnostic Accuracy Studies-2 [20]. Two independent reviewers performed data extraction and quality assessment, with any disagreement resolved by discussion.

3. Data synthesis

Two-by-two tables were tabulated from included articles. One article provided per-patient and per-site analyses; the latter, which is more informative for treatment planning, was selected [7]. Metastasis at each site (i.e., omentum, mesentery, bowel, peritoneal cavity) was evaluated as positive or negative regardless of its numbers in the per-site analysis. Pooled sensitivity, specificity, positive likelihood ratio (PLR), and negative likelihood ratio (NLR) were calculated using hierarchical methods, including bivariate and hierarchical summary receiver operating characteristic (HSROC) models [21]. Publication bias was assessed using Deeks' funnel plot asymmetry test [22].

Heterogeneity was assessed by Higgins I^2 statistic. [23]. To explore the possible presence of threshold effect, Spearman's rank correlation between sensitivity and false-positive rate was calculated. Sensitivity analyses using several covariates were performed to explore potential causes of heterogeneity.

The clinical application of ^{18}F -FDG PET/CT was examined by pooling likelihood ratios and using them with Fagan's nomogram to generate the post-test probability for metastasis [24]. The estimated pre-test probability for detecting metastasis was based on prevalences of regional and advanced metastases of 20% and 60%, respectively [25].

Stata 10.0 (StataCorp LP, College Station, TX, USA) and R version 3.4.2 (R Foundation for Statistical Computing, Vienna, Austria) were used for statistical analyses. The p values of <0.05 were regarded as statistically significant.

RESULTS

1. Literature search

The study selection process is depicted in **Fig. 1**. The initial literature search yielded 1,076 articles. After removing 289 duplicates, screening of the remaining 787 titles and abstracts yielded 32 potentially eligible original articles. After performing full-text reviews, 24 were excluded. Thus, eight studies met our pre-defined criteria and were included [5-10,26,27]. These studies included 594 patients.

2. Study characteristics

Table 1 summarizes patient and tumor characteristics, and **Table 2** describes study characteristics. Five studies used laparotomy as the reference standard, whereas three included diagnostic laparoscopy. Seven studies confirmed surgical findings by histopathologic evaluation. The analysis level of metastatic lesions was per-site in all included

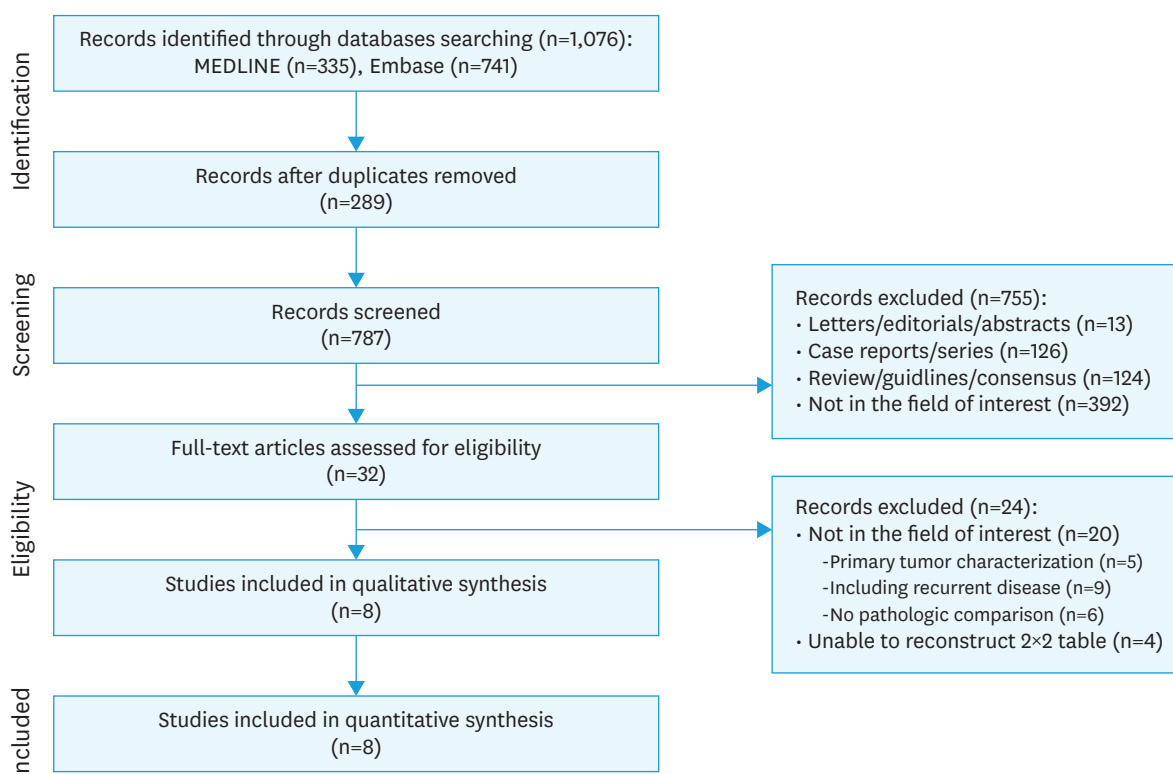


Fig. 1. Flowchart showing the selection process for eligible studies.

studies. Peritoneal metastases were evaluated in seven studies, retroperitoneal lymph node (RPLN) metastases in six, and distant metastases in three. PET/CT characteristics are shown in **Supplementary Table 1**. Six studies used hybrid PET/CT scanners, one included a stand-alone PET scanner, and one used only a stand-alone PET scanner.

3. Quality assessment

Supplementary Fig. 1 summarizes quality assessment results. One study had an unclear risk of bias in the patient selection domain because it was unclear whether consecutive patients were enrolled [26]. The same study had a possible risk of bias in the index test as it was unclear whether the index test was interpreted without knowledge of the reference standard [26]. Regarding the reference standard domain, three studies showed a high risk of bias because they used laparoscopy as the reference standard [6,10,26], and there was an unclear risk of bias in three further studies for which it was unclear whether reference standard interpretation was blinded to index test results [5,8,27]. In 2 studies, there was an unclear risk of bias in the flow and timing domain because the time interval between the PET/CT scan and reference standard was not provided [6,26].

There was low concern for applicability in the patient selection domain for all but two studies: one included only patients with advanced (stage III/IV) ovarian cancer [27] and the other excluded patients with abdominal dissemination [7]. There was high concern for applicability in the index test domain for 2 studies that included the PET only image results interpreted with enhanced CT scans [5,6]. For all studies, concern for applicability in the reference standard domain was low.

Table 1. Patient and tumor characteristics

Author	Patient characteristics					Tumor characteristics										
	No.	Age (yr)		CA-125 (U/mL)		Total lesions (No.)	Size	FIGO stage	Histologic subtype (No.)							
		Mean	Range	Mean	Range				Serous	Mucinous	Endometrioid	Clear cell	Transitional	Undifferentiated	Mixed epithelial	Others†
De Iaco et al. [26]	40	65	46–78	1,342.3	26–6,000	346	5 mm: 37.5% 5 mm–5 cm: 10.6% >5 cm: 37.5%	IIIB–IV	14	0	8	2	0	16	0	0
Hynninen et al. [10]	41	65*	45–79	NR	NR	693	NR	IC–IV	37	1	1	1	0	1	0	0
Kitajima et al. [9]	40	55.4	38–77	NR	NR	680	4.5±1.1	IA–IV	15	7	5	7	0	6	0	0
Michelsen et al. [6]	32	61.9	20–83	NR	NR	594	<1 cm: 37.5% >1 cm: 29% Confluent: 35%	IA–IV	22	1	0	0	0	0	0	9
Schmidt et al. [8]	15	65	31–89	NR	NR	195	≤5 mm: 17% 5 mm–5 cm: 54% >5 cm: 29%	NR	7	1	3	1	0	3	0	0
Shim et al. [27]	343	55*	20–80	715	4–123,000	1,029	NR	IIIA–IV	274	5	24	22	10	0	0	8
Signorelli et al. [7]	68	49*	35–72	NR	NR	517	9.0 mm* (4–41 mm)	IA–IIIC	29	6	13	10	0	3	7	0
Yoshida et al. [5]	15	60.4	34–89	NR	NR	240	NR	IA–IIIC	8	3	2	0	0	1	0	1

CA-125, cancer antigen 125; FIGO, International Federation of Gynecology and Obstetrics; NR, not reported.

*Median; †Others include germ cell tumors, benign tumors, metastatic tumors, and originally reported as others.

Table 2. Study characteristics

Author	Publication year	Publication		Origin		Design			Reference standard					Readers			
		Period	Country	Institution	Prospective	Multicenter	Patient selection	Consecutive enrollment	Method	Pathologic evaluation	PET- reference interval (days)	Analysis level	Site	No. Experience (yr)	Interpretation	Blinded	
De Iaco et al. [26]	2011	2004.09–2008.04	Italy	Azienda Ospedaliero-Universitaria di Bologna	No	No	Clinically suspected	NR	Diagnostic LPS	No	NR	Per-site	PC	NR	SUV _{max} >2 g/ml	NR	
Hynninen et al. [10]	2013	2009.10–2012.03	Finland	Turku University Hospital	Yes	No	Clinically suspected	Yes	Laparotomy or Diagnostic LPS	Yes	≤14	Per-site	PC, RPLN	2	NR	Visual	Yes
Kitajima et al. [9]	2008	2006.04–2008.04	Japan	Dokyo University School of Medicine	No	No	Clinically suspected	Yes	Laparotomy	Yes	≤14	Per-site	Contralateral ovary, PC, RPLN, liver, lung	2	3/5	Visual	Yes
Michielsens et al. [6]	2014	2010.10–2012.02	Belgium	University Hospitals Leuven	Yes	No	Clinically suspected	Yes	Laparotomy or diagnostic LPS	Yes	NR	Per-site	PC, RPLN	1	11	Visual	Yes
Schmidt et al. [8]	2015	NR	Switzerland	Lausanne University Hospital	Yes	No	Clinically suspected	Yes	Laparotomy	Yes	≤29	Per-site	PC, RPLN, pleural carcinomatosis	1	10	Visual	Yes
Shim et al. [27]	2015	2006.01–2013.08	South Korea	Asan Medical Center	No	No	Pathologically confirmed	Yes	Laparotomy	Yes	≤28	Per-site	PC	NR	NR	Visual	Yes
Signorelli et al. [7]	2013	2006.01–2012.05	Italy	San Gerardo Hospital	Yes	No	Pathologically confirmed	Yes	Laparotomy	Yes	≤30	Per-site	RPLN	2	NR	Visual	Yes
Yoshida et al. [5]	2004	2001.09–2002.07	Japan	Fukui Medical University	No	No	Clinically suspected	NR	Laparotomy	Yes	14	Per-site	Contralateral ovary, PC, RPLN, liver, lung	NR	NR	Visual	Yes

LPS, laparoscopy; NR, not reported; PC, peritoneal carcinomatosis; PET, positron emission tomography; RPLN, retroperitoneal lymph node; SUV_{max}, maximum standardized uptake value.

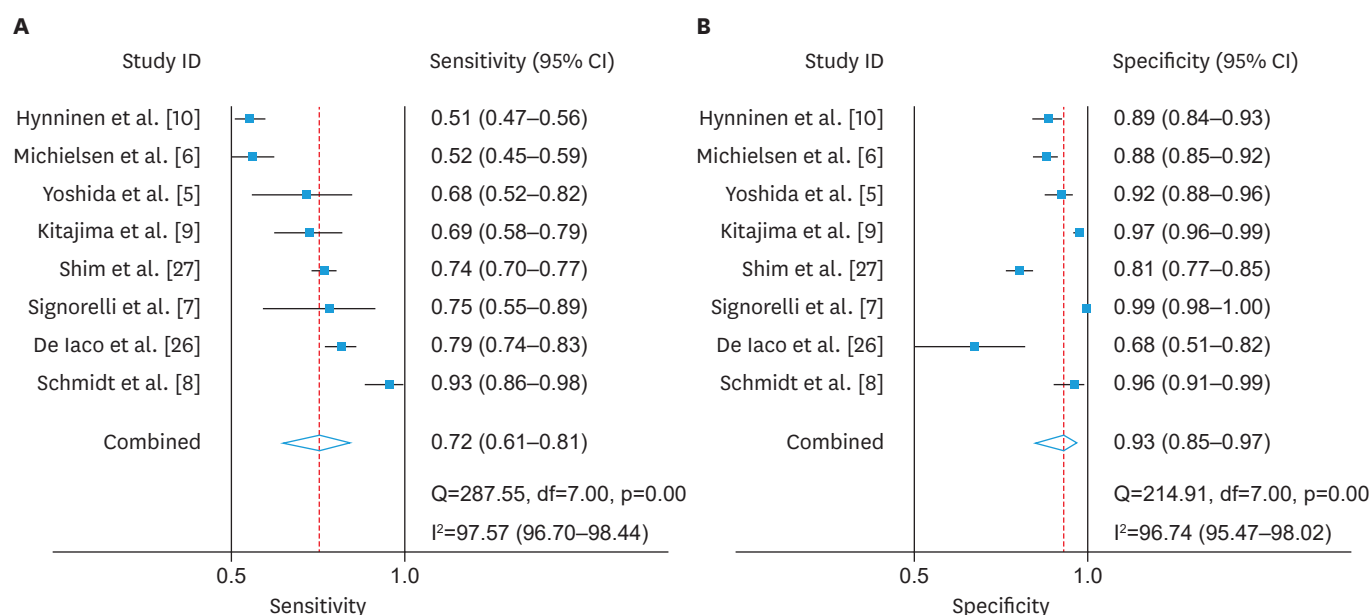


Fig. 2. Coupled forest plots of pooled sensitivity and specificity. CI, confidence interval.

4. Diagnostic accuracy and heterogeneity assessment

Across all eight included studies, the pooled sensitivity and specificity of ^{18}F -FDG PET/CT for identifying the presence of metastasis were 0.72 (95% confidence interval [CI]=0.61–0.81) and 0.93 (95% CI=0.85–0.97), respectively (**Fig. 2**). The pooled PLR and NLR were 10.5 (95% CI=4.5–24.5) and 0.30 (95% CI=0.20–0.44), respectively. The area under the HSROC curve was 0.89 (95% CI=0.86–0.91) (**Supplementary Fig. 2**). Higgins I^2 statistic demonstrated considerable heterogeneity in sensitivity ($I^2=97.57\%$) and specificity ($I^2=96.74\%$). No threshold effect was observed ($p=0.003$). The Deeks funnel plot suggested the presence of publication bias, with a p value of 0.08 (**Supplementary Fig. 3**).

5. Heterogeneity exploration

Sensitivity analysis results are presented in **Table 3**. Sensitivity and specificity estimates were significantly higher in studies that used laparotomy as the reference standard than in those that included diagnostic laparoscopy (sensitivity: 0.77; 95% CI=0.67–0.87 vs. 0.62; 95% CI=0.46–0.77; $p=0.02$; specificity: 0.96; 95% CI=0.92–0.99 vs. 0.84; 95% CI=0.69–0.99; $p=0.01$). Specificity estimates were significantly higher in studies that confirmed surgical findings by pathologic evaluation than in the study without histopathologic confirmation (0.95; 95% CI=0.90–0.99 vs. 0.69; 95% CI=0.24–1.00; $p=0.03$). Studies with a greater proportion ($\geq 70\%$) of the FDG-avid subtype showed lower specificity than those with a lower proportion ($< 70\%$) (0.89; 95% CI=0.80–0.97 vs. 0.97; 95% CI=0.94–1.00). There were no significant differences in sensitivity and specificity estimates with regard to the International Federation of Gynecology and Obstetrics (FIGO) stage, scanner type, or PET interpretation method. However, pooled estimates for these subgroups were considered unstable because only 1 or 2 studies were included in each subgroup.

6. Subgroup analysis and clinical application

Subgroup analyses were performed for detecting peritoneal carcinomatosis (PC) and RPLN metastasis. Subanalysis for PC included data from seven studies with 526 patients. The pooled

Table 3. Sensitivity analysis results

Covariate	No. of studies	Sensitivity (95% CI)	p	Specificity (95% CI)	p
Study design					
Prospective	4	0.71 [0.56–0.86]	0.28	0.96 [0.91–1.00]	0.61
Retrospective	4	0.73 [0.60–0.87]	-	0.89 [0.79–1.00]	-
Patient selection					
Pathologically confirmed	2	0.75 [0.56–0.95]	0.72	0.96 [0.89–1.00]	0.47
Clinically suspected	6	0.71 [0.59–0.83]	-	0.92 [0.85–0.99]	-
Reference					
Diagnostic LPS included	3	0.62 [0.46–0.77]	0.02	0.84 [0.69–0.99]	0.01
Laparotomy	5	0.77 [0.67–0.87]	-	0.96 [0.92–0.99]	-
Pathologic evaluation					
Yes	7	0.71 [0.60–0.82]	0.37	0.95 [0.90–0.99]	0.03
No	1	0.79 [0.57–1.00]	-	0.69 [0.24–1.00]	-
FIGO stage*					
Early stage included	6	0.71 [0.59–0.83]	0.22	0.96 [0.93–0.99]	0.14
Advanced stage only	2	0.76 [0.60–0.93]	-	0.77 [0.55–0.99]	-
Prevalence of FDG-avid subtype†					
≥70%	5	0.76 [0.64–0.87]	0.88	0.89 [0.80–0.97]	0.01
<70%	3	0.66 [0.48–0.85]	-	0.97 [0.94–1.00]	-
Type of scanner					
Hybrid PET/CT	6	0.75 [0.65–0.85]	0.69	0.94 [0.88–1.00]	0.69
Stand-alone PET included	2	0.60 [0.38–0.82]	-	0.91 [0.77–1.00]	-
PET interpretation					
SUV _{max} >2 g/mL	1	0.79 [0.57–1.00]	0.92	0.69 [0.24–1.00]	0.08
Visual	7	0.71 [0.60–0.82]	-	0.95 [0.90–0.99]	-

CI, confidence interval; CT, computed tomography; FDG, fluorodeoxyglucose; FIGO, International Federation of Gynecology and Obstetrics; LPS, laparoscopy; PET, positron emission tomography; SUV_{max}, maximum standardized uptake value.

*FIGO stages I and II were regarded as early stage; †The FDG-avid subtype comprised serous, endometrioid, and undifferentiated tumors.

sensitivity and specificity were 0.70 (95% CI=0.56–0.82) and 0.90 (95% CI=0.82–0.94), respectively, and the pooled PLR and NLR were 7.0 (95% CI=3.7–13.2) and 0.33 (95% CI=0.21–0.52), respectively. The area under the HSROC curve was 0.89 (95% CI=0.86–0.91). Subanalysis for RPLN metastasis included 6 studies with 211 patients. The pooled sensitivity and specificity were 0.77 (95% CI=0.61–0.87) and 0.97 (95% CI=0.93–0.99), respectively, and the pooled PLR and NLR were 28.5 (95% CI=10.5–77.2) and 0.24 (95% CI=0.13–0.43). The area under the HSROC curve was 0.95 (95% CI=0.92–0.96). The subgroup analysis for detecting distant metastasis was not performed because of the paucity of studies.

At a pre-test probability of 20%, a positive result for RPLN metastasis remarkably increased the post-test probability (88%), whereas a positive result for PC moderately increased the post-test probability (63%) (**Fig. 3**). At a pre-test probability of 60%, positive results for PC and RPLN metastases increased the post-test probability by up to 91% and 98%, respectively. Negative results for these conditions moderately reduced the post-test probability to 33% and 26%, respectively.

DISCUSSION

We evaluated the performance of pre-treatment ¹⁸F-FDG PET/CT as a staging modality for detecting metastasis in ovarian cancer. Previous meta-analyses investigating the role of ¹⁸F-FDG PET/CT in ovarian cancer focused on diagnosing recurrent disease [28] or detecting metastasis in a mixed primary/recurrent population [4,29]. The present meta-analysis provided a comprehensive overview of literature, explored the causes of heterogeneity, and investigated the clinical application of the staging performance of ¹⁸F-FDG PET/CT in practice. The sensitivity

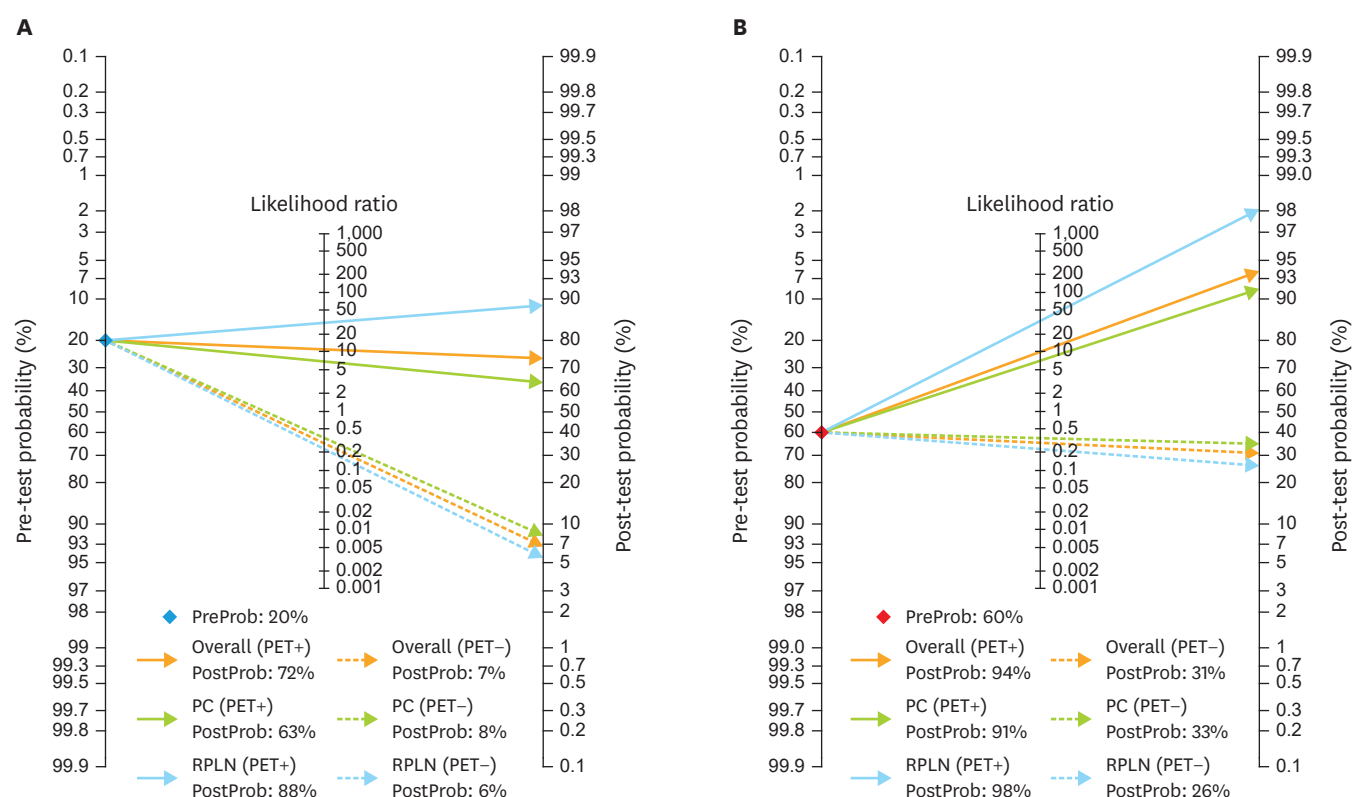


Fig. 3. Fagan's nomogram for pre-test probabilities of (A) 20% and (B) 60%.

PC, peritoneal carcinomatosis; PET, positron emission tomography; PostProb, post-test probability; PreProb, pre-test probability; RPLN, retroperitoneal lymph node.

and specificity of ^{18}F -FDG PET/CT for revealing metastasis, pooled across the eight included studies, were 0.72 (95% CI=0.61–0.81) and 0.93 (95% CI=0.85–0.97), respectively.

There was considerable heterogeneity among the included studies. Comprehensive sensitivity analyses provided some insight into the potential causes of heterogeneity. Studies that used laparotomy as the reference standard showed significantly higher sensitivity and specificity than those that included diagnostic laparoscopy. There has been no conclusive evidence that laparoscopic staging is comparable to standard surgical staging by laparotomy in either the advanced disease or apparent early stage ovarian cancer [30]. With laparoscopy, it can be difficult to assess some abdominal regions, including the retrohepatic area, hepatophrenic junction, and porta hepatis [31]. Tumor deposits at the peritoneal folding and in the subdiaphragmatic space can be missed because laparoscopy lacks the tactile sense [32]. Biopsy under laparoscopy is technically demanding and occasionally unsuccessful because of adhesions or unsatisfactory exposure [33]. Some FDG-avid lesions may be missed due to technical problems, leading to false-positive results and thus low specificity. There was a significant difference in specificity estimates between studies with and those without histologic surgical specimen evaluations. This difference may be attributable to a study [26] that used only diagnostic laparoscopy as the reference standard and showed a much lower specificity (0.69) than other studies. The low sensitivity in studies that included laparoscopy was difficult to explain because there may have been more false-negative cases in the setting of laparotomy. One explanation could be that laparoscopic staging was preferentially performed in early stage ovarian cancer, thus leading equivocal ^{18}F -FDG PET/CT findings to negative.

It is well known that FDG-avidity is important for the diagnostic accuracy of ^{18}F -FDG PET/CT. Studies with a lower prevalence of the FDG-avid subtype showed higher specificity than those with a greater prevalence. A possible partial explanation is that interpretations are prone to be negative under the assumption that a primary lesion is FDG-non avid. Sensitivity was higher in studies with a greater prevalence of the FDG-avid subtype, but this difference was not statistically significant because of the wide confidence interval as a result of pooling three studies with low prevalence.

Lesion size is another well-known factor that affects the diagnostic accuracy of ^{18}F -FDG PET/CT. Although positive correlations between lesion size and PET positivity have been reported [7,9,26], sensitivity analysis with regard to lesion size was not possible because the type of description for size varied (mean \pm standard deviation, median value with range, and classification into categorized values). Further studies are needed to clarify this issue. In addition, the numbers of patients and lesions varied among the included studies, which may be explained by the differences in the FIGO stage, extent of surgery, and image analysis methods. These discrepancies could result in heterogeneity.

Our analysis showed that pre-treatment ^{18}F -FDG PET/CT provided moderate sensitivity and high specificity for detecting metastasis in ovarian cancer. The likelihood ratios and post-test probabilities provided information relevant to clinicians. For instance, at a pre-test likelihood of 60%, which is the probability of unknown patients having advanced disease, PET-positive results of both PC and RPLN metastasis increased post-test likelihood to >90%. Test positivity of ^{18}F -FDG PET/CT provided a reliable estimate to clinicians for the risk of lymph node metastasis. The use of ^{18}F -FDG PET/CT moderately improved the probability of PC. Depending on its location, a test-positive lesion may require a modified surgical approach or can be interpreted as a resectable condition that may require surgical subspecialty expertise (such as hepatic metastasis, implant near the hepatic vein, or bowel implant) or a potentially non-resectable condition (such as mesenteric root involvement or suprarenal lymph node metastasis) with a low false-positive rate of ^{18}F -FDG PET/CT [3]. However, surgical staging is still required because the possibility of a false-negative result cannot be overlooked. The detection of distant metastasis is another important role of ^{18}F -FDG PET/CT for accurate staging. In general, ^{18}F -FDG PET/CT has been known to be effective for the identification of distant metastases at pretreatment evaluation in patients with ovarian cancer [34]. However, we could not provide meta-analytically pooled estimates for detecting distant metastasis because only three of the included studies evaluated distant metastasis.

There were limitations to this meta-analysis. Only eight studies were included. A systematic search of the literature without language restrictions could only identify 8 studies for evidence synthesis. Nevertheless, the meta-analysis provides a general overview of the currently available literature on this topic. Further, there was considerable heterogeneity in the pooled analysis, suggesting a need for exercising caution in applying summary estimates more generally. The type of reference standard used, use of histopathologic confirmation, and prevalence of the FDG-avid subtype may explain some of the heterogeneity, but part remains unexplained. Additionally, our pooled results were site-based, making them prone to overestimation compared with those from a per-lesion analysis. Nevertheless, none of the included studies provided a lesion-based analysis because the head-to-head comparison of surgical and PET/CT findings is not realistically feasible. Finally, publication bias affected included studies; studies with no significant or unfavorable results are more likely to be discarded. It is therefore possible that the diagnostic performance of ^{18}F -FDG PET/CT was overestimated in this meta-analysis.

In conclusion, pre-treatment ^{18}F -FDG PET/CT showed moderate sensitivity and high specificity for detecting metastasis in ovarian cancer. With its low false-positive rate, ^{18}F -FDG PET/CT can help decide the selection of surgical approaches or alternative treatment options. However, surgical staging is required even with negative results because of the considerable false-negative rate.

SUPPLEMENTARY MATERIALS

Supplementary Material

Study protocol

[Click here to view](#)

Supplementary Table 1

PET/CT characteristics

[Click here to view](#)

Supplementary Fig. 1

Grouped bar charts summarizing quality assessments.

[Click here to view](#)

Supplementary Fig. 2

HSROC curve for the staging performance of pre-treatment PET/CT in ovarian cancer.

[Click here to view](#)

Supplementary Fig. 3

The Deeks' funnel plot of the eight included studies suggested the presence of publication bias.

[Click here to view](#)

REFERENCES

1. Siegel RL, Miller KD, Jemal A. Cancer statistics, 2017. *CA Cancer J Clin* 2017;67:7-30.
[PUBMED](#) | [CROSSREF](#)
2. Disaia PJ, Creasman WT, Mannel RS, McMeekin DS, Mutch DG. *Clinical gynecologic oncology*. 9th ed. Philadelphia, PA: Elsevier; 2017.
3. Nougaret S, Addley HC, Colombo PE, Fujii S, Al Sharif SS, Tirumani SH, et al. Ovarian carcinomatosis: how the radiologist can help plan the surgical approach. *Radiographics* 2012;32:1775-800.
[PUBMED](#) | [CROSSREF](#)
4. Suppiah S, Chang WL, Hassan HA, Kaewput C, Asri AA, Saad FF, et al. Systematic review on the accuracy of positron emission tomography/computed tomography and positron emission tomography/magnetic resonance imaging in the management of ovarian cancer: Is functional information really needed? *World J Nucl Med* 2017;16:176-85.
[PUBMED](#) | [CROSSREF](#)

5. Yoshida Y, Kurokawa T, Kawahara K, Tsuchida T, Okazawa H, Fujibayashi Y, et al. Incremental benefits of FDG positron emission tomography over CT alone for the preoperative staging of ovarian cancer. *AJR Am J Roentgenol* 2004;182:227-33.
[PUBMED](#) | [CROSSREF](#)
6. Michielsen K, Vergote I, Op de Beeck K, Amant F, Leunen K, Moerman P, et al. Whole-body MRI with diffusion-weighted sequence for staging of patients with suspected ovarian cancer: a clinical feasibility study in comparison to CT and FDG-PET/CT. *Eur Radiol* 2014;24:889-901.
[PUBMED](#) | [CROSSREF](#)
7. Signorelli M, Guerra L, Pirovano C, Crivellaro C, Fruscio R, Buda A, et al. Detection of nodal metastases by ¹⁸F-FDG PET/CT in apparent early stage ovarian cancer: a prospective study. *Gynecol Oncol* 2013;131:395-9.
[PUBMED](#) | [CROSSREF](#)
8. Schmidt S, Meuli RA, Achtari C, Prior JO. Peritoneal carcinomatosis in primary ovarian cancer staging: comparison between MDCT, MRI, and ¹⁸F-FDG PET/CT. *Clin Nucl Med* 2015;40:371-7.
[PUBMED](#) | [CROSSREF](#)
9. Kitajima K, Murakami K, Yamasaki E, Kaji Y, Fukasawa I, Inaba N, et al. Diagnostic accuracy of integrated FDG-PET/contrast-enhanced CT in staging ovarian cancer: comparison with enhanced CT. *Eur J Nucl Med Mol Imaging* 2008;35:1912-20.
[PUBMED](#) | [CROSSREF](#)
10. Hynninen J, Kemppainen J, Lavonius M, Virtanen J, Matomäki J, Oksa S, et al. A prospective comparison of integrated FDG-PET/contrast-enhanced CT and contrast-enhanced CT for pretreatment imaging of advanced epithelial ovarian cancer. *Gynecol Oncol* 2013;131:389-94.
[PUBMED](#) | [CROSSREF](#)
11. Nam EJ, Yun MJ, Oh YT, Kim JW, Kim JH, Kim S, et al. Diagnosis and staging of primary ovarian cancer: correlation between PET/CT, Doppler US, and CT or MRI. *Gynecol Oncol* 2010;116:389-94.
[PUBMED](#) | [CROSSREF](#)
12. Funicelli L, Travaini LL, Landoni F, Trifirò G, Bonello L, Bellomi M. Peritoneal carcinomatosis from ovarian cancer: the role of CT and [¹⁸F]FDG-PET/CT. *Abdom Imaging* 2010;35:701-7.
[PUBMED](#) | [CROSSREF](#)
13. Castellucci P, Perrone AM, Picchio M, Ghi T, Farsad M, Nanni C, et al. Diagnostic accuracy of ¹⁸F-FDG PET/CT in characterizing ovarian lesions and staging ovarian cancer: correlation with transvaginal ultrasonography, computed tomography, and histology. *Nucl Med Commun* 2007;28:589-95.
[PUBMED](#) | [CROSSREF](#)
14. Dauwen H, Van Calster B, Deroose CM, Op de Beeck K, Amant F, Neven P, et al. PET/CT in the staging of patients with a pelvic mass suspicious for ovarian cancer. *Gynecol Oncol* 2013;131:694-700.
[PUBMED](#) | [CROSSREF](#)
15. Narayanan P, Sahdev A. The role of ¹⁸F-FDG PET CT in common gynaecological malignancies. *Br J Radiol* 2017;90:20170283.
[PUBMED](#) | [CROSSREF](#)
16. Liberati A, Altman DG, Tetzlaff J, Mulrow C, Gøtzsche PC, Ioannidis JP, et al. The PRISMA statement for reporting systematic reviews and meta-analyses of studies that evaluate health care interventions: explanation and elaboration. *PLoS Med* 2009;6:e1000100.
[PUBMED](#) | [CROSSREF](#)
17. Meinhold-Heerlein I, Fotopoulou C, Harter P, Kurzeder C, Mustea A, Wimberger P, et al. Statement by the Kommission Ovar of the AGO: the new FIGO and WHO classifications of ovarian, fallopian tube and primary peritoneal cancer. *Geburtshilfe Frauenheilkd* 2015;75:1021-7.
[PUBMED](#) | [CROSSREF](#)
18. Cantuaria G, Fagotti A, Ferrandina G, Magalhaes A, Nadji M, Angioli R, et al. GLUT-1 expression in ovarian carcinoma: association with survival and response to chemotherapy. *Cancer* 2001;92:1144-50.
[PUBMED](#) | [CROSSREF](#)
19. Kurokawa T, Yoshida Y, Kawahara K, Tsuchida T, Okazawa H, Fujibayashi Y, et al. Expression of GLUT-1 glucose transfer, cellular proliferation activity and grade of tumor correlate with [¹⁸F]-fluorodeoxyglucose uptake by positron emission tomography in epithelial tumors of the ovary. *Int J Cancer* 2004;109:926-32.
[PUBMED](#) | [CROSSREF](#)
20. Whiting PF, Rutjes AW, Westwood ME, Mallett S, Deeks JJ, Reitsma JB, et al. QUADAS-2: a revised tool for the quality assessment of diagnostic accuracy studies. *Ann Intern Med* 2011;155:529-36.
[PUBMED](#) | [CROSSREF](#)

21. Chong GO, Jeong SY, Park SH, Lee YH, Lee SW, Hong DG, et al. Comparison of the prognostic value of F-18 pet metabolic parameters of primary tumors and regional lymph nodes in patients with locally advanced cervical cancer who are treated with concurrent chemoradiotherapy. *PLoS One* 2015;10:e0137743.
[PUBMED](#) | [CROSSREF](#)
22. Deeks JJ, Macaskill P, Irwig L. The performance of tests of publication bias and other sample size effects in systematic reviews of diagnostic test accuracy was assessed. *J Clin Epidemiol* 2005;58:882-93.
[PUBMED](#) | [CROSSREF](#)
23. Higgins J, Green S. *Cochrane handbook for systematic reviews of interventions* version 5.1.0. [Internet]. London: The Cochrane Collaboration; c2017 [cited 2017 Nov 15]. Available from: http://handbook.cochrane.org/chapter_9/9_5_2_identifying_and_measuring_heterogeneity.htm.
24. Fagan TJ. Letter: nomogram for Bayes theorem. *N Engl J Med* 1975;293:257.
[PUBMED](#) | [CROSSREF](#)
25. Howlode N, Noone A, Krapcho M, Miller D, Bishop K, Kosary C, et al. *Seer cancer statistics review, 1975–2014*. [Internet]. Bethesda, MD: National Cancer Institute; c2017 [cited 2018 Jan 8]. Available from: https://seer.cancer.gov/csr/1975_2014/.
26. De Iaco P, Musto A, Orazi L, Zamagni C, Rosati M, Allegri V, et al. FDG-PET/CT in advanced ovarian cancer staging: value and pitfalls in detecting lesions in different abdominal and pelvic quadrants compared with laparoscopy. *Eur J Radiol* 2011;80:e98-103.
[PUBMED](#) | [CROSSREF](#)
27. Shim SH, Lee SJ, Kim SO, Kim SN, Kim DY, Lee JJ, et al. Nomogram for predicting incomplete cytoreduction in advanced ovarian cancer patients. *Gynecol Oncol* 2015;136:30-6.
[PUBMED](#) | [CROSSREF](#)
28. Gu P, Pan LL, Wu SQ, Sun L, Huang G. CA 125, PET alone, PET-CT, CT and MRI in diagnosing recurrent ovarian carcinoma: a systematic review and meta-analysis. *Eur J Radiol* 2009;71:164-74.
[PUBMED](#) | [CROSSREF](#)
29. Yuan Y, Gu ZX, Tao XF, Liu SY. Computer tomography, magnetic resonance imaging, and positron emission tomography or positron emission tomography/computer tomography for detection of metastatic lymph nodes in patients with ovarian cancer: a meta-analysis. *Eur J Radiol* 2012;81:1002-6.
[PUBMED](#) | [CROSSREF](#)
30. Falcetta FS, Lawrie TA, Medeiros LR, da Rosa MI, Edelweiss MI, Stein AT, et al. Laparoscopy versus laparotomy for FIGO stage I ovarian cancer. *Cochrane Database Syst Rev* 2016;10:CD005344.
[PUBMED](#) | [CROSSREF](#)
31. Brun JL, Rouzier R, Uzan S, Daraï E. External validation of a laparoscopic-based score to evaluate resectability of advanced ovarian cancers: clues for a simplified score. *Gynecol Oncol* 2008;110:354-9.
[PUBMED](#) | [CROSSREF](#)
32. Koo YJ, Kim JE, Kim YH, Hahn HS, Lee IH, Kim TJ, et al. Comparison of laparoscopy and laparotomy for the management of early-stage ovarian cancer: surgical and oncological outcomes. *J Gynecol Oncol* 2014;25:111-7.
[PUBMED](#) | [CROSSREF](#)
33. Abu-Rustum NR, Chi DS, Sonoda Y, DiClemente MJ, Bekker G, Gemignani M, et al. Transperitoneal laparoscopic pelvic and para-aortic lymph node dissection using the argon-beam coagulator and monopolar instruments: an 8-year study and description of technique. *Gynecol Oncol* 2003;89:504-13.
[PUBMED](#) | [CROSSREF](#)
34. Khiewvan B, Torigian DA, Emamzadehfard S, Paydary K, Salavati A, Houshmand S, et al. An update on the role of PET/CT and PET/MRI in ovarian cancer. *Eur J Nucl Med Mol Imaging* 2017;44:1079-91.
[PUBMED](#) | [CROSSREF](#)