

## Video Article



# Early ovarian cancer surgery with indocyanine-green-guided targeted compartmental lymphadenectomy (TCL, pelvic part)

Rainer Kimmig , Paul Buderath, Peter Rusch , Pawel Mach , Bahriye Aktas

Department of Gynecology and Obstetrics, West German Cancer Center, University Hospital Essen, University of Duisburg-Essen, Essen, Germany

## OPEN ACCESS

**Received:** Mar 24, 2017

**Revised:** May 23, 2017

**Accepted:** Jun 2, 2017

### Correspondence to

Rainer Kimmig

Department of Gynecology and Obstetrics,  
West German Cancer Center, University  
Hospital Essen, University of Duisburg-Essen,  
Hufelandstraße 55, Essen 45133, Germany.  
E-mail: rainer.kimmig@uk-essen.de

**Copyright** © 2017. Asian Society of  
Gynecologic Oncology, Korean Society of  
Gynecologic Oncology  
This is an Open Access article distributed  
under the terms of the Creative Commons  
Attribution Non-Commercial License (<https://creativecommons.org/licenses/by-nc/4.0/>)  
which permits unrestricted non-commercial  
use, distribution, and reproduction in any  
medium, provided the original work is properly  
cited.

### ORCID iDs

Rainer Kimmig

<https://orcid.org/0000-0003-1118-2199>

Peter Rusch

<https://orcid.org/0000-0002-4890-3503>

Pawel Mach

<https://orcid.org/0000-0002-7301-6746>

Bahriye Aktas

<https://orcid.org/0000-0002-5474-051X>

## ABSTRACT

**Objective:** Para-aortic indocyanine-green (ICG)-guided targeted compartmental lymphadenectomy is feasible in early ovarian cancer [1]; systematic pelvic and para-aortic lymphadenectomy could potentially be avoided if thoroughly investigated sentinel nodes could predict whether residual nodes will be involved or free of disease. In contrast to advanced ovarian cancer, where the therapeutic potential of lymphadenectomy will soon be clarified by the results of the Arbeitsgemeinschaft Gynäkologische Onkologie lymphadenectomy in ovarian neoplasms (AGO LION) trial, systematic lymphadenectomy seems to be mandatory for diagnostic and also therapeutic purposes in early ovarian cancer [2-4]. Sentinel node biopsy or resection of the regional lymphatic network may reduce morbidity compared to systematic lymphadenectomy as shown already for other entities [5-7]. Apart from the ovarian mesonephric pathway [1], a second Müllerian uterine pathway exists for lymphatic drainage of the ovary [8]. Lymphatic valves apparently do not exist at this level of the utero-ovarian network since injection of radioactivity into the ovarian ligaments also labelled pelvic nodes [9].

**Methods:** We applied ICG using 4×0.5 mL of a 1.66 mg/mL ICG solution for transcervical injection into the fundal and midcorporal myometrium at each side [10] instead of injection into the infundibulopelvic ligament, since the utero-ovarian drainage was intact.

**Results:** In this case a 1.8 cm cancer of the right ovary was removed in continuity with its draining lymphatic vessels and at least the first 2 sentinel nodes in each channel “en bloc” as shown in this video for the pelvic part, consistent with the loco-regional ontogenetic approach [11,12].

**Conclusion:** This could potentially avoid most of systematic lymphadenectomies in early ovarian cancer.

**Keywords:** Lymph Node Excision; Indocyanine Green; Ovarian Neoplasms

### Conflict of Interest

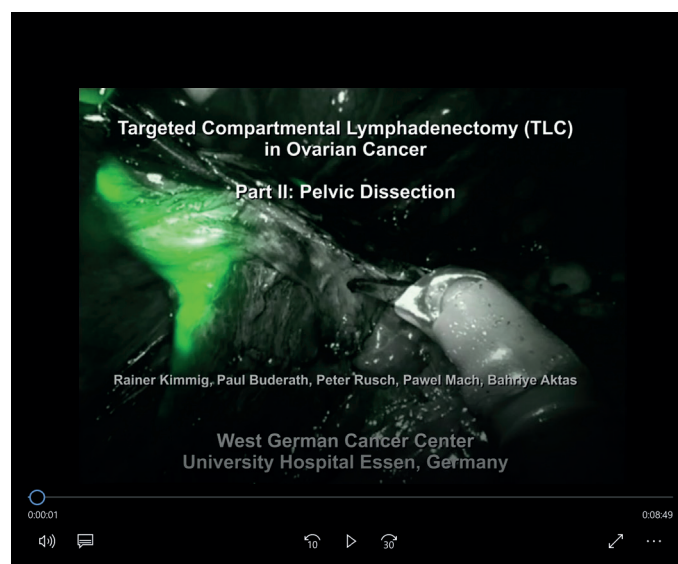
No potential conflict of interest relevant to this article was reported.

### Author Contributions

Conceptualization: K.R.; Data curation: B.P., R.P.; Formal analysis: K.R., M.P.; Investigation: K.R.; Methodology: K.R., B.P., R.P., A.B.; Project administration: K.R.; Resources: K.R.; Software: M.P.; Supervision: K.R.; Validation: K.R., A.B.; Visualization: K.R.; Writing - original draft: K.R.; Writing - review & editing: K.R., M.P., B.P., R.P., A.B.

## VIDEO CLIP

Early ovarian cancer surgery with indocyanine-green-guided targeted compartmental lymphadenectomy.



Video can be found with this article online at <https://ejgo.org/src/sm/jgo-28-e68-s001.mp4>.

## REFERENCES

1. Kimmig R, Buderath P, Mach P, Rusch P, Aktas B. Surgical treatment of early ovarian cancer with compartmental resection of regional lymphatic network and indocyanine-green-guided targeted compartmental lymphadenectomy (TCL, paraaortic part). *J Gynecol Oncol* 2017;28:e41.  
[PUBMED](#) | [CROSSREF](#)
2. Camara O, Sehouli J. Controversies in the management of ovarian cancer--pros and cons for lymph node dissection in ovarian cancer. *Anticancer Res* 2009;29:2837-43.  
[PUBMED](#)
3. Powless CA, Aletti GD, Bakkum-Gamez JN, Cliby WA. Risk factors for lymph node metastasis in apparent early-stage epithelial ovarian cancer: implications for surgical staging. *Gynecol Oncol* 2011;122:536-40.  
[PUBMED](#) | [CROSSREF](#)
4. Mikami M. Role of lymphadenectomy for ovarian cancer. *J Gynecol Oncol* 2014;25:279-81.  
[PUBMED](#) | [CROSSREF](#)
5. Handgraaf HJ, Verbeek FP, Tummers QR, Boogerd LS, van de Velde CJ, Vahrmeijer AL, et al. Real-time near-infrared fluorescence guided surgery in gynecologic oncology: a review of the current state of the art. *Gynecol Oncol* 2014;135:606-13.  
[PUBMED](#) | [CROSSREF](#)
6. Collarino A, Vidal-Sicart S, Perotti G, Valdés Olmos RA. The sentinel node approach in gynaecological malignancies. *Clin Transl Imaging* 2016;4:411-20.  
[PUBMED](#) | [CROSSREF](#)
7. Cibula D, Oonk MH, Abu-Rustum NR. Sentinel lymph node biopsy in the management of gynecologic cancer. *Curr Opin Obstet Gynecol* 2015;27:66-72.  
[PUBMED](#) | [CROSSREF](#)
8. Kleppe M, Kraima AC, Kruitwagen RF, Van Gorp T, Smit NN, van Munsteren JC, et al. Understanding lymphatic drainage pathways of the ovaries to predict sites for sentinel nodes in ovarian cancer. *Int J Gynecol Cancer* 2015;25:1405-14.  
[PUBMED](#) | [CROSSREF](#)

9. Kleppe M, Brans B, Van Gorp T, Slangen BF, Kruse AJ, Pooters IN, et al. The detection of sentinel nodes in ovarian cancer: a feasibility study. *J Nucl Med* 2014;55:1799-804.  
[PUBMED](#) | [CROSSREF](#)
10. Kimmig R, Aktas B, Buderath P, Rusch P, Heubner M. Intraoperative navigation in robotically assisted compartmental surgery of uterine cancer by visualisation of embryologically derived lymphatic networks with indocyanine-green (ICG). *J Surg Oncol* 2016;113:554-9.  
[PUBMED](#) | [CROSSREF](#)
11. Höckel M. Morphogenetic fields of embryonic development in locoregional cancer spread. *Lancet Oncol* 2015;16:e148-51.  
[PUBMED](#) | [CROSSREF](#)
12. Santiago IA, Gomes AP, Heald RJ. An ontogenetic approach to gynecologic malignancies. *Insights Imaging* 2016;7:329-39.  
[PUBMED](#) | [CROSSREF](#)