

Video Article



Surgical treatment of early ovarian cancer with compartmental resection of regional lymphatic network and indocyanine-green-guided targeted compartmental lymphadenectomy (TCL, paraaortic part)

Rainer Kimmig , Paul Buderath, Pawel Mach , Peter Rusch, Bahriye Aktas

Department of Gynecology and Obstetrics, West-German Cancer Center, University of Duisburg-Essen, Essen, Germany

OPEN ACCESS

Received: Jan 31, 2017

Revised: Feb 28, 2017

Accepted: Mar 5, 2017

Correspondence to

Rainer Kimmig

Department of Gynecology and Obstetrics,
West-German Cancer Center, University of
Duisburg-Essen, Hufelandstraße 55,
Essen 45147, Germany.
E-mail: rainer.kimmig@uk-essen.de

Copyright © 2017. Asian Society of
Gynecologic Oncology, Korean Society of
Gynecologic Oncology
This is an Open Access article distributed
under the terms of the Creative Commons
Attribution Non-Commercial License (<https://creativecommons.org/licenses/by-nc/4.0/>)
which permits unrestricted non-commercial
use, distribution, and reproduction in any
medium, provided the original work is properly
cited.

ORCID iDs

Rainer Kimmig
<https://orcid.org/0000-0003-1118-2199>
Pawel Mach
<https://orcid.org/0000-0002-7301-6746>

ABSTRACT

Objective: Whether pelvic and para-aortic lymphadenectomy is of therapeutic benefit in advanced ovarian cancer will remain unclear until the publication of the Arbeitsgemeinschaft Gynäkologische Onkologie lymphadenectomy in ovarian neoplasms (AGO LION) trial. In early ovarian cancer, however, lymphadenectomy seems mandatory for diagnostic and also therapeutic reasons [1-3].

Methods: Complete systematic lymphadenectomy is accompanied by morbidity which may be reduced by sentinel node biopsy already established for several solid tumors [4-6]. In ovarian cancer there are 2 main pathways in lymphatic drainage: along the ovarian vessels to the para-aortic nodes and the uterine vessels to the iliac lymph compartments [7]. Following injection of radioactive dye into the ovarian ligaments this could be confirmed suggesting that there is bidirectional flow at this level of the ovarian and uterine lymphatic pathways [8]. Indocyanine-green-guided (ICG) injection to the uterine corpus seems to be equally effective in labelling the “uterine Müllerian” and the “ovarian mesonephric” lymphatic drainage of the ovary [9,10].

Results: This technique [9] was applied and will be outlined in the video showing the procedure with respect to the para-aortic lymphatic drainage. Isolated sentinel node biopsy and tumor excision will not resect the organ compartment together with its super-ordinated draining lymphatic system at risk.

Conclusion: Thus, the authors suggest to remove the malignancy together with its draining lymphatic vessels and at least the first 2 sentinel nodes in each channel en bloc; we propose to analyze this procedure consistent with the ontogenetic approach [11, 12] with respect to diagnostic accuracy and loco-regional control. This could potentially avoid most of systematic lymphadenectomies in early ovarian cancer.

Keywords: Sentinel Lymph Node; Lymph Node Excision; Indocyanine Green; Robotic Surgery; Ovarian Neoplasms

Conflict of Interest

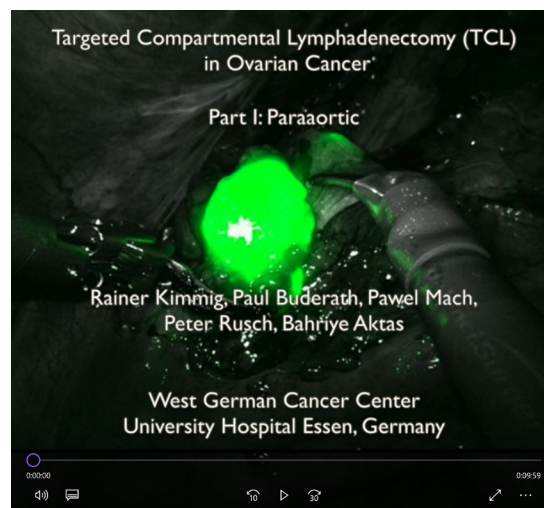
RK received honoraries for proctoring and presentations from Intuitive Surgical Inc., PB, PM, PR, and BA have no potential conflict of interest.

Author Contributions

Conceptualization: K.R., A.B.; Data curation: M.P.; Formal analysis: B.P., M.P.; Investigation: K.R., A.B.; Methodology: K.R., B.P.; Visualization: B.P., M.P., R.P.; Writing - original draft: K.R.; Writing - review & editing: B.P., M.P., R.P., A.B.

VIDEO CLIP

ICG-guided targeted compartmental lymphadenectomy in early ovarian cancer.



Video can be found with this article online at <https://ejgo.org/src/sm/jgo-28-e41-s001.mp4>.

REFERENCES

1. Camara O, Sehouli J. Controversies in the management of ovarian cancer--pros and cons for lymph node dissection in ovarian cancer. *Anticancer Res* 2009;29:2837-43.
[PUBMED](#)
2. Powless CA, Aletti GD, Bakkum-Gamez JN, Cliby WA. Risk factors for lymph node metastasis in apparent early-stage epithelial ovarian cancer: implications for surgical staging. *Gynecol Oncol* 2011;122:536-40.
[PUBMED](#) | [CROSSREF](#)
3. Mikami M. Role of lymphadenectomy for ovarian cancer. *J Gynecol Oncol* 2014;25:279-81.
[PUBMED](#) | [CROSSREF](#)
4. Handgraaf HJ, Verbeek FP, Tummers QR, Boogerd LS, van de Velde CJ, Vahrmeijer AL, et al. Real-time near-infrared fluorescence guided surgery in gynecologic oncology: a review of the current state of the art. *Gynecol Oncol* 2014;135:606-13.
[PUBMED](#) | [CROSSREF](#)
5. Collarino A, Vidal-Sicart S, Perotti G, Valdés Olmos RA. The sentinel node approach in gynaecological malignancies. *Clin Transl Imaging* 2016;4:411-20.
[PUBMED](#) | [CROSSREF](#)
6. Cibula D, Oonk MH, Abu-Rustum NR. Sentinel lymph node biopsy in the management of gynecologic cancer. *Curr Opin Obstet Gynecol* 2015;27:66-72.
[PUBMED](#) | [CROSSREF](#)
7. Kleppe M, Kraima AC, Kruitwagen RF, Van Gorp T, Smit NN, van Munsteren JC, et al. Understanding lymphatic drainage pathways of the ovaries to predict sites for sentinel nodes in ovarian cancer. *Int J Gynecol Cancer* 2015;25:1405-14.
[PUBMED](#) | [CROSSREF](#)
8. Kleppe M, Brans B, Van Gorp T, Slangen BF, Kruse AJ, Pooters IN, et al. The detection of sentinel nodes in ovarian cancer: a feasibility study. *J Nucl Med* 2014;55:1799-804.
[PUBMED](#) | [CROSSREF](#)
9. Kimmig R, Aktas B, Buderath P, Rusch P, Heubner M. Intraoperative navigation in robotically assisted compartmental surgery of uterine cancer by visualisation of embryologically derived lymphatic networks with indocyanine-green (ICG). *J Surg Oncol* 2016;113:554-9.
[PUBMED](#) | [CROSSREF](#)

10. Kimmig R, Aktas B, Buderath P, Heubner M. Robotically assisted peritoneal mesometrial resection (PMMR) in endometrial cancer supported by ICG labeling of the compartmental lymphatic system. *Gynecol Oncol Rep* 2016;16:24.
[PUBMED](#) | [CROSSREF](#)
11. Höckel M. Morphogenetic fields of embryonic development in locoregional cancer spread. *Lancet Oncol* 2015;16:e148-51.
[PUBMED](#) | [CROSSREF](#)
12. Santiago IA, Gomes AP, Heald RJ. An ontogenetic approach to gynecologic malignancies. *Insights Imaging* 2016;7:329-39.
[PUBMED](#) | [CROSSREF](#)