



## Role of paclitaxel and cisplatin as the neoadjuvant treatment for locally advanced squamous cell carcinoma of the vulva

Francesco Raspagliesi<sup>1</sup>, Flavia Zanaboni<sup>1</sup>, Fabio Martinelli<sup>1</sup>, Santiago Scasso<sup>1,2</sup>, Joel Laufer<sup>1,2</sup>, Antonino Ditto<sup>1</sup>

<sup>1</sup>Gynecologic Oncology Unit, Fondazione IRCCS Istituto Nazionale dei Tumori, Milan, Italy; <sup>2</sup>Department of Obstetrics and Gynecology, University of Uruguay School of Medicine, Montevideo, Uruguay

**Objective:** The therapeutic outcomes of patients with advanced vulvar cancer are poor. Multi-modality treatments including concurrent chemoradiation or different regimens of neoadjuvant chemotherapy (NACT), and surgery have been explored to reduce the extent of surgery and morbidity. The present single-institution trial aimed to evaluate the efficacy and toxicity of paclitaxel and cisplatin in locally advanced vulvar cancer.

**Methods:** From 2002 to 2009, 10 patients with stage III-IV locally advanced squamous cell carcinoma of the vulva were prospectively treated with 3 courses of paclitaxel-ifosfamide-cisplatin or paclitaxel-cisplatin. Nine of them subsequently underwent radical local excision or radical partial vulvectomy and bilateral inguino-femoral lymphadenectomy.

**Results:** The clinical response rate of all enrolled patients was 80%, whereas the pathological responses included 1 case with complete remission, 2 with persistent carcinoma *in situ*, and 6 invasive cancer cases with tumor shrinkage of more than 50%. Four patients had positive nodes. Forty percent of patients experienced grade 3-4 bone marrow toxicity, which was successfully managed with granulocyte-colony stimulating factor, even in cases of elderly patients. Median progression-free survival after surgery was 14 months (range, 5 to 44 months). Six of the 7 recurrent cases were local, and 3 of them were treated with salvage surgery while the other 3 received radiation with or without chemotherapy. After a median follow-up period of 40 months (range, 5 to 112 months), 55.5% of patients remained alive with no evidence of disease, including 2 long-term survivors after recurrence at 5 and 9 years.

**Conclusion:** Based on the high response rate and manageable toxicity, NACT with paclitaxel and cisplatin with or without ifosfamide followed by surgery could be considered as a therapeutic option for locally advanced vulvar cancer.

**Keywords:** Locally advanced vulvar cancer, Morbidity, Neoadjuvant chemotherapy, Paclitaxel and cisplatin, Surgical treatment

### INTRODUCTION

Invasive carcinoma of the vulva is a rare disease that accounts for approximately 4% of all gynecologic cancers [1]. In Western countries, the average annual age-adjusted incidence of invasive vulvar carcinoma is 1.2 cases per 100,000 women [2]. Approximately 75% of patients diagnosed with invasive vulvar

cancer are 60 years of age and older, with a peak incidence of 20 cases per 100,000 women older than 70 years of age [3-5].

The current treatment modalities for advanced vulvar cancer patients with inguinal lymph node metastasis involve radical vulvar surgery plus groin dissection and radiotherapy. However, approximately a quarter of patients with squamous cell carcinoma of the vulva would be diagnosed with either advanced or inoperable primary disease [6]. In addition, despite the often mutilating surgery and/or high doses of radiation, therapeutic results are poor. The 5-year survival rates for stage III and IV diseases according to the International Federation of Gynecology and Obstetrics (FIGO) system is 43.2% and 13%,

Received Aug 11, 2013, Revised Sep 26, 2013, Accepted Sep 30, 2013

**Correspondence to** Francesco Raspagliesi  
Gynecologic Oncology Unit, Fondazione IRCCS Istituto Nazionale dei Tumori,  
Via Venezian 1, 20133 Milan, Italy. E-mail: raspagliesi@istitutotumori.mi.it

Copyright © 2014. Asian Society of Gynecologic Oncology, Korean Society of Gynecologic Oncology

This is an Open Access article distributed under the terms of the Creative Commons Attribution Non-Commercial License (<http://creativecommons.org/licenses/by-nc/3.0/>) which permits unrestricted non-commercial use, distribution, and reproduction in any medium, provided the original work is properly cited.

respectively [7]. Radiation therapy alone does not seem to be curative for patients with large vulvar lesions. Conversely, surgical treatment for such advanced cases often requires exenterative procedures with considerable associated morbidity and high incidence of failures. The 5-year survival rate after pelvic exenteration, including urinary diversion and/or colostomy, has been reported to be less than 50%, even in properly selected cases, with a perioperative mortality rate of about 10% and no long-term survivors among patients with positive nodes [8,9]. Therefore, in order to reduce the need for pelvic exenteration, multi-modality treatments, such as chemoradiotherapy plus surgery or neoadjuvant chemotherapy (NACT) followed by surgery, have been explored [10-12].

Although neoadjuvant concurrent chemoradiation offers a chance of cure, it is often associated with high morbidity. Therefore, significant efforts have been spent on determining the optimal chemotherapy combination [13-15].

In comparison to concurrent chemoradiation, NACT offers the advantages of local morbidity reduction and treatment of occult or distant diseases. Moreover, it can be part of the therapeutic armamentarium even in cases where radiation therapy is not available. Despite historical belief that vulvar cancer is not chemosensitive, previous studies have shown promising results. However, the most effective chemotherapeutic regimen remains unknown. Since the late nineties, new regimens such as the paclitaxel, ifosfamide, and cisplatin (TIP) combination, and paclitaxel-cisplatin (TP) therapy have been investigated as the neoadjuvant treatment for advanced squamous cervical cancer with promising response rates ranging from 46% to 66.6% [16-18]. Such results were subsequently confirmed by two randomized trials [19,20].

To the best of our knowledge, the above-mentioned regimens have not been tested in vulvar cancer. Therefore, the present prospective single-institution clinical study aimed to evaluate the tumor response rate, toxicity, and disease resectability after NACT with TP or TIP in locally advanced carcinoma of the vulva.

## MATERIALS AND METHODS

The present study was approved by the Institutional Review Board of the National Cancer Institute in Milan, and all patients provided written informed consent.

Female patients with locally advanced vulvar cancer were prospectively enrolled. The inclusion criteria were: (1) histologically confirmed locally advanced squamous cell carcinoma of the vulva that was not suitable for surgery as the first-line treatment (stages bulky T2 or T3, N0-2, M0-1 [only pelvic

nodes] according to the 1994 tumor-node-metastasis classification), and otherwise only eligible for exenterative surgery; and (2) measurable or evaluable disease. Additionally, patients had to be older than 18 years of age, have World Health Organization performance status of 0-2, life expectancy of >3 months, adequate bone marrow reserve (white blood cell count of >4,000/mm<sup>3</sup>, platelet count of >150,000/mm<sup>3</sup>), adequate liver and renal function (bilirubin concentration of ≤1.5 mg/dL, creatinine clearance of >60 mL/min), and no previous treatment to enroll.

Otherwise, the study excluded patients with previous chemotherapy or radiotherapy, metastatic disease, impossibility of adequate follow-up, other malignancy except adequately treated basal cell skin cancer or carcinoma *in situ* of the cervix, impaired renal (creatinine clearance of <50 mL/min) or liver function (bilirubin concentration of >1.5 mg/dL), and active infection that would impair their ability to receive the treatment protocol.

### 1. Chemotherapy regimens

For TIP, on day 1, paclitaxel was given intravenously (IV) at 175 mg/m<sup>2</sup> in a 3-hour infusion, whereas cisplatin was also administered IV at 50 mg/m<sup>2</sup>. On day 2, ifosfamide at 5 g/m<sup>2</sup> and mesna also at 5 g/m<sup>2</sup> were infused IV in 2 liters of normal saline solution over a 24-hour period. On completion of such infusion, additional mesna at 2 g/m<sup>2</sup> was administered IV in 1 liter of normal saline in a 24-hour infusion.

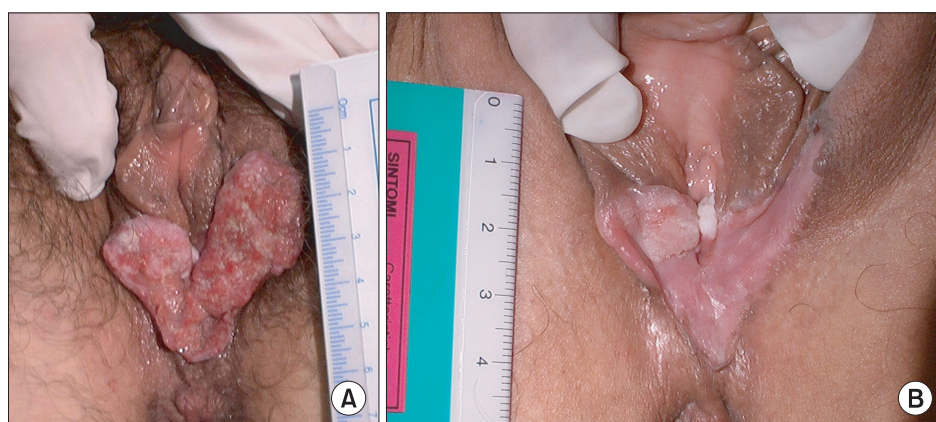
For TP, on the same day, paclitaxel was given IV at 175 mg/m<sup>2</sup> in a 3-hour infusion, whereas cisplatin was also administered IV at 70 mg/m<sup>2</sup> with pre- and postinfusion hydration.

NACT consisted of at least 2 courses, which was repeated every 3 weeks if the patient's granulocyte count was >1,500/mm<sup>3</sup>, and platelet count was >100,000/mm<sup>3</sup> on the treatment scheduled day. Otherwise, treatment was delayed for 1 week. Blood cell counts were performed weekly. One additional cycle of preoperative chemotherapy was given to responders after patient response assessment.

The present study was a non-randomized trial, and the choice of TP or TIP was at the attending physician's discretion, based on each patient's condition. The physician's aim was to avoid ifosfamide administration in older women of >70 years of age or in younger patients with severe comorbidities. Similar to cervical cancer, the number of planned chemotherapy courses was three [19,20] in order to achieve tumor shrinkage while avoiding excessive toxicity and tumor resistance to drugs.

### 2. Response assessment

Response assessment was determined according to the



**Fig. 1.** Vulvar neoplasia T2N2 before treatment (A) and partial response after 3 courses of neoadjuvant chemotherapy (pT1b pN0) (B).

response criteria in solid tumors (RECIST, ver. 1.0) [21]. Local response was monitored via clinical evaluation with lesion measurements and photographs (taken at baseline and after 3 chemotherapy courses) (**Fig. 1**). Response was then evaluated by comparing the calculated tumor areas, obtained from the measurements of two largest diameters of the lesions, before and after treatment. A complete response (CR) was recorded when a lesion completely disappeared, whereas a partial response (PR) was when a tumor decreased at least 30% of its original size. Progressive disease (PD) was considered when a lesion increased more than 20% of its original size, and stable disease (SD) was when changes occurring between PR and PD were observed. Exclusion of metastatic disease was determined by using chest radiographs and abdominal-pelvic computed tomography (CT) at baseline and at the conclusion of treatment. Cystoscopy and proctoscopy were performed in cases of suspected bladder or rectal involvement.

Three weeks from the end of the second cycle, patients were clinically re-evaluated for therapeutic responses. Primary tumor (T) and inguinal node (N) clinical responses were investigated separately. Regardless of the N response, complete and partial T responders received one additional cycle of chemotherapy and subsequently underwent radical surgery. Patients showing minimal response or SD after the 2<sup>nd</sup> course were reconsidered for immediate radical surgery, while those with PD were submitted to radiotherapy on an individual basis.

### 3. Surgery

The surgical approach in this study consisted of radical partial vulvectomy or radical local excision with a tumor-free margin of at least 2 cm in bilateral radical inguinal lymph node dissection [22]. Lymphadenectomy included the removal of all nodes superficial to the cribriform fascia and lateral to the femoral vein. Such dissection and node extirpation continued

deep to the adductor longus muscle and medial to the femoral vein. Attempt was made to preserve the saphenous vein. In cases of bulky nodes, dissection of the obturator, external iliac, and caudal part of the common iliac lymph node chains were included as part of the pelvic lymphadenectomy procedure. Closed suction drains were placed in each groin incision and removed when the total output was less than 80–100 mL per 24 hours. All above-mentioned procedures were performed by the same surgeons.

### 4. Toxicity assessment

Toxicity was evaluated according to the National Cancer Institute Common Toxicity Criteria version 2.0 [23].

## RESULTS

Between November 2002 and April 2009, 10 patients with locally advanced vulvar cancer were treated. The patients' median age was 70 years (range, 47–78 years). Patient characteristics and outcomes are shown in **Table 1**. Six women had clinical FIGO stage III disease, 3 had stage IVA tumors, and 1 had a stage IVB cancer. Two cases were of grade 1, 6 of grade 2, and 2 of grade 3. Eight patients were clinically suspected for unilateral or bilateral inguinal node metastasis, and 6 were subsequently confirmed by performing CT scans. Cytological and/or histological evaluation of suspicious groin nodes (cN1–N2) was not performed before treatment.

All but one patient received 3 courses of TIP (n=4) or TP (n=5). The initially scheduled TP was modified by suspending paclitaxel at the second course in 1 patient due to toxicity. Eight clinical objective responses were observed (3 CR and 5 PR). One case showed SD, whereas the remaining 1 patient had PD and was submitted to chemoradiation after two cycles of TP. That patient experienced distant metastases

Table 1. Patients' characteristics and outcomes

Patient no.	Age (yr)	Comorbidities	Clinical stage TNM/FIGO	Grade	NACT scheme	Tumor diameters pre & post (cm)	Clinical response	pN N+/N total	Resection margin	Adjuvant therapy	Site of relapse	PFS (mo)	OS (mo)	Status
1	47	None	T2N2/IVA	2	TIP	5×3, 1×1	PR	0/19	Right and vaginal	CHT (TIP×3)	Vulvar	5	112	NED
2	65	Previous MI, type 1 DM, hypertension	T2N1/III	2	TIP	4×3, 0	CR	0/17	Negative	-	-	109	109	Alive with anal cancer
3	69	AF, obesity, DVT, UC	T2N2/IVA	3	TP	5×5, 0	CR	0/22	Negative	-	Vulvar	44	103	NED
4	66	None	T3N0/III	3	TIP	3×2, 1×1	PR	0/17	Anal	-	Perianal	10	25	DOD
5	77	Hypertension	T2N1/III	1	TP	4×4, 4×3	SD	1/13	Vaginal	RT	Vulvar	14	21	DOD
6	67	Hepatitis C	T2N1/III	1	TP	2.5×1.5, 0.6×0.5	PR	0/17	Negative	-	Perianal+ nodes	34	52	NED
7	62	Type 2 DM	T3N1/III	2	TIP	4×4, 2.5×1.5	PR	1/18	Negative	RT	-	44	44	NED
8	73	Type 2 DM, hypertension	T3N0/III	2	TP	6×4, 0	CR	1/20	Negative	RT	Vulvar	28	35	NED
9	78	Type 2 DM, angina, hypertension	T3N2M1/IVB	2	TP	11×7, 4.5×3	PR	2/17	Negative	RT	Vulvar+liver	5	9	DOD
10	77	-	T3N2/IVA	2	TP	3.5×2, 4×2.5	PD	--	-	-	Liver	2	5	DOD

AF, atrial fibrillation; CHT, chemotherapy; CR, complete response; DM, diabetes mellitus; DOD, dead of disease; DVT, deep vein thrombosis; FIGO, International Federation of Gynecology and Obstetrics; MI, myocardial infarction; NACT, neoadjuvant chemotherapy; NED, no evidence of disease; N+/N total, number of positive nodes over number of total removed nodes; OS, overall survival; PD, progressive disease; PFS, progression free survival; pN, pathological nodes; PR, partial response; RT, radiotherapy; SD, stable disease; TIP, paclitaxel-ifosfamide-cisplatin; TNM, tumor node metastasis; TP, paclitaxel-cisplatin; UC, ulcerative colitis.

during chemoradiation treatment and died of the disease 2 months later. Overall, 9 patients underwent radical surgery (8 radical local excision and 1 radical partial vulvectomy) with bilateral inguino-femoral lymphadenectomy after NACT. Pelvic lymphadenectomy was performed in 1 patient because of the observation of suspected iliac node metastasis on CT scans; however, the node was pathologically negative for malignancy.

Pathological responses included 1 case with CR, 2 with persistent carcinoma *in situ*, and 6 invasive cancer cases with tumor shrinkage of more than 50% from the initial diagnosis. Negative margins were achieved in 6 out of 9 patients (67%). Four patients had positive nodes. Five received adjuvant post-operative treatment, including 4 with radiation therapy, and 1 with 3 additional courses of TIP, due to positive resection margins. One patient with a positive anal margin refused any further treatment. Chemotherapy-related toxicities included grade 3–4 neutropenia (40%), particularly in patients receiving TIP, which was managed with granulocyte colony-stimulating factor (G-CSF), grade 2 alopecia (100%), and neurologic toxicity (10%) requiring paclitaxel dose reduction (Table 2).

After surgery, 1 patient experienced grade 2 partial vulvar wound dehiscence, and 1 had grade 1 vulvar incisional separation. Neither of them required surgical reintervention. Seven out of 9 operated patients had disease recurrence, with a median progression-free survival (PFS) from surgery of 14 months (range, 5–44 months), whereas 1 patient was diagnosed with a second neoplasia (recto-anal) 46 months after surgery. All recurrences but one were local. Three of them were treated with salvage surgery, whereas the other 3 received radiation therapy with or without chemotherapy.

Table 2. Grade of NACT toxicities according to the National Cancer Institute Common Toxicity Criteria ver. 2.0 [23]

Patient no.	NACT scheme	Neutropenia	Neurologic toxicity	Anemia	Alopecia
1	TIP	4	-	-	2
2	TIP	4	-	-	2
3	TP	3	2	-	2
4	TIP	4	-	-	2
5	TP	-	3	-	2
6	TP	-	-	-	2
7	TIP	-	-	-	2
8	TP	-	-	-	2
9	TP	-	-	-	2
10	TP	-	-	1	2

NACT, neoadjuvant chemotherapy; TIP, paclitaxel-ifosfamide-cisplatin; TP, paclitaxel-cisplatin.



All long-term toxicities were of mild intensity (grade 1), including 1 lymphocyst in the patient who underwent pelvic lymphadenectomy, and 2 cases of lymphedema in the lower extremities. During a median follow-up period of 40 months (range, 5–112 months), 4 patients died of PD. To date, 1 woman survives with active recto-anal carcinoma, and 5 are alive without any evidence of disease.

## DISCUSSION

Advanced vulvar cancer patients treated with NACT were able to undergo a less destructive surgery, suggesting that NACT was a promising therapeutic option with an improved quality of life. Although the enrolled patients achieved very good responses, the therapy-related mortality rate of this study still ranged from 5% to 13%.

In 2006, a Cochrane meta-analysis [24] showed that patients with inoperable primary tumors or lymph node metastases could benefit from chemoradiation if followed by surgery as chemoradiotherapy reduced the tumor size and thus improved operability. Wound breakdown, infection, necrosis, lymphedema, lymphorrhea, and lymphocele were very common side effects of such combinatorial treatment. In 4 previous studies, operability was achieved in 63 to 92% of cases with 5-fluorouracil and cisplatin or 5-fluorouracil and mitomycin C. In contrast, only 20% of the patients receiving bleomycin were operable after chemoradiation. After a follow-up period of 5 to 125 months, 26% to 63% of participants were alive and well. However, significant complications were observed with such treatment. A total of 27% to 85% of participants died due to treatment related causes or disease. Previous experience at our institution [12] also confirmed these results when Lupi et al. evaluated the efficacy of concurrent chemoradiation followed by surgery in 31 patients with locally advanced vulvar cancer. Chemotherapy with 2 courses of mitomycin C and 5-fluorouracil and concomitant radiotherapy (44 Gy) to the vulva and inguinal-pelvic lymph nodes resulted in objective responses in 22 of 24 primary cases (91.6%), and 7 of 7 recurrent cases (100%). Five of 9 patients (55%) with biopsy-proven inguinal lymph node metastases showed no residual groin disease in the surgical specimens. However, postoperative morbidity rate was quite high at 65% (19 of 29 patients), and mortality rate was 13.8% (4 of 29 patients). The high incidence of necrosis and surgical wound breakdown could be attributed to the microvascularization impairment resulting from radiotherapy, which was subsequently worsened by the surgical procedure. The recurrence rate in that study was 31.8%, and the median follow-up time was 34 months.

More recently, Moore et al. [25] studied 58 patients with locally advanced vulvar cancer treated with chemoradiation (weekly cisplatin plus 57.6 Gy of radiation) to determine the pathologic CR rate. A clinical CR was obtained in 64% of cases with a pathologic CR in 50%. However 18 out of 58 of patients (31%) did not completed the planned treatment, primarily due to treatment related toxicities (9 patients). One treatment related death was reported. After a median follow-up period of 25 months, 31 women (53%) were alive with no evidence of disease. Surgical treatment was not standardized. No data were reported on surgery-related complications after chemoradiation or long-term sequelae of radiation therapy. The authors concluded with a caution in treating elderly women, owing to radiation related complications, and advocated the inclusion of quality of life criteria in future trials.

Since 1990 [26], NACT in advanced vulvar cancer has been investigated in several studies, using different chemotherapy regimens to avoid aggressive and mutilating surgery in patients often of an old age and with several comorbidities. Additionally, since the 1980s, several cisplatin-containing regimens have been considered effective in advanced or recurrent squamous cell carcinomas, and have demonstrated promising results when administered as the neoadjuvant chemotherapy in locally advanced epidermoid head and neck or cervical cancer. Benedetti-Panici et al. [27] conducted a study in which 21 patients with advanced squamous cell carcinoma of the vulva (FIGO stage IVA) received 2 or 3 cycles of cisplatin, bleomycin, and methotrexate (PBM) followed by radical surgery in operable patients. Two patients (10%) had a PR in the T, and 14 patients (67%) had a complete or PR in the inguinal N. The operability rate following NACT was 90% with a pathologic downstaging rate of 33%, but surgical procedures remained intensive in 79% of cases. The combination of NACT and radical surgery had an acceptable morbidity, but the therapeutic results were less encouraging than expected, with a 3-year survival of 24%. The authors concluded that NACT with PBM did not seem to add any substantial benefit to surgery alone in this subset of patients with extremely advanced disease. Furthermore, Wagenaar et al. [28] reported on 25 patients with locally advanced vulvar carcinoma, or recurrent disease (after incomplete resection) who received NACT with bleomycin, methotrexate, and lomustine (BMC) followed by radical surgery. Two CR cases and 12 PR cases were observed, resulting in a response rate of 56%. The BMC regimen was associated with major hematological side effects and mild signs of bleomycin-related pulmonary toxicity. At a median follow-up period of 8 months, 3 patients were alive, whereas 18 patients died due to malignant disease, 2 due to toxicity, and 2 due to other diseases and unknown causes.

The median PFS was 4.8 months, and the median survival was 7.8 months. The 1-year survival rate was 32%. More recently, the Indiananths. The 1-yeconfirmed the efficacy of cisplatin with or without 5- fluorouracil as preoperative treatment in advanced disease [29], reporting a 90% response rate in 14 cases with long-term survivors in the combination arm (mean, 79 months).

*In vivo* use of paclitaxel administered weekly or every three weeks in vulvar cancer has been published in two previous studies [30,31]. The response rate varied from 14% to 83% in an NACT setting. As exciting results have been obtained with the use of paclitaxel-cisplatin in other locally advanced squamous cancers, such as head and neck and cervix, researchers were motivated to test the regimen in vulvar cancer, in order to limit radiotherapy to only cases with a valid requirement for local control. Recently published data by Aragona et al. [32] reported a 83% PR rate in 12 naive locally advanced vulvar cancer patients.

The TIP and TP schedules tested in cervical cancer and used in this study were also feasible in older patients. The results obtained in our investigation were relatively more positive than previous reports in the literature. In our study, 89% of cases became resectable. All but one T3 operated lesions achieved free margins without any stoma creation; even in cases of tumors at less than 1 cm from the anal margin, no stoma was required after NACT plus surgery. Negative margins were achieved in 67% of cases even with only radical local excisions, thus 2/3 of patients were able to avoid an extensive surgical procedure. No extensive reconstructive surgery, besides 2 cases of V-Y flap, was required for vulvar reconstruction. Finally, 45% of patients had clinical responses in nodes. Recurrences occurred in 77% of patients, who were rescued through surgery or radiation therapy. In more details, all 3 patients with positive margins experienced a local recurrence regardless of adjuvant treatment, and 2 out of 3 eventually died of the disease, whereas the remaining 4 patients with recurrence had negative margins at surgery, and 3 out of 4 remain alive to date without disease. Overall, 55.5% of all enrolled patients are alive without disease at 40 months after surgery, with 2 long-term survivors after recurrence (at 9 and 5 years). Bone marrow toxicity related to chemotherapy regimens was manageable with G-CSF, even in elderly patients. Consistent with literature reports and personal experience in advanced cases, we did not register any lethal event and morbidity related to surgery.

The main difference between our results and those recently reported by our Belgian colleagues [33] using a twice weekly carboplatin-paclitaxel regimen could be explained by the intensity of treatment schedules and the distinct role of

platinum compounds in squamous cancer. Carboplatin seems to be less active than cisplatin in different schedules in head and neck carcinoma [34], and its combined use with paclitaxel in cervical cancer is still under investigation [35]. Undoubtedly, we experienced a high rate (77%) of local recurrences, even in patients with negative margins, but we also reported a high percentage of surviving patients (55%) with no evidence of disease at a median of 40 months after surgery. Whether chemoradiotherapy is superior in local control remains unknown. The presence of positive margins after NACT and surgery seems detrimental. Therefore, further studies are necessary to evaluate which patient subset would benefit more from a less toxic treatment like NACT plus surgery versus chemoradiotherapy, while considering the quality of life aspects.

In conclusions, the results obtained in our study confirmed that NACT followed by a less aggressive surgery should be considered as a treatment option for locally advanced vulvar cancer.

## CONFLICT OF INTEREST

No potential conflict of interest relevant to this article was reported.

## REFERENCES

1. Jemal A, Siegel R, Ward E, Murray T, Xu J, Smigal C, et al. Cancer statistics, 2006. *CA Cancer J Clin* 2006;56:106-30.
2. Sturgeon SR, Brinton LA, Devesa SS, Kurman RJ. In situ and invasive vulvar cancer incidence trends (1973 to 1987). *Am J Obstet Gynecol* 1992;166:1482-5.
3. Beller U, Sideri M, Maisonneuve P, Benedet JL, Heintz AP, Ngan HY, et al. Carcinoma of the vulva. *J Epidemiol Biostat* 2001;6:155-73.
4. van der Velden J, van Lindert AC, Gimbrere CH, Oosting H, Heintz AP. Epidemiologic data on vulvar cancer: comparison of hospital with population-based data. *Gynecol Oncol* 1996;62:379-83.
5. Judson PL, Habermann EB, Baxter NN, Durham SB, Virnig BA. Trends in the incidence of invasive and in situ vulvar carcinoma. *Obstet Gynecol* 2006;107:1018-22.
6. Podratz KC, Symmonds RE, Taylor WF. Carcinoma of the vulva: analysis of treatment failures. *Am J Obstet Gynecol* 1982;143:340-51.
7. Beller U, Quinn MA, Benedet JL, Creasman WT, Ngan HY, Maisonneuve P, et al. Carcinoma of the vulva. FIGO 26th Annual Report on the Results of Treatment in Gynecological Cancer. *Int J Gynaecol Obstet* 2006;95 Suppl 1:S7-27.
8. Phillips B, Buchsbaum HJ, Lifshitz S. Pelvic exenteration for vulvovaginal carcinoma. *Am J Obstet Gynecol* 1981;141:1038-44.

9. Cavanagh D, Shepherd JH. The place of pelvic exenteration in the primary management of advanced carcinoma of the vulva. *Gynecol Oncol* 1982;13:318-22.
10. Eifel PJ, Berek JS, Thigpen JT. Carcinoma of the vulva. In: De Vita VT Jr, Hellman S, Rosenberg SA, editors. *Cancer principles and practice of oncology*. New York: Lippincott-Raven; 1997. p. 1462-9.
11. de Hullu JA, Oonk MH, van der Zee AG. Modern management of vulvar cancer. *Curr Opin Obstet Gynecol* 2004;16:65-72.
12. Shylasree TS, Bryant A, Howells RE. Chemoradiation for advanced primary vulval cancer. *Cochrane Database Syst Rev* 2011;(4):CD003752.
13. Lupi G, Raspagliesi F, Zucali R, Fontanelli R, Paladini D, Kenda R, et al. Combined preoperative chemoradiotherapy followed by radical surgery in locally advanced vulvar carcinoma: a pilot study. *Cancer* 1996;77:1472-8.
14. Landoni F, Maneo A, Zanetta G, Colombo A, Nava S, Placa F, et al. Concurrent preoperative chemotherapy with 5-fluorouracil and mitomycin C and radiotherapy (FUMIR) followed by limited surgery in locally advanced and recurrent vulvar carcinoma. *Gynecol Oncol* 1996;61:321-7.
15. Maneo A, Landoni F, Colombo A, Colombo A, Villa A, Caspani G. Randomised study between neoadjuvant chemoradiotherapy and primary surgery for the treatment of advanced vulval cancer [abstract]. *Int J Gynecol Cancer* 2003;13(Suppl 1):6.
16. Zanetta G, Lissoni A, Pellegrino A, Sessa C, Colombo N, Gueli-Alletti D, et al. Neoadjuvant chemotherapy with cisplatin, ifosfamide and paclitaxel for locally advanced squamous-cell cervical cancer. *Ann Oncol* 1998;9:977-80.
17. Dimopoulos MA, Papadimitriou CA, Sarris K, Aravantinos G, Kalofonos C, Gika D, et al. Combination of ifosfamide, paclitaxel, and cisplatin for the treatment of metastatic and recurrent carcinoma of the uterine cervix: a phase II study of the Hellenic Cooperative Oncology Group. *Gynecol Oncol* 2002;85:476-82.
18. Zanetta G, Fei F, Mangioni C. Chemotherapy with paclitaxel, ifosfamide, and cisplatin for the treatment of squamous cell cervical cancer: the experience of Monza. *Semin Oncol* 2000;27(1 Suppl 1):23-7.
19. Buda A, Fossati R, Colombo N, Fei F, Floriani I, Gueli Alletti D, et al. Randomized trial of neoadjuvant chemotherapy comparing paclitaxel, ifosfamide, and cisplatin with ifosfamide and cisplatin followed by radical surgery in patients with locally advanced squamous cell cervical carcinoma: the SNAP01 (Studio Neo-Adjuvante Portio) Italian Collaborative Study. *J Clin Oncol* 2005;23:4137-45.
20. Lissoni AA, Colombo N, Pellegrino A, Parma G, Zola P, Katsaros D, et al. A phase II, randomized trial of neo-adjuvant chemotherapy comparing a three-drug combination of paclitaxel, ifosfamide, and cisplatin (TIP) versus paclitaxel and cisplatin (TP) followed by radical surgery in patients with locally advanced squamous cell cervical carcinoma: the Snap-02 Italian Collaborative Study. *Ann Oncol* 2009;20:660-5.
21. Therasse P, Arbuck SG, Eisenhauer EA, Wanders J, Kaplan RS, Rubinstein L, et al. New guidelines to evaluate the response to treatment in solid tumors: European Organization for Research and Treatment of Cancer, National Cancer Institute of the United States, National Cancer Institute of Canada. *J Natl Cancer Inst* 2000;92:205-16.
22. Raspagliesi F, Hanozet F, Ditto A, Solima E, Zanaboni F, Vecchione F, et al. Clinical and pathological prognostic factors in squamous cell carcinoma of the vulva. *Gynecol Oncol* 2006;102:333-7.
23. National Cancer Institute, Division of Cancer Treatment and Diagnosis. Common Toxicity Criteria (CTC) ver. 2.0 [Internet]. Bethesda, MD: National Cancer Institute; 1999 [cited 2013 Nov 20]. Available from: [http://ctep.cancer.gov/protocolDevelopment/electronic\\_applications/docs/ctcv20\\_4-30-992.pdf](http://ctep.cancer.gov/protocolDevelopment/electronic_applications/docs/ctcv20_4-30-992.pdf).
24. van Doorn HC, Ansink A, Verhaar-Langereis M, Stalpers L. Neo-adjuvant chemoradiation for advanced primary vulvar cancer. *Cochrane Database Syst Rev* 2006;(3):CD003752.
25. Moore DH, Ali S, Koh WJ, Michael H, Barnes MN, McCourt CK, et al. A phase II trial of radiation therapy and weekly cisplatin chemotherapy for the treatment of locally-advanced squamous cell carcinoma of the vulva: a gynecologic oncology group study. *Gynecol Oncol* 2012;124:529-33.
26. Shimizu Y, Hasumi K, Masubuchi K. Effective chemotherapy consisting of bleomycin, vincristine, mitomycin C, and cisplatin (BOMP) for a patient with inoperable vulvar cancer. *Gynecol Oncol* 1990;36:423-7.
27. Benedetti-Panici P, Greggi S, Scambia G, Salerno G, Mancuso S. Cisplatin (P), bleomycin (B), and methotrexate (M) preoperative chemotherapy in locally advanced vulvar carcinoma. *Gynecol Oncol* 1993;50:49-53.
28. Wagenaar HC, Colombo N, Vergote I, Hocht-Boes G, Zanetta G, Pecorelli S, et al. Bleomycin, methotrexate, and CCNU in locally advanced or recurrent, inoperable, squamous-cell carcinoma of the vulva: an EORTC Gynaecological Cancer Cooperative Group Study. *European Organization for Research and Treatment of Cancer. Gynecol Oncol* 2001;81:348-54.
29. Geisler JP, Manahan KJ, Buller RE. Neoadjuvant chemotherapy in vulvar cancer: avoiding primary exenteration. *Gynecol Oncol* 2006;100:53-7.
30. Witteveen PO, van der Velden J, Vergote I, Guerra C, Scarabelli C, Coens C, et al. Phase II study on paclitaxel in patients with recurrent, metastatic or locally advanced vulvar cancer not amenable to surgery or radiotherapy: a study of the EORTC-GCG (European Organisation for Research and Treatment of Cancer--Gynaecological Cancer Group). *Ann Oncol* 2009;20:1511-6.
31. Domingues AP, Mota F, Durao M, Frutuoso C, Amaral N, de Oliveira CF. Neoadjuvant chemotherapy in advanced vulvar cancer. *Int J Gynecol Cancer* 2010;20:294-8.
32. Aragona AM, Cuneo N, Soderini AH, Alcoba E, Greco A, Reyes C, et al. Tailoring the treatment of locally advanced squamous cell carcinoma of the vulva: neoadjuvant chemotherapy followed by radical surgery: results from a multicenter study. *Int J Gynecol Cancer* 2012;22:1258-63.
33. Han SN, Vergote I, Amant F. Weekly paclitaxel/carboplatin in the treatment of locally advanced, recurrent, or metastatic vulvar

- cancer. *Int J Gynecol Cancer* 2012;22:865-8.
34. De Andres L, Brunet J, Lopez-Pousa A, Burgues J, Vega M, Tabernero JM, et al. Randomized trial of neoadjuvant cisplatin and fluorouracil versus carboplatin and fluorouracil in patients with stage IV-M0 head and neck cancer. *J Clin Oncol* 1995;13:1493-500.
  35. Saito I, Kitagawa R, Fukuda H, Shibata T, Katsumata N, Konishi I, et al. A phase III trial of paclitaxel plus carboplatin versus paclitaxel plus cisplatin in stage IVB, persistent or recurrent cervical cancer: Gynecologic Cancer Study Group/Japan Clinical Oncology Group Study (JCOG0505). *Jpn J Clin Oncol* 2010;40:90-3.

### Standards for Different Types of Articles

Guidelines for different types of articles have been adopted by the *Journal of Gynecologic Oncology*:

1. **CONSORT** (Consolidated Standards of Reporting Trials) standards for reporting randomized trials
2. **PRISMA** (Preferred Reporting Items for Systematic Reviews and Meta-analyses) guidelines for reporting systematic reviews and meta-analyses
3. **MOOSE** (Meta-analysis of Observational Studies in Epidemiology) guidelines for meta-analyses and systematic reviews of observational studies
4. **STROBE** (Strengthening the Reporting of Observational Studies in Epidemiology) guidelines for the reporting of observational studies
5. **STARD** (Standards for Reporting of Diagnostic Accuracy) standards for reporting studies of diagnostic accuracy
6. **REMARK** (Reporting of Tumor Markers Studies) guidelines for reporting tumor marker prognostic studies
7. **SQUIRE** (Standards for Quality Improvement Reporting Excellence) guidelines for quality improvement in health care
8. **CHEERS** (Consolidated Health Economic Evaluation Reporting Standards) statement for economic evaluations of health interventions
9. **COREQ** (Consolidated criteria for Reporting Qualitative research) for qualitative research interviews and focus groups
10. **SAMPL** (Statistical Analyses and Methods in the Published Literature) guidelines for basic statistical reporting for articles published in biomedical journals

Investigators who are planning, conducting, or reporting randomized trials, meta-analyses of randomized trials, meta-analyses of observational studies, observational studies, studies of diagnostic accuracy, or tumor marker prognostic studies should be familiar with these sets of standards and follow these guidelines in articles submitted for publication.

**NOW AVAILABLE ONLINE** at <http://www.ejgo.org>