

# Diagnosis of a Trocar Site Mass as Omental Herniation after Laparoscopic Gastrectomy

Sang-Ho Jeong<sup>1,4</sup>, Young-Joon Lee<sup>1,4</sup>, Dong Chool Kim<sup>2,4</sup>, Kyungsoo Bae<sup>3,4</sup>, Sang-Kyung Choi<sup>1,4</sup>, Soon-Chan Hong<sup>1,4</sup>, Eun-Jung Jung<sup>1,4</sup>, Young-Tae Ju<sup>1,4</sup>, Chi-Young Jeong<sup>1,4</sup>, and Woo-Song Ha<sup>1,4</sup>

Departments of <sup>1</sup>Surgery, <sup>2</sup>Pathology, <sup>3</sup>Diagnostic Radiology, <sup>4</sup>Institute of Health Sciences, Gyeongsang National University School of Medicine, Jinju, Korea

A trocar site hernia is a rare complication. We report a patient who had an abdominal wall mass at a previous trocar site after laparoscopic distal gastrectomy. It was diagnosed as omental herniation and fat necrosis. We conclude that patients with trocar site masses exhibiting fat density on a computed tomography scan could be followed up without surgery, and that fascial defects located at 10-mm or larger trocar sites should be closed whenever possible to prevent hernia formation.

**Key Words:** Omentum; Hernia; Trocar; Gastric neoplasms; Laparoscopy

## Introduction

The incidence of trocar site hernia is reported to be 0.11~0.84% after laparoscopic cholecystectomy.(1,2) Fear(3) first reported a trocar site hernia in his large series on laparoscopic surgery. Maio and Ruchman(4) reported a trocar site hernia with small-bowel obstruction immediately after cholecystectomy; this was the first report of a trocar site hernia in digestive surgery. Since then many reports have been published on cholecystectomy, and more recently on gastrointestinal surgery.

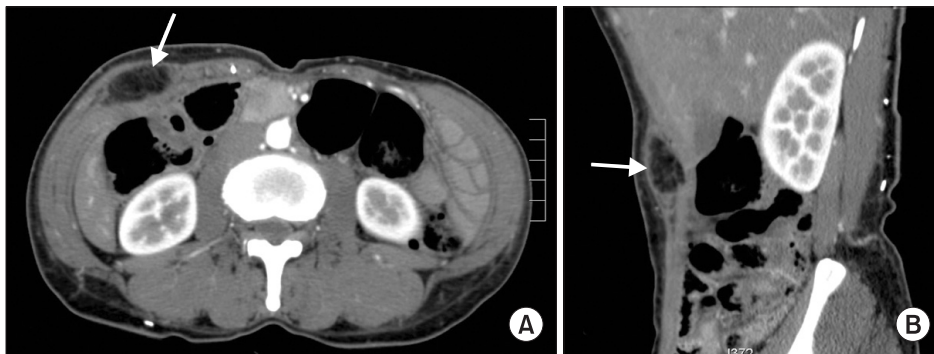
We report a patient who had an abdominal wall mass at a previous trocar site after laparoscopic distal gastrectomy. It was diagnosed as omental herniation and fat necrosis.

## Case Report

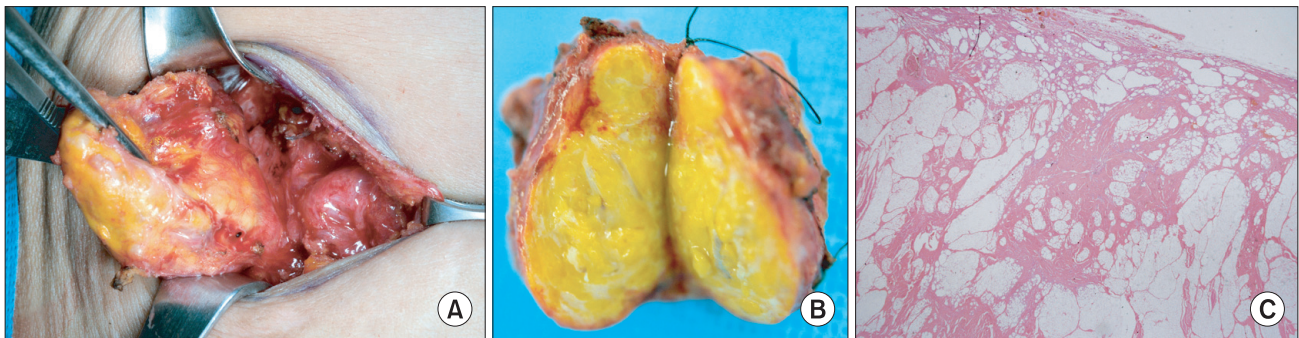
A 50 year-old women visited the hospital after a mass was detected in her right flank area. Six months previously she had undergone laparoscopic-assisted subtotal gastrectomy for an early gastric cancer located in her gastric antrum. We repaired the fascia at the troca sites of more than 10 mm. The patient was discharged on the 9th postoperative days without any complications. Her pathologic stage was T3N1 (2/18)M0 Stage IIB (TNM 7th edition). We found a 4.5×3.5 cm mass at the previous right lower 12 mm trocar site on computed tomography (CT) scan. The mass showed fat density on the CT scan and it was located between the external and the internal oblique muscle of the abdominal wall (Fig. 1). She perceived the mass, but it had not herniated. We found the mass was firm and movable on physical examination.

We decided to perform an excisional biopsy to exclude trocar site metastasis. The post-operative findings showed that the mass was located between the external oblique muscle and the internal oblique muscle and that it was oval shaped with a size of 4.5×3.3 cm (Fig. 2A). We divided the yellow mass that contained the central whitish lesion (Fig. 2B). No tumor cells were found in the frozen biopsy. We found the previous fascia of the trocar site had opened

Correspondence to: Young-Joon Lee  
Department of Surgery, Gyeongsang National University Hospital, 90, Chilam-dong, Jinju 660-702, Korea  
Tel: +82-55-750-8615, Fax: +82-55-757-5442  
E-mail: yjleegnu@gmail.com  
Received January 14, 2012  
Revised March 6, 2012  
Accepted March 7, 2012



**Fig. 1.** The fatty abdominal mass (arrow) between the external and the internal oblique muscle of the abdominal wall. (A) Transverse view and (B) sagittal view.



**Fig. 2.** (A) Intraoperative view; the mass was oval shaped and measured 4.5×3.3 cm. (B) Divided the yellow mass. (C) Pathology report showing fat necrosis (H&E, ×40).

under the mass. We repaired the fascia and wound. The patient was discharged three days after the operation. The pathology reports showed fat necrosis (Fig. 2C).

## Discussion

Although the incidence of gastric cancer and the mortality associated with this disease have decreased gradually in East Asia, it remains the second most frequent cause of death in Korea. Recently, the inclusion criteria for laparoscopic assisted gastrectomy have been enlarged, which has led to an increase in the number of publications describing laparoscopic treatment of advanced gastric cancer.(5,6)

We previously reported trocar site recurrence after laparoscopic gastrectomy in advanced gastric cancer patients.(7) So, when a mass at a trocar site is uncovered, it is worth considering trocar site recurrence after a previous cancer operation. However, the density of the mass on the CT scan in the present case corresponded to fat density, and the mass was located between the external oblique and the internal oblique muscle. The possibility of lipoma was low, so we decided to operate. After the operation, the pathology report showed fat necrosis. We concluded the mass had herniated from the abdominal omentum, because it was located between the ex-

ternal and the internal muscle, and the fascia of the internal oblique and the transversalis muscle had defects.

Most trocar-site hernias involve trocars of at least 10 mm, but a few cases of not only 5 mm trocars but also 3-mm trocars have been reported.(8,9) In the survey of the American Association of Gynecologic Laparoscopists,(10) of 840 trocar site hernias, 725 (86.3%) occurred in sites where the diameter was at least 10 mm. Only 92 hernias (10.9%) occurred at the site of insertion of trocars with a diameter of more than 8 mm but less than 10 mm, with 23 (2.7%) occurring in sites where the trocars were smaller than 8 mm (They estimated that 41.3% of all trocars were at least 10 mm.). Helgstrand et al.(11) reported that meta-analysis prevents trocar site herniations. The risk of a trocar site hernia is no different than a Veress needle, open access or blunt and cutting trocars. A slowly absorbable or non-absorbable suture is recommended for the prevention of hernias. The fascia should be sutured in all trocar sites  $\geq 10$  mm, but all port sites should be sutured regardless of trocar size in children (age < 6 years). Diabetes and smoking are possible risk factors, but not obesity.

We conclude that patients with trocar site masses exhibiting fat density on a CT scan could be followed up without surgery, and that fascial defects located at 10-mm or larger trocar sites should be closed whenever possible to prevent hernia formation.

## References

1. Ahmad SA, Schuricht AL, Azurin DJ, Arroyo LR, Paskin DL, Bar AH, et al. Complications of laparoscopic cholecystectomy: the experience of a university-affiliated teaching hospital. *J Laparoendosc Adv Surg Tech A* 1997;7:29-35.
2. Baird DR, Wilson JP, Mason EM, Duncan TD, Evans JS, Luke JP, et al. An early review of 800 laparoscopic cholecystectomies at a university-affiliated community teaching hospital. *Am Surg* 1992;58:206-210.
3. Fear RE. Laparoscopy: a valuable aid in gynecologic diagnosis. *Obstet Gynecol* 1968;31:297-309.
4. Maio A, Ruchman RB. CT diagnosis of postlaparoscopic hernia. *J Comput Assist Tomogr* 1991;15:1054-1055.
5. Jeong SH, Lee YJ, Park ST, Choi SK, Hong SC, Jung EJ, et al. Risk of recurrence after laparoscopy-assisted radical gastrectomy for gastric cancer performed by a single surgeon. *Surg Endosc* 2011;25:872-878.
6. Hwang SI, Kim HO, Yoo CH, Shin JH, Son BH. Laparoscopic-assisted distal gastrectomy versus open distal gastrectomy for advanced gastric cancer. *Surg Endosc* 2009;23:1252-1258.
7. Lee YJ, Ha WS, Park ST, Choi SK, Hong SC. Port-site recurrence after laparoscopy-assisted gastrectomy: report of the first case. *J Laparoendosc Adv Surg Tech A* 2007;17:455-457.
8. Bergemann JL, Hibbert ML, Harkins G, Narvaez J, Asato A. Omental herniation through a 3-mm umbilical trocar site: unmasking a hidden umbilical hernia. *J Laparoendosc Adv Surg Tech A* 2001;11:171-173.
9. Bloom DA, Ehrlich RM. Omental evisceration through small laparoscopy port sites. *J Endourol* 1993;7:31-32.
10. Montz FJ, Holschneider CH, Munro MG. Incisional hernia following laparoscopy: a survey of the American Association of Gynecologic Laparoscopists. *Obstet Gynecol* 1994;84:881-884.
11. Helgstrand F, Rosenberg J, Bisgaard T. Trocar site hernia after laparoscopic surgery: a qualitative systematic review. *Hernia* 2011;15:113-121.