

Review Article



Intraoperative Neural Monitoring in Thyroid Surgery: Role and Responsibility of Surgeon

Hoon Yub Kim ¹, Ralph P. Tufano², Young Jun Chai ³, Marcin Barczynski⁴, Özer Makay⁵, Che-Wei Wu ⁶, Eren Berber⁷, Hui Sun ⁸, Gianlorenzo Dionigi ⁹, the Korean Intraoperative Neural Monitoring Society (KINMoS)

¹KUMC Thyroid Center, Korea University Anam Hospital, Seoul, Korea

²Department of Otolaryngology-Head and Neck Surgery, The Johns Hopkins University School of Medicine, Baltimore, MD, USA

³Department of Surgery, Seoul Metropolitan Government-Seoul National University Boramae Medical Center, Seoul, Korea

⁴Department of Endocrine Surgery, 3rd Chair of General Surgery, Jagiellonian University College of Medicine, Kraków, Poland

⁵Division of Endocrine Surgery, Department of General Surgery, Ege University Hospital, İzmir, Turkey

⁶Department of Otolaryngology-Head and Neck Surgery, Kaohsiung Medical University, Kaohsiung, Taiwan

⁷Department of Endocrine Surgery, Cleveland Clinic, Cleveland, OH, USA

⁸Division of Thyroid Surgery, Jilin Provincial Key Laboratory of Surgical Translational Medicine, China-Japan Union Hospital of Jilin University, Changchun, China

⁹Division of Endocrine and Minimally Invasive Surgery, Department of Human Pathology in Adulthood and Childhood "G. Barresi", University Hospital G. Martino, University of Messina, Messina, Italy

OPEN ACCESS

Received: Dec 15, 2017

Accepted: Jan 7, 2018

Correspondence to

Hui Sun

Division of Thyroid Surgery, Jilin Provincial Key Laboratory of Surgical Translational Medicine, China-Japan Union Hospital of Jilin University, 126 Xiantai St., Erdao Qu, Changchun 130033, China.

E-mail: thyroidjl@163.com

Gianlorenzo Dionigi

Division for Endocrine and Minimally Invasive Surgery, Department of Human Pathology in Adulthood and Childhood "G. Barresi", University Hospital G. Martino, University of Messina, Via C. Valeria 1, Messina 98125, Italy. E-mail: gdionigi@unime.it

Copyright © 2018. Korean Association of Thyroid and Endocrine Surgeons; KATES. This is an Open Access article distributed under the terms of the Creative Commons Attribution Non-Commercial License (<https://creativecommons.org/licenses/by-nc/4.0/>).

ORCID iDs

Hoon Yub Kim

<https://orcid.org/0000-0002-6731-3912>

Young Jun Chai

<https://orcid.org/0000-0001-8830-3433>

Che-Wei Wu

<https://orcid.org/0000-0003-1052-5348>

Hui Sun

<https://orcid.org/0000-0002-6492-3459>

Gianlorenzo Dionigi

<https://orcid.org/0000-0003-0864-6087>

ABSTRACT

Surgeons who introduce intraoperative neural monitoring (IONM) or a new IONM accessory, or related procedure in their practice should have completed relevant surgical training, possess operating privileges in the affected endocrine system, and be able to address anticipated complications. Surgeon responsibility in monitoring is dual component. First, technical component is using and setting up the IONM equipment correctly and understanding the inherent properties of the system to avoid an erroneous setup (e.g., no muscle relaxation, correct electrode placement, low impedance, etc.). Second, interpretive component is performing the monitoring able to distinguish between a true response versus an artifactual one. Organizations such as the International Neural Study Group and the Korean Intraoperative Neural Monitoring Society provide training courses for surgeon, as well as a means to certify levels of monitoring interpretative competence.

Keywords: Neural monitoring; Thyroid surgery; Recurrent laryngeal nerve; Training

INTRODUCTION

Thyroid surgery is increasing in United States, Asia, and Europe (1-6). Thyroid operations in some European countries are ranked third in the intervention statistics of general surgical conditions after cholecystectomy and inguinal hernia repair (5,6). The leading indication for surgery continues to be the bilateral multinodular goiter in Europe while, cancer is more frequent in USA and Asia (1-6).

Author Contributions

Conceptualization: Hoon Yub Kim, Che-Wei Wu, Hui Sun, Gianlorenzo Dionigi; Data curation: Gianlorenzo Dionigi; Formal analysis: Gianlorenzo Dionigi; Investigation: Gianlorenzo Dionigi; Project administration: Özer Makay; Writing - original draft: Hoon Yub Kim, Ralph P; Tufano, Young Jun Chai, Marcin Barczynski, Özer Makay, Che-Wei Wu, Eren Berber, Hui Sun, Gianlorenzo Dionigi; Writing - review & editing: Hoon Yub Kim, Ralph P; Tufano, Young Jun Chai, Marcin Barczynski, Özer Makay, Che-Wei Wu, Eren Berber, Hui Sun, Gianlorenzo Dionigi.

Conflict of Interest

No potential conflict of interest relevant to this article was reported.

In recent years, an increase in more radical resections has been observed over previously favored thyroid remnant surgery both for benign and malignant conditions (7). The rationale for this is to avoid nodular recurrence and to ensure sufficient radicality in incidental carcinomas (7). In addition to hypoparathyroidism, paralysis of the recurrent laryngeal nerve (RLN) is one of the leading complications (8). For the patient, this can have far-reaching consequences with a significant reduction in the quality of life (8).

CLINICAL CONSEQUENCE OF RLN PALSY

The RLN carries sensitive, parasympathetic and motor fibers (8). It innervates almost all laryngeal muscles (with the exception of the cricothyroid muscle) and sensitively the mucous membrane of the larynx below the glottis (9).

Pre- and postoperative laryngeal examination is a gold standard for RLN management, together with surgeon experience, training, routine exposure, and identification of the nerve. The true incidence of postoperative RLN temporary complications appears to be approximately from 3% to 12% (10). The incidence of long-term RLN complications such as permanent morbidity remains unknown. Same, for the incidence of bilateral RLN palsy, temporary or permanent is unknown. These last 2 complications are still the “hidden black numbers” in thyroid surgery in 2018.

Unilateral recurrent paralysis causes the incomplete closure of the vocal cord fold on the affected side. This leads to hoarseness, which has consequences especially for young patients. In addition, there may be shortness of breath during speech due to an uncontrolled escape of air during speech (10).

The risk of tracheotomy with bilateral RLN palsy averages 30% with an additional 21% requiring other acute airway surgeries. Thus overall 50% patients with bilateral RLN palsy require airway intervention (10).

While the one-sided vocal cord palsy improvement in the voice can be achieved through speech therapy, patients with bilateral recurrent paresis in their everyday life are clearly limited and long-term disabled. Measures, such as vocal cord augmentation or various methods of surgical vocal cord medialization, which serve voice enhancement, have been proposed and applied (10).

TYPES OF RLN INJURIES

Avoiding nerve damage requires knowledge of the possible mechanism of injury (**Table 1**). Different possibilities of nerve damage have been described: mechanical lesions through

Table 1. Intraoperative RLN injury causes

| |
|--|
| • Section |
| • Ligature |
| • Mistake in hemostasis and dissection maneuvers |
| • Stretch/traction |
| • Compression/contusion/pressure |
| • Thermal/electrical injury |
| • Ischemia |

RLN = recurrent laryngeal nerve.

pressure or contusion especially in the area of the ligament of Berry, through clips and ligatures near the nerve, by thermal damage (application of electrocoagulation) or rarely by the accidental nerve transection.

Dionigi et al. (11) reported the prevalence of nerve lesions types as traction (71%), thermal from energy based devices (EBDs) (17%), compression (4%), clamping (3%), ligature entrapment (1.5%), suction (1.5%), and nerve transection (1.5%). The severity of thermal injuries was worse than traction injury (11,12). The rates of temporary and permanent RLN injury were 72% and 28% for thermal injury due to EBD (11,12).

RLN SURGICAL ANATOMY

The identification of RLN in thyroid surgery is well established in current guidelines (13). The visualization of the RLN requires the knowledge of the anatomical course and possible position variations.

Figs. 1 and 2 summarize the significant additions of intraoperative neural monitoring (IONM) for RLN surgical anatomy in the last decades.

The different anatomical course of the right and left RLN is due to complex ontogenetic processes during the embryonic period (**Fig. 3**). The right RLN is shorter than the left one. The right RLN intersects the subclavian artery and then extends obliquely from the lateral to the medio-cranial direction. The left-sided RLN initially forms a loop around the aortic arch. The nerve then shows a more vertical-parallel alignment with the tracheal axis in its further course (14).

Up to 30 positional variations between RLN and inferior thyroid artery have been reported, in particular the 3 main variants to note are the retrovascular course, the antevascular course, and the intervascular course (**Fig. 4**). An antevascular course is more frequently observed on the right and a retrovascular more frequently on the left (15).

It should always be noted here that traction forces during thyroid mobilization, especially during antevascular or intervascular courses, can lead to pressure damage in the nerve area. The positional relationship between both anatomical structures may be even more complex

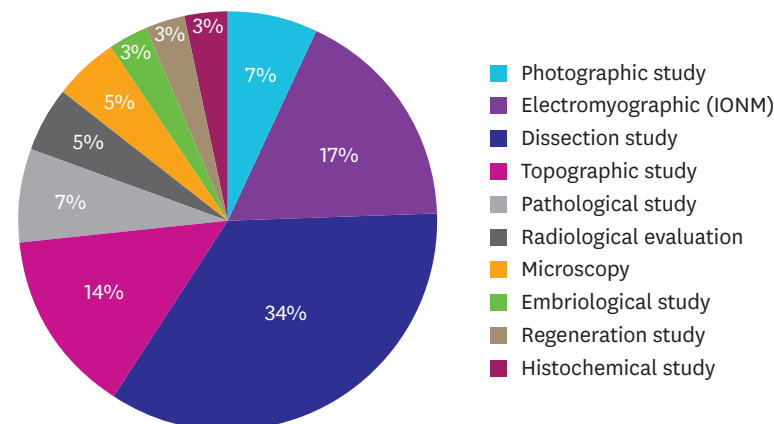


Fig. 1. RLN anatomy studies from 1927 to 2015 (peer-reviewed papers, edited books, abstract meetings) (n=711). RLN = recurrent laryngeal nerve; IONM = intraoperative neural monitoring.

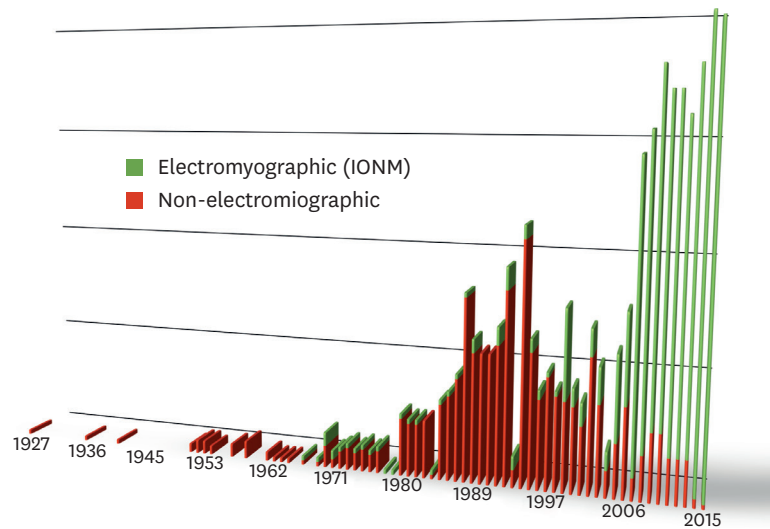


Fig. 2. RLN anatomy studies from 1927 to 2015 (peer-reviewed papers, edited books, abstract meetings) (n=711). RLN = recurrent laryngeal nerve; IONM = intraoperative neural monitoring.

as a result of an extralaryngeal branching (30%–45%) of the nerve. Most of them are 2, more rarely 3 branches of the RLN, which usually divide from the main trunk cranially to the junction with the artery before they enter the larynx (13-15).

The anterior branch carries the fibers with a purely selective motor function, which is

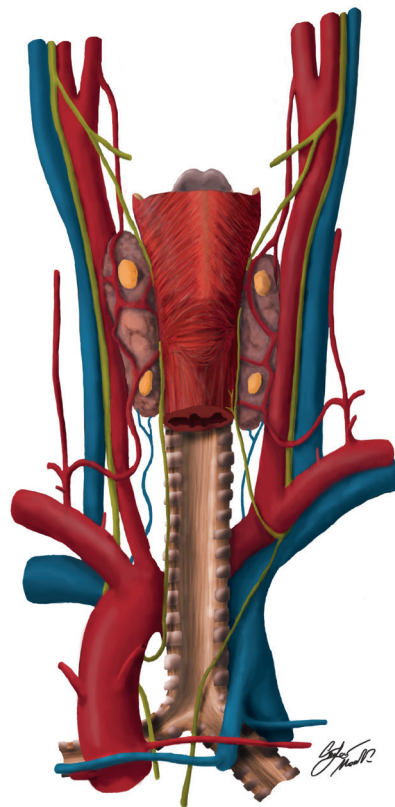


Fig. 3. The different anatomical course of the right and left RLN. RLN = recurrent laryngeal nerve.

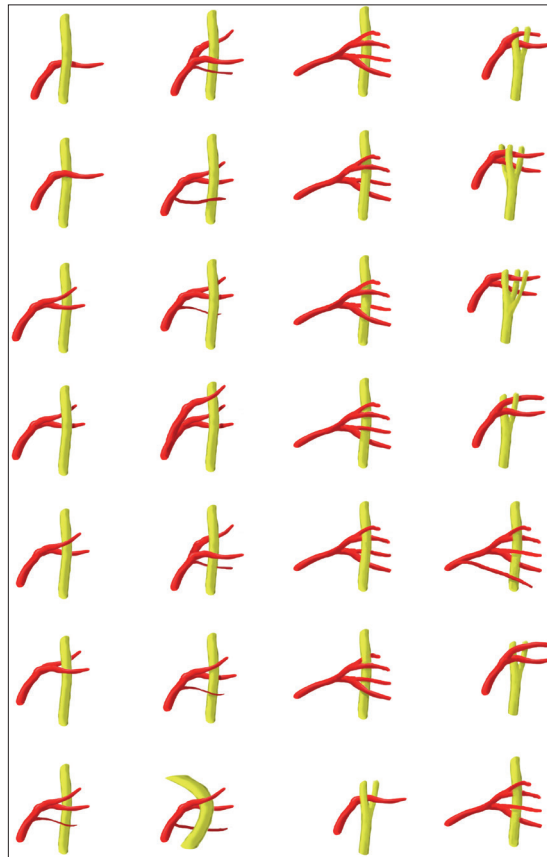


Fig. 4. Up to 30 positional variations between RLN and inferior thyroid artery have been reported, in particular the 3 main variants to note are the retrovascular course, the antevascular course, and the intervascular course. RLN = recurrent laryngeal nerve.

important for the application of the IONM (13). A non-recurrent course of the RLN is found in about 0.6% and is found on embryological grounds almost exclusively on the right side when an arteria lusoria is planted (13).

A Zuckerkandl Tuberculum (posterior thyroid gland) is seen in varying degrees in about 60% (14), more often on the right than on the left. The RLN usually runs posterior to the Zuckerkandl's tuberculum, rarely crosses the tuberculum. In a dorsal course, the nerve is found between the tubercle and trachea. A visualization of the nerve is thus possible only by carefully lifting the tuberculum and shifting it laterally and anteriorly (13).

The RLN is particularly vulnerable to a course embedded in the ligament of Berry. In this area, the nerve is particularly at risk embedded in the ligament (up to 50%) (15). A brusque medialization of the thyroid lead to a direct pressure or tensile damage of the nerve.

Before the nerve enters the larynx, branches to the inferior constrictor muscle and the cricopharyngeal muscle depart. The entry point of the RLN into the larynx is close to the lower thyroid cartilage horn.

The variety of different struma formations (dorsal nodal position, retrosternal position, recurrent goiter) lead to a series of individual displacements of the nerve course.

Inflammatory changes in the dorsal capsule area, also lead to “reversed” boundary layers and potentially altered nerve courses (14). Since the course of the nerve is basically unpredictable from an isolated point of representation, a nerve-conserving preparation usually means the long-stretched, largely exposing and isolating, but not devascularizing representation of the nerve. Here, in addition to a nerve-sparing preparation technique in the representation of the parathyroid glands, attention must be paid to a vascular ligation close to the thyroid gland because otherwise a devascularization of the parathyroid glands is possible.

The inferior thyroid artery and the parathyroid glands, which are also located in the retrothyroid space of the non-preoperated thyroid gland, can serve as orientation points for finding the nerve or assessing its course.

NERVE VISUALIZATION AND NEUROMONITORING

RLN and laryngeal anatomy are the basis of modern thyroid surgery.
So why do we need more than anatomical nerve identification?

Numerous studies have shown that the identification of the RLN is mandatory and a prerequisite for the use of IONM (16). On the one hand, the IONM serves to secure the anatomical structure and the recognition of positional variants, and on the other hand to ensure the function of the nerve. Of particular importance is the avoidance of bilateral RLN paresis (16).

So far, the use of the IONM could show no reduction in the paresis rate compared to the purely visual representation (16). In surgery of carcinoma and thyroid recurrence, however, the use seems to be useful (16). For IONM to be beneficial, 1) it must provide indications of impending neurological damage early enough to permit the surgical team to take appropriate measures to reverse or minimize the damage, 2) it should be easily interpreted, 3) it should be readily available, and 4) it should be cost effective.

IONM is not based on class I evidence, No IONM technique (in neurosurgery, orthopedics, etc.) has class I evidence. IONM in general surgery is limited to class II and III studies. Thus, IONM should be recognized at same level of evidence applied to most our clinical practice within thyroid surgery. Furthermore, the level of evidence and recommendations in IONM is not worse than that found for any other technology in thyroid surgery generally. Finally, unlikely class I studies will ever occur because 1) the likelihood of preventing RLN deficit using IONM, 2) the incidence of permanent RLN complications is low, 3) surgeons and patients will never accept randomization (16).

LARYNGOSCOPY

If IONM is used during surgery, why L1 and L2 still mandatory?

Pre- and postoperative laryngoscopy (L1 and L2) are mandatory for the assessment of IONM prior to surgery, as pre-existing RLN paresis may be associated with normal stimulation electromyography (EMG) (17). L1 is the reference for pre-dissectional stimulation of the vagal nerve (V1) and RLN (R1) (17). Post-operative laryngeal examination is essential as IONM is still in the development phase. L1 and L2 are essential in all cases while intermittent IONM (I-IONM)

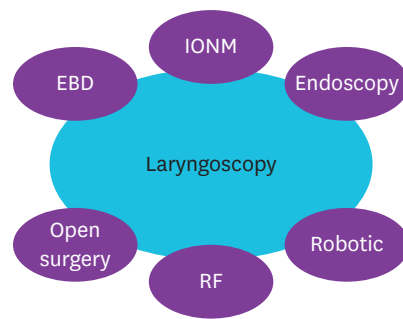


Fig. 5. Postoperative laryngeal examination represent the final asset of safety evaluation.
EBD = energy based device; IONM = intraoperative neural monitoring; RF = radio frequency.

and continuous IONM (C-IONM) are in the development phase to improve the prognostic correlation between neural stimulation and pre- and postoperative glottic function (17).

Intraoperative laryngeal examination is important as a verification tests of EMG tube position, and should be performed after the patient is fully positioned and not when the patient is in the neutral intubation position (17).

As surgical experience grows, operative techniques or technologies (as IONM) designed at reducing RLN risks will mature, strategies for managing complications will advance, and more advanced thyroid procedures designed for cosmetics will become available, at the end, it always ends, on an objective examination of the RLN management and surgeon audit, i.e., the vocal cords which is pre- and postoperative laryngoscopy (**Fig. 5**).

TECHNIQUE FOR IONM

Victor Riddel wrote in 1970 on the *British Journal of Surgery* (18):

“... It is the author inflexible rule never to resect the second lobe in a bilateral procedure until the integrity of the RLN has been proved...”

“... stimulation of the RLN by electrical current will establish its integrity palsy ...”

“.. stimulation will determine if an unidentified strand of tissue is the RLN or not...”

IONM has emerged over the last decades as one of the avenues of progress within surgery in neurosurgery, orthopedics, vascular surgery, plastic surgery, general surgery, otolaryngology (ENT), etc. The idea of applying techniques traditionally used in clinical neurophysiology within thyroid surgery is not novel (18).

The principle of the IONM is the derivation of an EMG of the larynx by stimulation of the RLN and the vagal nerve (VN) and the derivation of a muscle action potential. The non-invasive EMG tube electrodes are used for this purpose (19). At the beginning of the operation, the VN should be stimulated (V1) and a signal deduced before opening thyroid dissection. A signal above 500 mcV must be documented.

High quality IONM is fundamental to make any surgical deliberations, for safety and to reduce false positive. Unequivocal definition of normative V1 mean value >500 mcV is prerequisite for the diagnosis, interpretation, verification of: 1) functional intact RLN, 2)

“Significant” reduction of signal, 3) “Re-entry” signal, 4) recovery signal, 5) loss of signal (LOS), and 6) preoperative vocal cord paralysis (nerve conduction\EMG signal preserved).

Also, short-acting relaxants should be used and a repetitive dose should be avoided (19). When using the C-IONM, an electrode is placed around to the VN and the alarm limits adjusted after deriving an intact signal and amplitude and latency baseline (20,21). Studies show a higher probability of RLN paresis with a decrease in EMG amplitude of >50% and an increase in latency of >10% (20,21).

C-IONM leads to a reduction in the RLN palsy rate has been conclusively clarified recently. Damage caused by tension on the nerve seems to be prevented. Permanent RLN injuries are prevented too (20,21). In one study, in 1,314 nerves at risk (NAR) C-IONM was applied, 965 NAR had I-IONM (20,21). With the use of C-IONM, 63 (82%) of 77 combined events (decreased amplitude and increased latency) were reversible during the operation. No permanent vocal fold palsy occurred with C-IONM, whereas 4 unilateral permanent vocal fold palsies (0.4%) were diagnosed after I-IONM ($P=0.019$) (20,21).

The stringency of the criteria for C-IONM for raising an “alert” is also an important factor that is responsible for the different false-positive and false-negative rates. Uniformity in the criteria for “alerts” is essential. If a low threshold is used for raising an alert, then there is increased chance of false positives, with surgical procedures being unnecessarily altered or abandoned by these false positives. On the contrary, if a high threshold is used for raising an alert, then the chance of false negatives with resultant postoperative neurological deficits is a problem. Therefore, further research is definitely needed from the clinical sector to more fully define parameters for determining the significance of response decrement. Standardization of the IONM using the so-called 6-point method is essential for a reliable interpretation of the signals (19) (**Table 2**).

After resection of the thyroid lobe and completion of all other measures, the final derivation of a signal on the VN before switching to the opposite side is absolutely necessary (18,19). Here, too, a signal of over 500 mcV should be deduced (19).

In data from multicentre studies it could be proven that there is a high positive correlation between positive signal derived from the end of surgery and the vocal fold function measured postoperatively of more than 98% (22,23). Proper prediction of signal loss and vocal cord paralysis is significantly worse and is about 40%–70% for the temporary paresis and about 10% for the permanent paresis (22,23).

In summary, intraoperative detection of RLN paresis has been significantly improved by the use of IONM. Without neuromonitoring, only the visible damage to the nerve allows for a change in the operative strategy.

Table 2. Standardization of IONM in thyroid surgery

| | |
|----|--|
| L1 | Pre-operative laryngoscopy |
| V1 | Test vagus nerve before identification of RLN |
| R1 | Test RLN when it was identified at the tracheo-esophageal groove |
| R2 | Test RLN after it was completely dissected from Berry's ligament |
| V2 | Test vagus nerve after complete hemostasis |
| L2 | Post-operative laryngoscopy |

IONM = intraoperative neural monitoring; RLN = recurrent laryngeal nerve.

A bilateral paresis is also possible with IONM. Melin et al. (24) were able to report 2 cases of bilateral paresis despite intact bilateral IONM. In spite of an intact signal on the first resected side, a further 5 patients had paresis and thus also the risk of bilateral RLN paresis despite the intact signal (24).

The procedure for intraoperative signal loss should be discussed preoperatively with the patient individually. The usual procedure is to stop the operation. However, the continuation of the operation by a very experienced endocrine surgeon in a team or partial resection without exceeding the limit lamella can also be justified in individual cases.

If there is no intact signal of the vagus nerve with preserved continuity of the RLN, it is recommended to check the nerve on its entire prepared route. IONM can then be used to stimulate over all sections to detect the site of signal termination (type I damage, signal from RLN near the larynx, no signal via VN, i.e., segmental injury). If no signal can be derived either over the VN or over the entire RLN, diffuse damage can be assumed (type II damage, no signal via RLN, and no signal via VN (19)).

Equipment failure, electrode dislocation or neuromuscular blockade can be ruled out by stimulation of the contralateral VN.

If the continuity of the RLN is intact and there is no mechanical compression of the nerve, the overall likelihood of recovery from vocal cord paralysis is greater.

Finally, IONM documentation is required at the end of surgery and includes measures of amplitude, latency, waveform morphology, and magnitude of stimulating current (V1, R1, R2, V2 for every side). It includes at minimum the V2 signal of the first resected side.

RESPONSIBILITY OF MONITORING

Surgeons who introduce a new IONM device or procedure in their practice should have completed relevant surgical training, possess operating privileges in the affected endocrine system, and be able to address anticipated complications.

For minor modifications of devices and procedures, surgeons should monitor their practice based on self-assessment. The more substantial the change in surgeons' practice and the higher the risk to the patient, the more important it is that surgeons complete a relevant didactic course, and have their performance objectively assessed and their outcomes monitored.

Surgeon responsibility in monitoring is dual component:

- A. Technical component: using and setting up the IONM equipment correctly and understanding the inherent properties of the system to avoid an erroneous setup (e.g., no muscle relaxation, correct electrode placement, low impedance, etc.).
- B. Interpretive component: is the person performing the monitoring able to distinguish between a true response versus an artifactual one? When problems occur, can thyroid surgeon perform appropriate troubleshooting to identify and correct the issue at hand?

Table 3. Structure of informed consent form for monitored thyroidectomy

| |
|---|
| • Type of surgery |
| • Surgical objectives |
| • Consequence of thyroidectomy |
| • Risk and benefits of doing nothing |
| • Risks of thyroidectomy |
| • Consequences of IONM |
| - Stage thyroidectomy (rate 2.5%) |
| - Technological failures (prevalence <1%) |

IONM = intraoperative neural monitoring.

Complex procedures (C-IONM, superior laryngeal nerve monitoring) benefit greatly from a well-trained team. As the use of monitoring has become increasingly routine, surgical residency programs should begin to include monitoring courses in their core curriculum, and test for competency in this area just as they do in other critical areas (neurosurgery, spine surgery, laparoscopy).

The patient shall beforehand be given appropriate information on the purpose and nature of the intervention and its consequences and risks. The structure of written dedicated informed consent form for modern monitored thyroid surgery should include the following informations (**Table 3**): type of surgery, surgical objectives, consequence of thyroidectomy, risk and benefits of doing nothing (i.e., no surgery), risks of thyroidectomy, and the consequences of the use of IONM that is stage thyroidectomy procedures and possible technological IONM failures.

De facto, with the increased use of IONM, an adaptation of the resection strategy appears to be necessary in case of a LOS of the first operated side with a total thyroidectomy planned. In the case of an intraoperative LOS of the first operated side with total thyroidectomy planned, the contralateral side with intact RLN function from the surgical point of view basically has 3 options:

- C. No contralateral resection in bilateral goiter, Graves' disease, or low risk thyroid carcinoma (differentiated and medullary thyroid carcinomas) with the aim of 2-stage completion surgery after recovery of nerve function.
- D. Contralateral subtotal resection ventrally of the RLN plane in benign goiter with a safety distance to the nerve with the aim of avoiding further surgery.
- E. Total thyroidectomy as planned for advanced thyroid carcinomas (including undifferentiated thyroid carcinomas) with the aim of immediate postoperative radiotherapy.

IONM technology has undergone rapid growth in the thyroid surgical field. In clinical practice, failure of IONM procedures mainly results from a surgeon's inability or to a device malfunction. According to data from the literature, device malfunction or false IONM results are rare (<1%) (19). High false-positive rates should give reason to critically review the clinic-internal standards in order to avoid unnecessary double-stage thyroidectomy. A possible intraoperative recovery of the EMG signal and its importance for the progress of the operation should be the subject of further studies using continuous neuromonitoring. We believe it is important to explain to the patient, as with all the technologies used in surgery, that the IONM can fail or give unreliable results.

We believe it is necessary to complement surgical training with a technical understanding of IONM devices. Organizations such as the International Neural Study Group (INMSG,

www.inmsg.org) and the Korean Intraoperative Neural Monitoring Society (KINMoS, <http://kinmos.or.kr>) provide training courses for surgeon, as well as a means to certify levels of monitoring interpretative competence. Thus, surgeons who choose to perform technical and/or interpretive aspects of monitoring should take advantage of KINMoS educational resources.

Surgeon must be familiar with IONM technology, troubleshooting algorithms, adhere to published current INMSG guidelines to gain the greatest level of predictive intraoperative RLN information and for optimal use of IONM (19).

REFERENCES

1. Haugen BR, Alexander EK, Bible KC, Doherty GM, Mandel SJ, Nikiforov YE, et al. 2015 American Thyroid Association Management Guidelines for adult patients with thyroid nodules and differentiated thyroid cancer: the American Thyroid Association Guidelines Task Force on thyroid nodules and differentiated thyroid cancer. *Thyroid* 2016;26:1-133.
[PUBMED](#) | [CROSSREF](#)
2. Yi KH, Kim SY, Kim DH, Kim SW, Na DG, Lee YJ, et al. The Korean guideline for thyroid cancer screening. *J Korean Med Assoc* 2015;58:302-12.
[CROSSREF](#)
3. Fei X, Yang D, Kong Z, Lou Z, Wu J. Thyroid cancer incidence in China between 2005 and 2009. *Stoch Environ Res Risk Assess* 2014;28:1075-82.
[CROSSREF](#)
4. Sanabria A, Kowalski LP, Shah JP, Nixon IJ, Angelos P, Williams MD, et al. Growing incidence of thyroid carcinoma in recent years: factors underlying overdiagnosis. *Head Neck*, in press 2017.
[PUBMED](#)
5. Statistisches Bundesamt (DE). Fallpauschalenbezogene Krankenhausstatistik (DRG-Statistik): Operationen und Prozeduren der Vollstationären Patientinnen und Patienten in Krankenhäusern- Ausführliche Darstellung. Wiesbaden: Statistisches Bundesamt; 2012.
6. Lamartina L, Durante C, Lucisano G, Grani G, Bellantone R, Lombardi CP, et al. Are evidence-based guidelines reflected in clinical practice? An analysis of prospectively collected data of the Italian thyroid cancer observatory. *Thyroid* 2017;27:1490-7.
[PUBMED](#) | [CROSSREF](#)
7. Barczyński M, Konturek A, Hubalewska-Dydejczyk A, Golkowski F, Nowak W. Ten-year follow-up of a randomized clinical trial of total thyroidectomy versus dunhill operation versus bilateral subtotal thyroidectomy for multinodular non-toxic goiter. *World J Surg*, in press 2017.
[PUBMED](#)
8. Borel F, Christou N, Marret O, Mathonnet M, Caillard C, Bannani S, et al. Long-term voice quality outcomes after total thyroidectomy: a prospective multicenter study. *Surgery*, in press 2017.
[PUBMED](#)
9. Marin Arteaga A, Peloni G, Leuchter I, Bedat B, Karenovics W, Triponez F, et al. Modification of the surgical strategy for the dissection of the recurrent laryngeal nerve using continuous intraoperative nerve monitoring. *World J Surg*, in press 2017.
[PUBMED](#) | [CROSSREF](#)
10. Francis DO, Pearce EC, Ni S, Garrett CG, Penson DF. Epidemiology of vocal fold paralyses after total thyroidectomy for well-differentiated thyroid cancer in a medicare population. *Otolaryngol Head Neck Surg* 2014;150:548-57.
[PUBMED](#) | [CROSSREF](#)
11. Dionigi G, Wu CW, Kim HY, Rausei S, Boni L, Chiang FY. Severity of recurrent laryngeal nerve injuries in thyroid surgery. *World J Surg* 2016;40:1373-81.
[PUBMED](#) | [CROSSREF](#)
12. Dionigi G, Alesina PF, Barczynski M, Boni L, Chiang FY, Kim HY, et al. Recurrent laryngeal nerve injury in video-assisted thyroidectomy: lessons learned from neuromonitoring. *Surg Endosc* 2012;26:2601-8.
[PUBMED](#) | [CROSSREF](#)
13. Cho I, Jo MG, Choi SW, Jang JY, Wang SG, Cha W. Some posterior branches of extralaryngeal recurrent laryngeal nerves have motor fibers. *Laryngoscope* 2017;127:2678-85.
[PUBMED](#) | [CROSSREF](#)

14. Rajabian A, Walsh M, Quraishi NA. Berry's Ligament and the Inferior Thyroid Artery as reliable anatomical landmarks for the Recurrent Laryngeal Nerve (RLN): a fresh-cadaveric study of the cervical spine. The RLN relevant to spine. *Spine J* 2017;17:S33-9.
[PUBMED](#) | [CROSSREF](#)
15. Henry BM, Vikse J, Graves MJ, Sanna S, Sanna B, Tomaszewska IM, et al. Extralaryngeal branching of the recurrent laryngeal nerve: a meta-analysis of 28,387 nerves. *Langenbecks Arch Surg* 2016;401:913-23.
[PUBMED](#) | [CROSSREF](#)
16. Barczyński M, Konturek A, Cichoń S. Randomized clinical trial of visualization versus neuromonitoring of recurrent laryngeal nerves during thyroidectomy. *Br J Surg* 2009;96:240-6.
[PUBMED](#) | [CROSSREF](#)
17. Dionigi G, Boni L, Rovera F, Rausei S, Castelnovo P, Dionigi R. Postoperative laryngoscopy in thyroid surgery: proper timing to detect recurrent laryngeal nerve injury. *Langenbecks Arch Surg* 2010;395:327-31.
[PUBMED](#) | [CROSSREF](#)
18. Riddell V. Thyroidectomy: prevention of bilateral recurrent nerve palsy. Results of identification of the nerve over 23 consecutive years (1946–69) with a description of an additional safety measure. *Br J Surg* 1970;57:1-11.
[PUBMED](#) | [CROSSREF](#)
19. Randolph GW, Dralle H, Abdullah H, Barczynski M, Bellantone R, Brauckhoff M, et al. Electrophysiologic recurrent laryngeal nerve monitoring during thyroid and parathyroid surgery: international standards guideline statement. *Laryngoscope* 2011;121 Suppl 1:S1-16.
[PUBMED](#) | [CROSSREF](#)
20. Schneider R, Sekulla C, Machens A, Lorenz K, Thanh PN, Dralle H. Dynamics of loss and recovery of the nerve monitoring signal during thyroidectomy predict early postoperative vocal fold function. *Head Neck* 2016;38 Suppl 1:E1144-51.
[PUBMED](#) | [CROSSREF](#)
21. Schneider R, Sekulla C, Machens A, Lorenz K, Nguyen Thanh P, Dralle H. Postoperative vocal fold palsy in patients undergoing thyroid surgery with continuous or intermittent nerve monitoring. *Br J Surg* 2015;102:1380-7.
[PUBMED](#) | [CROSSREF](#)
22. Dralle H, Lorenz K. Intraoperative neuromonitoring of thyroid gland operations: surgical standards and aspects of expert assessment. *Chirurg* 2010;81:612-9.
[PUBMED](#) | [CROSSREF](#)
23. Dralle H, Sekulla C, Lorenz K, Brauckhoff M, Machens A German IONM Study Group. Intraoperative monitoring of the recurrent laryngeal nerve in thyroid surgery. *World J Surg* 2008;32:1358-66.
[PUBMED](#) | [CROSSREF](#)
24. Melin M, Schwarz K, Pearson MD, Lammers BJ, Goretzki PE. Postoperative vocal cord dysfunction despite normal intraoperative neuromonitoring: an unexpected complication with the risk of bilateral palsy. *World J Surg* 2014;38:2597-602.
[PUBMED](#) | [CROSSREF](#)