



# Managing the behavior of a patient with autism by sedation via submucosal route during dental treatment

Chan-Woo Jo<sup>1</sup>, Chan-Hee Park<sup>1</sup>, Jong-Hyug Lee<sup>1</sup>, Ji-Hun Kim<sup>2</sup>

<sup>1</sup>Department of Pediatric Dentistry, Wonju Severance Christian Hospital, Yonsei University, Wonju, Korea

<sup>2</sup>Department of Dentistry, Wonju College of Medicine, Yonsei University, Wonju, Korea

In sedation via the submucosal route, the drug is administered through the maxillary buccal submucosa. It is time saving, effective, and safe. Patients with autism, a mental disorder, often find it hard to make relationships with other people. These patients display a strong resistance to dental treatment and sedation. This study reports a successful case of behavioral management during dental treatment, using sedation via the submucosal route. The patient was strongly resistant to sedation via the oral, intramuscular, and intravenous routes. The drug used was 9 mg (0.1 mg/kg) of midazolam. Through this case report, we reaffirm the significance of sedation via the submucosal route, and expect that it will be used more frequently for patients with autism, who display behaviors that are difficult to manage, patients with other disabilities, and children.

**Keywords:** Autism; Behavior; Management; Sedation; Submucosal Route.



This is an Open Access article distributed under the terms of the Creative Commons Attribution Non-Commercial License (<http://creativecommons.org/licenses/by-nc/3.0/>) which permits unrestricted non-commercial use, distribution, and reproduction in any medium, provided the original work is properly cited.



In pediatric dentistry, when the behavior of patients is difficult to manage, dental treatment is performed under sedation [1]. Sedation can be performed via several routes such as the inhalational, oral, intramuscular, and intravenous routes. These routes are mostly used during dental treatment [1]. However, during the preparatory steps, patients sometimes refuse to wear inhalation masks, take pills, or receive intramuscular and intravenous injections due to fear, involuntary action, and other factors. In some cases, even the sedative drug may be inadequate to produce the intended behavior management effects. Sedation via the intravenous route is useful and quick in effect; however, it requires a higher level of clinical technique and monitoring. Moreover, it might be harmful for deep sedation [2]. As an alternative, sedation via the submucosal route is considered. In this method, the

sedative drug is administered into the maxillary buccal submucosa; it is a quick method that produces adequate sedative effects, and can thus serve as an alternative for other sedation routes.

In cases of disabled patients, sedation often becomes necessary to control their involuntary movements. In particular, patients with autism often have difficulties in making relationships; thus, in order to perform dental treatment, sedation becomes necessary [3,4]. However, patients with autism show strong resistance to sedation. Sedation via the submucosal route can thus be used for effective behavior control in such cases, enabling the patients to undergo dental treatment.

So far, only a few studies have compared sedation via the submucosal route and those via other routes [5,6]. This study reports a case of effective behavior manage-

Received: 2017. May. 30. • Revised: 2017. June. 7. • Accepted: 2017. June. 10.

Corresponding Author: Jihun Kim, Department of Dentistry, Wonju College of Medicine, Yonsei University, 20, Ilsan-ro, Wonju-si, Gangwon-do, 220-701, Republic of Korea

Tel: +82-33-741-0673 Fax: +82-33-741-1442 E-mail: [pedo@yonsei.ac.kr](mailto:pedo@yonsei.ac.kr)

Copyright© 2017 Journal of Dental Anesthesia and Pain Medicine

ment by sedation via the submucosal route for a patient with autism, who was resistant to oral medication, intramuscular injection, and intravenous injection.

## CASE REPORT

A 19-year-old male patient came to the department of pediatric dentistry of our hospital in order to get prosthetic treatment for his right mandibular posterior teeth. The patient was given a temporary bridge after preparation of the right mandibular posterior teeth under general anesthesia at our hospital about 2 months ago. On the day of presentation, final preparation and impression for the final bridge were scheduled. The patient had autism, with no other relevant medical history. His weight was approximately 90 kg; height was approximately 180 cm. He was overweight for his age. The degree of autism was so severe that he could not stand still and stubbornly resisted from entering the clinic. In addition, the muscular strength of the patient made it tougher to control his behavior. We decided to administer 10 mg of midazolam via the intramuscular route. However, the patient's resistance to intramuscular injection made it difficult to do so. As the patient was overweight, sedation via the oral route could not be maintained, and he resisted taking oral pills. Moreover, even intravenous injection was difficult, and there were no professionals and monitoring equipment to perform sedation via the intravenous route. Hence, as an alternative, we decided to try sedation via the submucosal route. First, protective stabilization for the patient who had strong involuntary movements was arranged using physical restraint. Then, local infiltration anesthesia was administered with about 0.6 ml of 2% lidocaine (1:100,000 epinephrine) to the left maxillary vestibule, and midazolam was injected into the submucosa at the same spot. The total dose of midazolam was 9 mg (5 mg/ml; 0.1 mg/kg). After about 5 minutes, the patient was under sedation. The level attained was that of conscious sedation, and the airway remained under the patient's voluntary control. During the treatment, he

turned his head or moved his body, both of which did not interfere with the treatment. SpO<sub>2</sub> was continuously monitored during the treatment, and O<sub>2</sub> was continuously supplied through the nasal mask. The duration of the dental procedure was about 40 minutes, and the treatment was safely completed without any side effects of midazolam under good coordination. Approximately 30 minutes after the completion of the treatment, the patient recovered from calm state. After confirming that there was no physical problem, we explained the remarks, and allowed him to go home.

## DISCUSSION

This study reports the case of a patient with autism whose behavior was difficult to manage. The patient displayed resistance to sedation via the oral, intramuscular, and intravenous routes. Thus, the patient was quickly and effectively stabilized by sedation via the submucosal route (Fig 1).

The effect of sedation via the submucosal route can be elucidated from comparative studies on other sedation routes. According to Lee et al. [7], sedation via the submucosal route was more effective than sedation via the oral, intramuscular, and intravenous routes. That is,

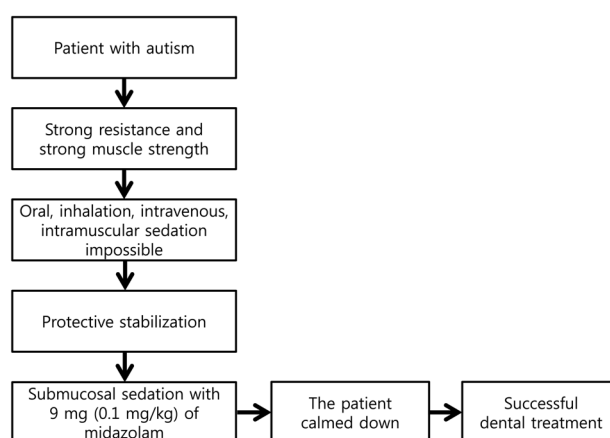


Fig. 1. Flow chart of the case is presented. The patient with autism whose behavior could not be managed was quickly and sufficiently sedated via the submucosal route in a situation where sedation was not possible through other routes.

on comparing submucosal midazolam (0.1-0.2 mg/kg) mixed with oral chloral hydrate (50-70 mg/kg) and oral chloral hydrate (50-70 mg/kg) alone, the combination had better behavior response rating and less vomiting response than oral chloral hydrate used alone. According to Alfonzo-Echeverri et al. [6], after comparing the differential absorption rates of midazolam (0.08 mg/kg to a maximum of 5 mg) in sedation via the submucosal route and the intramuscular route, there was no big difference in average absorption; however, sedation via the submucosal route reached the maximum absorption rate at 10 minutes on an average, and sedation via the intramuscular route reached the maximum absorption rate at 20 minutes on an average. These reports demonstrate that sedation via the submucosal route has better effectiveness and shorter onset time than sedation via the oral and intramuscular routes.

Sedation via the submucosal route shows a more profound effect and shorter working time compared to sedation via the oral route because it is not affected by the first pass effect, that is, the sedative does not pass through the liver [8]. In the case of sedation via the oral route, the sedative loses its effect as it passes through the liver and the gastrointestinal tract by the first pass effect and thus exhibits a longer onset time [9]. In contrast, in the case of sedation via the submucosal route, it directly goes into the cardiovascular system through intraoral veins, without passing through the liver [10].

The shortcoming of sedation via the submucosal route is the discomfort at the injection spot and the vomiting reflex. Moreover, there can be undesirable effects such as respiratory depression, despite the short working time and increased effectiveness. A case of serious side effects along with respiratory depression after sedation via the submucosal route has been reported. It was managed using Alphaprodine, an opium material [11]. However, it is not used anymore, and midazolam, which was used in this case, is safe and effective [12]. Furthermore, flumazenil, a benzodiazepine antagonist, may be used to reverse the effect of midazolam [13]. Flumazenil can reverse the effect of benzodiazepine drugs including

midazolam by competitively binding to the GABA receptor, on which benzodiazepines act [14]. It is mainly injected intravenously, but can also be injected into muscles and submucosa; the recommended dose for intravenous injection is 0.3-0.6 mg. According to Schmitt et al. [15], sedation via the submucosal route was associated a greater local irritable reaction and pain compared to oral sedation; however, the differences were not considerable. In this case, even if the patient had local discomfort, it was much better to use sedation via the submucosal route, as no alternatives could be used.

Unlike this case, not every patient with autism has difficulties in being kept under sedation [16]. However, in this case, the patient was overweight for his age and had high physical strength and resistance. He also displayed autistic symptoms that resist relationships with others and changes in the surrounding environment; this in turn, made it difficult to perform sedative procedures other than sedation via the submucosal route.

In general, submucosal injection is not as technically feasible as intramuscular injection. The reason why submucosal injection could be administered, while intramuscular and intravenous injections could not, was that submucosal injection can be administered using physical restraints such as Pedi-Wrap. Use of physical restraints can hinder the access for intramuscular and intravenous injections. Inpatients in hospitals can be restrained using straps to administer intramuscular and intravenous injection; however, strings or beds are not available in dental clinics. Besides, in the case of intramuscular and intravenous injection, there is difficulty in exposing the injection spot when performing protective stabilization using physical restraints such as Pedi-Wrap. Especially in cases like this, it becomes more difficult to expose the site for intramuscular and intravenous injection under protective stabilization for patients with autism, who have involuntary movements and exhibit resistance with physical strength.

When sedation via submucosal route is performed, it is preferable to use local anesthetics without vasoconstrictors, as the vasoconstrictor may delay the effect

of the sedative [17]. In this case, lidocaine containing epinephrine, which is mainly used in dental clinics, was used because sedation via submucosal route was not planned from the beginning, and it was necessary to perform local anesthesia quickly after restraining the patient. He was considered not to be affected by small amounts of vasoconstrictor because he was overexcited to cause vasodilatation, and overweight.

This study showed that sedation via the submucosal route is an effective way for managing the behavior of patients with autism in situations where other types of sedation are not available. This study highlights the importance of understanding the individual clinical situation and the potential of sedation via the submucosal route. Thus, sedation via the submucosal route is expected to be more frequently used for patients with autism who cannot be sedated by other routes, patients with other disabilities, and children. Follow-up studies about sedation via submucosal route in various situations are expected to be presented.

#### AUTHOR ORCIDs

Chan-Woo Jo: <http://orcid.org/0000-0003-4777-0080>

Chan\_Hee Park: <http://orcid.org/0000-0002-4391-449X>

Jong-Hyung Lee: <http://orcid.org/0000-0003-1197-1307>

Ji-Hun Kim: <http://orcid.org/0000-0002-2124-0818>

**NOTES:** There are no financial or other issues that might lead to conflict of interest.

#### REFERENCES

- Moore PA, Mickey EA, Hargreaves JA, Needleman HL. Sedation in pediatric dentistry: a practical assessment procedure. *J Am Dent Assoc* 1984; 109: 564-9.
- Runes J, Ström C. Midazolam intravenous conscious sedation in oral surgery. A retrospective study of 372 cases. *Swed Dent J* 1995; 20: 29-33.
- Rapin I, Tuchman RF. Autism: definition, neurobiology, screening, diagnosis. *Pediatr Clin North Am* 2008; 55: 1129-46.
- Braff M, Nealon L. Sedation of the autistic patient for dental procedures. *ASDC J Dent Child* 1978; 46: 404-7.
- Baek KW. Considerations for submucosal midazolam administration in combination with oral and inhaled medications for sedation of pediatric dental patients. *J Dent Anesth Pain Med* 2015; 15: 47-52.
- Alfonzo-Echeverri E, Troutman KC, George W. Absorption and elimination of midazolam by submucosal and intramuscular routes. *Anesth Prog* 1990; 37: 277-81.
- Lee YE, Park MK, Kim YH, Jung SH, Baek KW. The sedative effects of submucosal midazolam in children. *J Korean Dent Soc Anesthesiol* 2005; 5: 101-6.
- Song YU, Webb MD. Comparison of the effect of orally versus submucosally administered meperidine on the behavior of pediatric dental patients: a retrospective study. *Anesth Prog* 2003; 50: 129-33.
- Thummel KE, O'shea D, Paine MF, Shen DD, Kunze KL, Perkins JD, et al. Oral first-pass elimination of midazolam involves both gastrointestinal and hepatic CYP3A-mediated metabolism. *Clin Pharmacol Thera* 1996; 59: 491-502.
- Trapp LD, Goodson JM, Price DC. Evaluation of oral submucosal blood flow at dental injection sites by radioactive xenon clearance in beagle dogs. *J Dent Res* 1977; 56: 889-93.
- Hine CH, Pasi A. Fatality after use of alphaprodine in analgesia for dental surgery: report of case. *J Am Dent Assoc* 1972; 84: 858-61.
- Azevedo ID, Ferreira MAF, da Costa APS, Bosco VL, Moritz RD. Efficacy and safety of midazolam for sedation in pediatric dentistry: a controlled clinical trial. *J Dent Child* 2013; 80: 133-8.
- Brogden RN, Goa KL. Flumazenil. A reappraisal of its pharmacological properties and therapeutic efficacy as a benzodiazepine antagonist. *Drugs* 1991; 42: 1061-89.
- Whitwam JG, Amrein R. Pharmacology of flumazenil. *Acta Anaesthesiol Scand Suppl* 1995; 108: 3-14.
- Schmitt M, Nazif MM, McKee KC, Zullo T, Venkataramanan R, Burckart G, et al. Pharmacokinetics and local responses to submucosal meperidine compared

- with other routes of administration. *Pediatr Dent* 1994; 16: 190-2.
16. Pisalchaiyong T, Trairatvorakul C, Jirakijja J, Yuktarnonda W. Comparison of the effectiveness of oral diazepam and midazolam for the sedation of autistic patients during dental treatment. *Pediatr Dent* 2005; 27: 198-206.
17. Myers GR, Maestrello CL, Mourino AP, Best AM. Effect of submucosal midazolam on behavior and physiologic response when combined with oral chloral hydrate and nitrous oxide sedation. *Pediatr Dent* 2004; 26: 37-43.