

A Case of Lamotrigine-Induced Excessive Involuntary Eye Blinking

Dong-Gun Kim, M.D., Seung-Hun Oh, M.D., Ok Joon Kim, M.D.

Department of Neurology, Pochon CHA University, College of Medicine, Sunghnam, Korea

A wide variety of movement disorders can be induced by the administration of antiepileptic drugs. A 44-year-old female was admitted with involuntary excessive eye blinking that manifested 5 months after beginning the administration of lamotrigine for control of complex partial and secondarily generalized seizures. The involuntary eye blinking persisted while taking lamotrigine, and disappeared 1 month after the cessation of lamotrigine. The development of atypical involuntary eye blinking in this case may have resulted from the inhibition of excitatory neurotransmitters by lamotrigine, which led to secondary dysfunction of the dopaminergic system.

J Clin Neurol 3(2):93-95, 2007

Key Words : Lamotrigine, Eye Blinking, Side Effect

Lamotrigine (3,5-diamino-6-(2,3-dichlorophenyl)-1,2,4- triazine; LTG) is one of the most commonly used broad-spectrum antiepileptic drugs (AEDs). In vitro pharmacological studies suggest that LTG inhibits voltage-sensitive sodium channels, thereby stabilizing neuronal membranes and consequently modulating the presynaptic release of excitatory amino acid transmitters (e.g., glutamate and aspartate).¹ Common side effects of LTG are skin rash, dizziness, headache, ataxia, nausea, vomiting, and diplopia. There are several case reports of the development of involuntary movement disorders including chorea and tic disorder after LTG treatment.^{2,3} However, LTG-induced involuntary eyelid movement disorder is extremely rare. Here we present a case with LTG-induced excessive involuntary eye blinking.

A 44-year-old female presented with excessive involuntary eye blinking with a 5-month history. She had no family history of epilepsy or movement disorder. She had a history of febrile convulsion with a frequency of 5 or 6 times per year during infancy. When she was 7 years old, she was diagnosed with epilepsy and started medication with AEDs. Semiology revealed complex partial seizures composed of vacant staring and automatism with occasionally secondary generalized tonic-clonic seizures. She was recently treated with phenobarbital (maintenance dose of 60 mg/day) in combination with primidone (250 mg/day) at a local clinic, which decreased her seizure frequency to twice yearly. Five months prior to visiting our clinic, she was treated with LTG (Lamictal® at 25 mg/day) following discontinuation of previous AEDs at another hospital. The dosage of LTG was increased slowly to 200 mg/day, and her seizures were well controlled. However, 5 months after LTG treatment, an involuntary eye blinking

CASE REPORT

Received : April 10, 2007 / Accepted : May 25, 2007 / Address for correspondence : Ok Joon Kim, M.D.

Department of Neurology, College of Medicine, Pochon CHA University, 351 Yatap-dong, Bundang-gu, Seongnam-si, Gyeonggi-do, 463-712, Korea
Tel.: +82-31-780-5481, Fax: +82-31-780-5198, E-mail: okjun77@cha.ac.kr, okjun77@hanmail.net

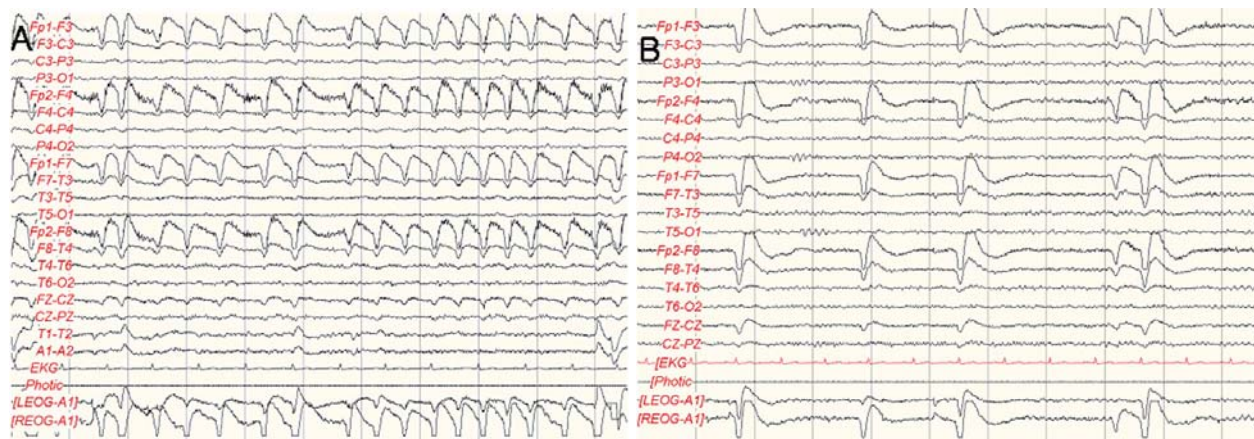


Figure 1. Electroencephalography study shows no epileptiform discharges during eye blinking. On simultaneous electromyography (EMG) attached to surface electrodes on both eyelid muscles, the frequency of eyeblinking after cessation of lamotrigine was normalized to 0.5 times/second (B) compared with on medication of lamotrigine (1.7 times/second) (A)

developed. No other medication (including digestives) was prescribed and no procedure was performed when this symptom developed. She visited our hospital because of persistent excessive involuntary eye blinking for the previous 5 months.

The initial neurological examination revealed excessive eye blinking with a frequency of about twice per second that was not accompanied with blepharospasm. She could not voluntarily control her eye blinking, and the frequency of eye blinking did not change during extraocular movement at any direction or during conversation. Cranial nerve function including pupil light reflex and extraocular movement, facial motor and sensory functions, corneal reflex, and glabella reflex were all normal. Other neurologic examinations produced normal results. Video monitoring combined with electroencephalography (EEG) with extra electrodes 1 cm lateral to both orbits showed normal findings without epileptiform discharges. Eye blinking on electromyography (EMG) continued at a frequency of 1.7 times/second during EEG monitoring (Fig. 1-A). Facial nerve conduction and the blink reflex were normal. We changed LTG to topiramate (Topamax® at 100 mg/day), with the dosage subsequently being increased to 200 mg/day. The excessive involuntary eyelid blinking improved gradually 1 month after the cessation of LTG. We changed topiramate to valproic acid (Depakote ER® at 500 mg/day) due to intolerable side effects of a poor

appetite and tingling sensation. After treatment of valproic acid and cessation of LTG, the episodes of involuntary eye blinking resolved completely without an seizures. Repeated EEG monitoring revealed that the frequency of eye blinking had decreased (to once every 2 seconds) (Fig. 1-B), and excessive eye blinking was absent at a 7-month follow-up.

DISCUSSION

Eye blinking is fundamental to corneal wetting and eye protection, and consists of two physiologic components: (1) inhibition of sustained activity of the levator palpebrae superioris muscles and (2) concurrent activation of the orbicularis oculi muscles.⁴ The eye-blinking signal is generated in the reticular formation of the rostral pons and regulated by the substantia nigra, superior colliculus, occipital cortex via the lateral geniculate body, and optic radiation. The thalamus and cerebellum are also involved in the production of eye blinking.⁵ An abnormal eye blinking rate is observed in many diseases involving the central nervous system. The rate of eye blinking is usually decreased in Parkinson's disease, but increased in schizophrenia, Huntington's disease, and blepharospasm.⁵ In depression, eye blinking can be either increased or decreased.⁵

Our patient did not show any cognitive or motor

deficits except for the excessive involuntary eye blinking, and this was not induced by seizure based on the EEG findings being normal during excessive eye blinking. An association with depression was unlikely because there was no evidence of mood disorder. Excessive involuntary eye blinking began in our patient after 5 months of administration with LTG and disappeared completely after the cessation of LTG, which indicates a close association between the condition and LTG.

Various involuntary movements as side effects of AEDs have been reported. Tremor (postural or kinetic) is one of common side effects of AEDs such as valproic acid and phenytoin.^{6,7} Chorea was reported in several patients receiving phenytoin or valproic acid.^{8,9} LTG-induced eyelid movement disorder is extremely rare. Verma et al.¹⁰ reported a patient who developed blepharospasm 4 months after beginning the administration of LTG, with it disappearing 1 month after the cessation of LTG. However, to our knowledge, involuntary eye blinking associated with LTG has not been reported previously.

Many drug-induced movement disorders are related to an enhanced dopaminergic system. Neuroleptics are representative of the drugs that induce abnormal movement, acting on dopamine receptors directly and leading to postsynaptic dopamine supersensitivity and a postsynaptic increase in the number of dopamine receptors.⁵ The mechanism of LTG-induced involuntary movement has been unclear. LTG does not directly affect striatal dopamine receptors, and hence the pathophysiological mechanism of LTG-induced involuntary movement differs from that induced by neuroleptics. One possible explanation is that LTG inhibits presynaptic excitatory neurotransmitters, which induce the striatal dopaminergic system secondarily. For example, amantadine, a subtype N-methyl-D-aspartate receptor (NMDA) blocker, exerts antiparkinsonian effects via inhibition of NMDA receptors, which secondarily facilitates the presynaptic release of striatal dopamine. Although LTG has no effect of NMDA receptor blockade, it may indirectly influence the dopaminergic system by inhibiting some types of excitatory neurotransmitters. Zipp et al.¹¹ reported five patients with Parkinson's disease who were successfully treated with LTG, which suggests that LTG can in-

fluence the dopaminergic system indirectly via an unknown mechanism, even though it is not associated with the direct inhibition of dopamine or glutamate receptors. Further investigations are needed to clarify the exact pathophysiological mechanism of LTG-induced involuntary movement.

In conclusion, we report a case of LTG-induced excessive involuntary eye blinking. The results presented here indicate that unrepresentative side effects such as involuntary eye blinking should be considered when LTG is administered.

REFERENCES

1. Leach MJ, Marsden CM, Miller AA. Pharmacological studies on lamotrigine, a novel potential antiepileptic drug: II. Neurochemical studies on the mechanism of action. *Epilepsia* 1986;27:490-497.
2. Das KB, Harris C, Smyth DP, Cross JH. Unusual side effects of lamotrigine therapy. *J Child Neurol* 2003;18: 479-480.
3. Sotero de Menezes MA, Rho JM, Murphy P, Cheyette S. Lamotrigine-induced tic disorder: report of five pediatric cases. *Epilepsia* 2000;41:862-867.
4. Esteban A, Traba A, Prieto J. Eyelid movements in health and disease. The supranuclear impairment of the palpebral motility. *Neurophysiol Clin* 2004;34:3-15.
5. Ebert D, Albert R, Hammon G, Strasser B, May A, Merz A. Eye-blink rates and depression. Is the antidepressant effect of sleep deprivation mediated by the dopamine system? *Neuropsychopharmacology* 1996;15:332-339.
6. Karas BJ, Wilder BJ, Hammond EJ, Bauman AW. Valproate tremors. *Neurology* 1982;32:428-432.
7. Turkdogan D, Onat F, Ture U, Pamir N. Phenytoin toxicity with mandibular tremor secondary to intravenous administration. *Int J Clin Pharmacol Ther* 2002;40:18-19.
8. Saito Y, Oguni H, Awaya Y, Hayashi K, Osawa M. Phenytoin-induced choreoathetosis in patients with severe myoclonic epilepsy in infancy. *Neuropediatrics* 2001;32: 231-235.
9. Gunal DI, Guleryus M, Bingol CA. Reversible valproate-induced choreiform movements. *Seizure* 2002;11:205-206.
10. Verma A, Miller P, Carwile ST, Husain AM, Radtke RA. Lamotrigine-induced blepharospasm. *Pharmacotherapy* 1999; 19:877-880.
11. Zipp F, Baas H, Fischer PA. Lamotrigine-antiparkinsonian activity by blockade of glutamate release? *J Neural Transm Park Dis Dement Sec* 1993;5:67-75.