

## A Case of Propofol-Induced Delayed-Onset Refractory Myoclonic Seizures

Hyung Won Jeon, M.D., Ji Hye Kang, M.D., Hyun Sook Kim, M.D.,  
Hee Young Jo, M.D., Sang-Ho Kim, M.D.

*Department of Neurology, College of Medicine, Dong-A University, Busan, Korea*

Propofol, a GABA-mediated inhibitor of excitatory neurotransmitter, is a popular intravenous agent for general anesthesia and sedation. Its side effects reportedly include opisthotonus, seizures, and myoclonus, and are usually manageable. We present a patient who developed propofol-induced delayed-onset refractory myoclonic seizures that resisted antiepileptic drugs.

*J Clin Neurol 3(3):154-157, 2007*

**Key Words :** Propofol, Myoclonic seizure, Status epilepticus

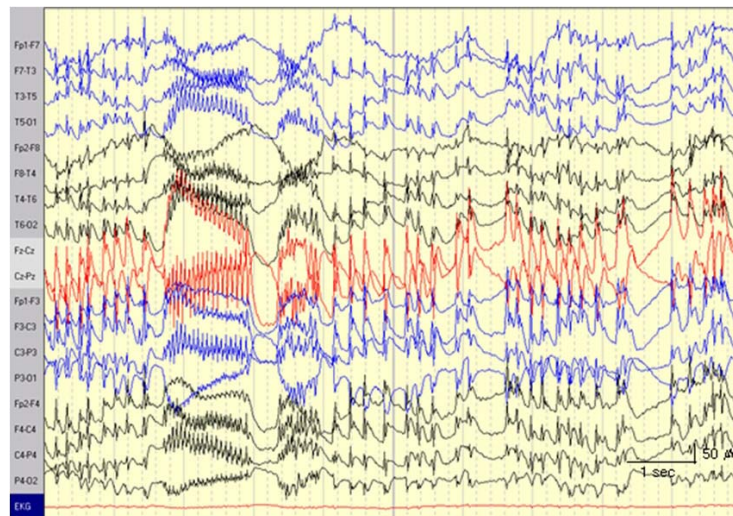
Propofol (2,6-diisopropylphenol) has been widely used since 1980 for anesthesia, sedating patients in intensive care units, and treating intractable status epilepticus. Neuroexcitation is an uncommon but well-recognized side effect of propofol anesthesia and sedation. Side effects can occur during the induction of, maintenance of, or emergence from anesthesia. Some case reports have also described propofol-induced delayed-onset seizures.<sup>1,2</sup> However, these side effects seldom produce neurologic sequelae.

### CASE REPORT

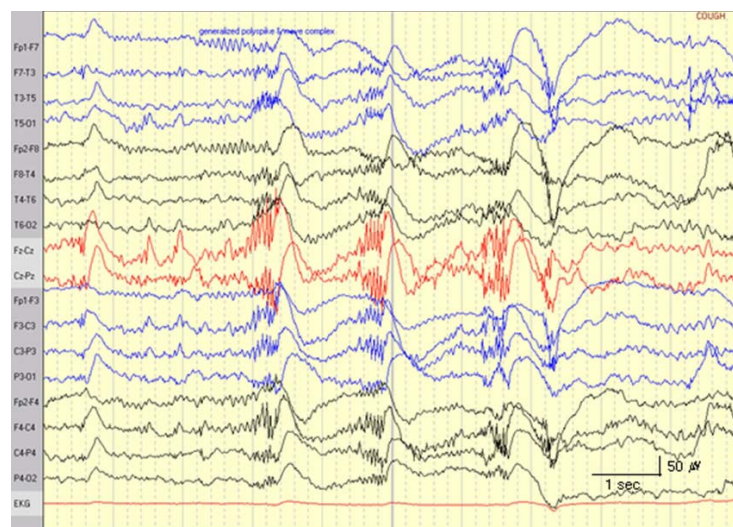A 31-year-old woman visited her local hospital for an IVF (*in vitro* fertilization) procedure because of infertility. The patient had no previous medical history except for infertility and no history of epilepsy, drug abuse, or recent infection. She had undergone propofol anesthesia for an IVF procedure with no complications

2 years previously. However, she lost consciousness and began to convulse 30 minutes after the end of this second experience of propofol anesthesia. Her seizure was stopped with a benzodiazepine injection and she recovered consciousness. A neurologic examination revealed a sedative mental state due to benzodiazepines, but other findings were unremarkable. On the next morning seizures developed again and were not controlled despite injecting benzodiazepines and phenytoin, so she was transferred to our hospital.

In our emergency room, her vital signs were stable except for a fever (39.4°C). The white cell count was 21530/ $\mu$ l, the C-reactive protein level was increased to 10.84 mg/dl, and the troponin-I level was 0.59 ng/ml, but the other laboratory findings were within normal limits. There was no evidence of infection in the chest X-ray, urinalysis, cerebrospinal fluid analysis, or gynecologic examination. Echocardiography and brain MRI findings were normal. On the following day her white cell count had decreased to 13800/ $\mu$ l,



**Figure 1.** Example EEGs showing frequent generalized polyspike-and-wave complexes followed by rhythmic fast waves at 15 Hz.



**Figure 2.** Example EEGs showing polyspike-and-wave complexes without rhythmic fast activity.

the troponin-I level was 0.12 ng/ml, and the fever had normalized.

An initial neurological examination showed deep-stupor mentality and long-lasting generalized myoclonic seizures followed by intermittent opisthotonus. Diazepam and lorazepam were injected immediately but did not control her seizures, and EEGs showed generalized polyspikes and waves followed by rhythmic fast waves at 15 Hz (Fig. 1). The generalized polyspike-and-wave complexes coincided with the occurrence of generalized myoclonic seizures, and the subsequent rhythmic fast

waves coincided with brief opisthotonus. Valproic acid (1600 mg) was therefore injected over a 10-minute period, which stopped her opisthotonus but had no effect on her generalized myoclonic seizures. Continuous infusion of lorazepam at up to 9 mg/kg/hour for 48 hours stopped the spontaneous myoclonic seizures, but myoclonic seizures could still be evoked by subtle stimulations such as light touch or sound, and ictal waves continued (Fig. 2). Therefore, Pentothal was infused continuously at 3 mg/kg/hour, which after 3 days decreased the frequency and severity of

myoclonic seizures. This dosage of Pentothal infusion was maintained for 3 weeks because seizures recurred when the dosage was reduced. Her mentality recovered as the Pentothal dosage was reduced after adding valproic acid and topiramate, but the myoclonic seizures were aggravated when Pentothal was stopped. The addition of lamotrigine and phenobarbital allowed Pentothal infusion to be stopped, but myoclonic seizures could now be evoked by stimulation. Two months after admission, the frequency and severity of her myoclonic seizures were reduced sufficiently for the patient to perform the activities of daily living.

## DISCUSSION

Propofol is a rapid onset and short-acting intravenous anesthetic agent.<sup>3</sup> Since its introduction in 1980,<sup>4</sup> it has been widely used for anesthesia, sedating patients in intensive care units, and treating intractable status epilepticus.<sup>3,4</sup>

Few side effects of propofol have been reported. Hypotension and dose-dependent breathing depression may occur during the induction of anesthesia, and a burning pain may occur in the region of injection. Neuroexcitation is an uncommon but well-recognized side effect of propofol anesthesia and sedation. Unresponsiveness, myoclonus, transient opisthotonus, refractory dystonia, ataxia, seizures, and transient seizure-like phenomena, all occurring either with or without an altered mental status, have been described during the induction of, maintenance of, and emergence from propofol anesthesia and sedation. These complications occur most frequently at the induction and emergence states, so a rapid change in the propofol concentration in the brain may be crucial for the generation of seizures.<sup>5</sup>

If patients are appropriately treated, most neurologic complications associated with propofol resolve spontaneously.<sup>2,6</sup> Additionally, abnormal EEG findings are rare after the neurologic complication has improved.<sup>7</sup>

Several cases with delayed-onset seizures following propofol anesthesia have been reported, but most of the patients recovered with no neurological compli-

cations, and the duration of seizures was limited to no more than several days in all but one case (which lasted for 18 days).<sup>8</sup> Trotter and Serpell reported neurological sequelae that occurred in two children after the withdrawal of propofol infusion: twitching movements persisting for 18 days, and choreiform movements of the arms persisting for 9 days despite antiepileptic treatment.<sup>9</sup>

The pathophysiological mechanisms underlying the neuroexcitatory symptoms associated with propofol are unknown, but several possible mechanisms have been proposed, including dose-related effects on inhibitory and excitatory neurons, drug-induced decerebrate rigidity, strychnine-like effects on glycinergic and GABAergic pathways, uncoordinated neuronal oscillations because of GABA-mediated enhanced inhibitory transmission, a relaxant effect of central muscles at high tissue concentrations,<sup>10</sup> imbalance between cholinergic and dopaminergic activity at the level of basal ganglia, and epileptic dampening.<sup>11</sup> Propofol has a delayed terminal elimination half-life<sup>12</sup> that may reflect its slow return from poorly perfused peripheral compartments back into the central compartment. Hence, significant concentrations of propofol may persist for some time within the nervous system, producing effects that depend on the balance between inhibitory and excitatory neurons. However, additional studies are needed to determine the precise biochemical or biophysical origin of these excitatory phenomena associated with propofol use.

Our patient had no history of previous seizure events, and had not presented side effects when first exposed to propofol. However, her first seizure occurred during recovery from her second experience of propofol anesthesia, and this was easily controlled by a benzodiazepine injection. However, another delayed seizure occurred 1 day after this first seizure, and was aggravated to status epilepticus. Although we had administered intensive antiepileptic treatment, her mentality did not improve and her seizures continued. Even though we had treated the patient with a combination therapy of antiepileptic agents for 2 months, her myoclonic seizures were not in complete remission when she was discharged from the hospital. To our knowledge,

this is the first reported case of propofol-induced refractory seizures in Korea. Our patient had delayed-onset refractory myoclonic seizures that resisted anti-epileptic drugs and were documented by EEGs.

## REFERENCES

1. Jung SH, Kim TW, Jung KY, Kim JM. A case of propofol-induced seizure-like phenomena. *Korean J Epilepsy Soc* 2003;7:51-53.
2. Finley GA, MacManus B, Sampson SE, Fernandez CV, Retallick R. Delayed seizures following sedation with propofol. *Can J Anaesth* 1993;40:863-865.
3. Jungheinrich C, Scharpf R, Wargenau M, Dilger C, Bepperling F. Pharmacokinetics of the generic formulation propofol 1% fresenius in comparison with the original formulation (Disoprivan 1%). *Clin Drug Investig* 2002; 22:417-427.
4. Walder B, Tramer MR, Seeck M. Seizure-like phenomena and propofol: a systematic review. *Neurology* 2002;58: 1327-1332.
5. Sounders PRI, Harris MNE. Opisthotonus and other unusual neurological sequelae after outpatient anaesthesia. *Anaesthesia* 1990;45:552-557.
6. Bevan JC, Veall GRO, Macnab AJ, Ries CR, Marsland C. Midazolam premedication delays recovery after propofol without modifying involuntary movements. *Anesth Analg* 1997;85:50-54.
7. Sneyd JR. Excitatory events associated with propofol anaesthesia: a review. *J R Soc Med* 1992;85:288-291.
8. Saravanakumar K, Venkatesh P, Bromley P. Delayed onset refractory dystonic movements following propofol anaesthesia. *Paediatr Anaesth* 2005;15:597-601.
9. Trotter C, Serpell MG. Neurological sequelae in children after prolonged propofol infusion. *Anaesthesia* 1992;47: 340-342.
10. Borgeat A, Dessibourg C, Popovic V, Meier D, Blanchard M, Schwander D. Propofol and spontaneous movements: an EEG study. *Anesthesiology* 1991;74:24-27.
11. Makela JA, Livanainen M, Pieninkeroinen IP, Waltimo O, Lahdensuu M. Seizures associated with propofol anaesthesia. *Epilepsia* 1993;34:832-835.
12. Campbell GA, Morgan DJ, Kumar K, Crankshaw DP. Extended blood collection period required to define distribution and elimination kinetics of propofol. *Br J Clin Pharmacol* 1988;26:187-190.