



# Effects of counter torque and transposition (transfer) of installed implants timing on their integration in dog tibia

Mohammad Reza Karimi<sup>1\*</sup>, Shima Fathi<sup>2</sup>, Farzin Ghanavati<sup>3</sup>

<sup>1</sup>Department of Periodontics, Dental Branch, Islamic Azad University, Tehran, Iran

<sup>2</sup>Postgraduate of Oral Medicine, Dental Branch, Hamadan University of Medical Sciences, Hamadan, Iran

<sup>3</sup>Department of Periodontics, Dental Research Center, Dental School, Shahid Beheshti University of Medical Sciences, Tehran, Iran

**PURPOSE.** The purpose of this research was to evaluate the amount of reosseointegration after counter torquing (reverse torque) and transposing the installed implants at different times. **MATERIALS AND METHODS.** This study was done on ten tibiae of five cross-bred dogs. At the first day one implant was installed in each tibia. After one week half of the implants were randomly counter torqued (1WCT) and the other half were explanted and reimplanted in a new juxtaposition site (transposed)(1WT). At the same time three new implants were installed in each dog, one of them was considered as one week control (1WC) and remaining two as 8 week groups (8WCT&8WT). After eight weeks the 1WCT and 1WT implants were loosened by counter torque and the quantity of needed force for liberation was measured with the digital device (BGI). At the same time one implant was installed in each dog as eight week control (8WC) and the same protocol was repeated for 8 week groups after another 8 weeks. **RESULTS.** All implants were osseointegrated. Mean quantities of osseointegration in case groups indicated better amounts rather than control groups. **CONCLUSION.** Counter torque or transposition of the installed implants one week or eight weeks after the implantation did lead to osseointegration. [J Adv

Prosthodont 2015;7:62-8]

**KEY WORDS:** Implant; Reverse torque; Counter torque; Osseointegration; Reintegration

## INTRODUCTION

Nowadays changing the position of inserted implants is done in individual clinical experiments. In many cases the

integrated implants are not in an appropriate position and can cause pressure to the dental nerves, maxillary sinus membrane damage or many difficulties in prosthetic procedure due to incorrect implant direction. On the other hand the implant may rotate during the abutment screw tightening or prosthetic treatment in immediate, early or delayed loading.<sup>1</sup> During these procedures a sheer force is transmitted to implant-bone interface. This strength obviously has a detrimental effect on the bone next to the implant and could lead to disintegration.<sup>2,3</sup>

Rotation of an implant after eight weeks of healing, based on contractual implant success benchmark, could be a sign of failure and in this situation implant removal would be planned even in the absence of the other established indicators of non-osteointegration.<sup>4-8</sup> In other words loose implants are considered as failure and are prescribed to be removed.<sup>1</sup> But several studies have shown that loose implant can result from the absence of bone-implant contacts,<sup>1</sup> and is not considered as the failed implant.<sup>1,9-11</sup> There is a difference between rotational mobility and buccolingual mobility.<sup>2</sup>

Corresponding author:  
Mohammad Reza Karimi  
Department of Periodontics, Dental Branch, Islamic Azad University,  
4th floor, no 5, 2nd St, Niloufar St, Apadana St, Tehran 1533853911, Iran  
Tel. 98 09126082162: e-mail, shfathi7@gmail.com  
Received July 31, 2014 / Last Revision October 27, 2014 / Accepted  
November 7, 2014

© 2015 The Korean Academy of Prosthodontics  
This is an Open Access article distributed under the terms of the Creative  
Commons Attribution Non-Commercial License (<http://creativecommons.org/licenses/by-nc/3.0>) which permits unrestricted non-commercial use,  
distribution, and reproduction in any medium, provided the original  
work is properly cited.

This study was supported by Dental Research Center, Shahid Beheshti University M.C, Tehran, Iran and Dentium Co.(Republic of Korea) for providing Implantium implant system. The authors thank Dr. Davood Sharifi, Veterinary Medicine, Tehran University of Medical Sciences, Tehran, Iran and Dr. Ali Reza Akbarzadeh Baghban, statistical analyst, Shahid Beheshti University of Medical Sciences and Mr. Kaveh Tagharobi for editing the article.

According to observations from clinicians, despite the possibility of non integration implicated by the rotation,<sup>4</sup> it seems acceptable if the implant is allowed to heal for an additional period of time, integration of an implant can be re-established.<sup>1,12</sup> Considering the resistance to 20 Ncm reverse torque is a parameter for osseointegration and a measure of functional stability,<sup>13</sup> so clinicians have to decide how long they should wait for re-integration of the implant or when they should remove it from the mouth.<sup>2</sup> However, there are very limited data supporting their decision at present.<sup>2</sup> There is no basic and fulfilling study in this field therefore more research due to the increasing use of implant in the world and also the interest in early and immediate loading of implants is needed.<sup>2,4</sup>

This investigation is designed to find the answer to two questions: First, the best time and the success of counter torquing or transposition of inserted implants, second: whether it is possible, for any given reason, to transport implants in the bone once they are integrated.

## MATERIALS AND METHODS

Five male adult dogs weighting 25-30 kg were used in this investigation. The protocol of this study was approved by the Ethics Committee of Shahid Beheshti University School of Dentistry, Tehran, Iran, and the National Animal Care Society, Tehran, Iran. A period of 10 days was considered to standardize the diet and environmental conditions of the dogs.<sup>14</sup>

All the procedures were done by one clinician. An overall number of thirty implants (Implantium, Republic of Korea, 3.80 mm × 10 mm) were used in this study, that is, three in each dog's tibia making it six for each individual dog. The consensus on dividing implants into six groups was made: 1) one week control (1WC), 2) eight week control (8WC), 3) one week counter torque (1WCT), 4) one week transposition (1WT), 5) eight week counter torque (8WCT); and 6) eight week transposition (8WT). All dogs received the whole six implant groups.

For 12 hours the dogs were in full non-diet regime before operation with no water for four hours. An intramuscular (IM) injection of ketamine 10%, (10 mg/kg) (Rotexmedica co, GmbH, Germany) and Xylazine 2%, (1 mg/kg) (Behyar Saman Pharmaceutical Co, Tehran, Iran), was used to sedate the animals prior to operation. The IV injection Sodium thiopental 5% (Behestan Darou Co, Tehran, Iran) with average dose (10 mg) was used for general anesthesia. The tibia was rinsed thoroughly with Saline (Shahid Ghazi Pharmaceutical Co, Tabriz, Iran) and Povidine-iodine (Tolid Darou Co, Tehran, Iran). Following operation, animals were taken care of according to the protocol of Tehran Veterinary School, Tehran, Iran, with a special diet and supporting medicament. Prophylactic IM 6.3.3 Penicillin (Jaber Ebne Hayan Laboratories, Tehran, Iran), Dexamethasone 2 cc (Darou Pakhsh, Tehran, Iran), B complex 2 cc (Exire Pharmaceutical Co, Tehran, Iran), Mefenamic capsule 250 mg (Razak Laboratories, Tehran,

Iran) per 12 hours and Tramadol tablet 100 mg (Razak Laboratories, Tehran, Iran) per 12 hours was administered daily. The presences of edema or inflammation in the area of sutures were inspected. The sutures were removed on the seventh or twelfth day following surgery.

The sterile conditions were maintained throughout the operation.

Week 0: For surgical procedures, the animals were anaesthetized. The surgical implantation was performed through a crestal incision<sup>4</sup> and the tibia metaphyses were exposed by full thickness flap and with the ample reflection of the periosteal flap.<sup>4</sup> One implant was inserted in the proximal part of each tibia (two implants in each dog) during vigorous irrigation with sterile saline.<sup>1</sup> The implants were inserted 1 mm subcrestal in bone (Fig. 1).

Week 1: After one week, in second session, all animals were anaesthetized for the second time, as described above.<sup>1</sup> Randomly, one implant in one tibia of each dog was counter torqued by applying a reverse force with a ratchet and the implant in another tibia was transposed. Also, three new implants were inserted in each dog so that the two implants in two different tibiae in each dog were considered as the eight-week group and another one was considered as the first control group (Fig. 1).

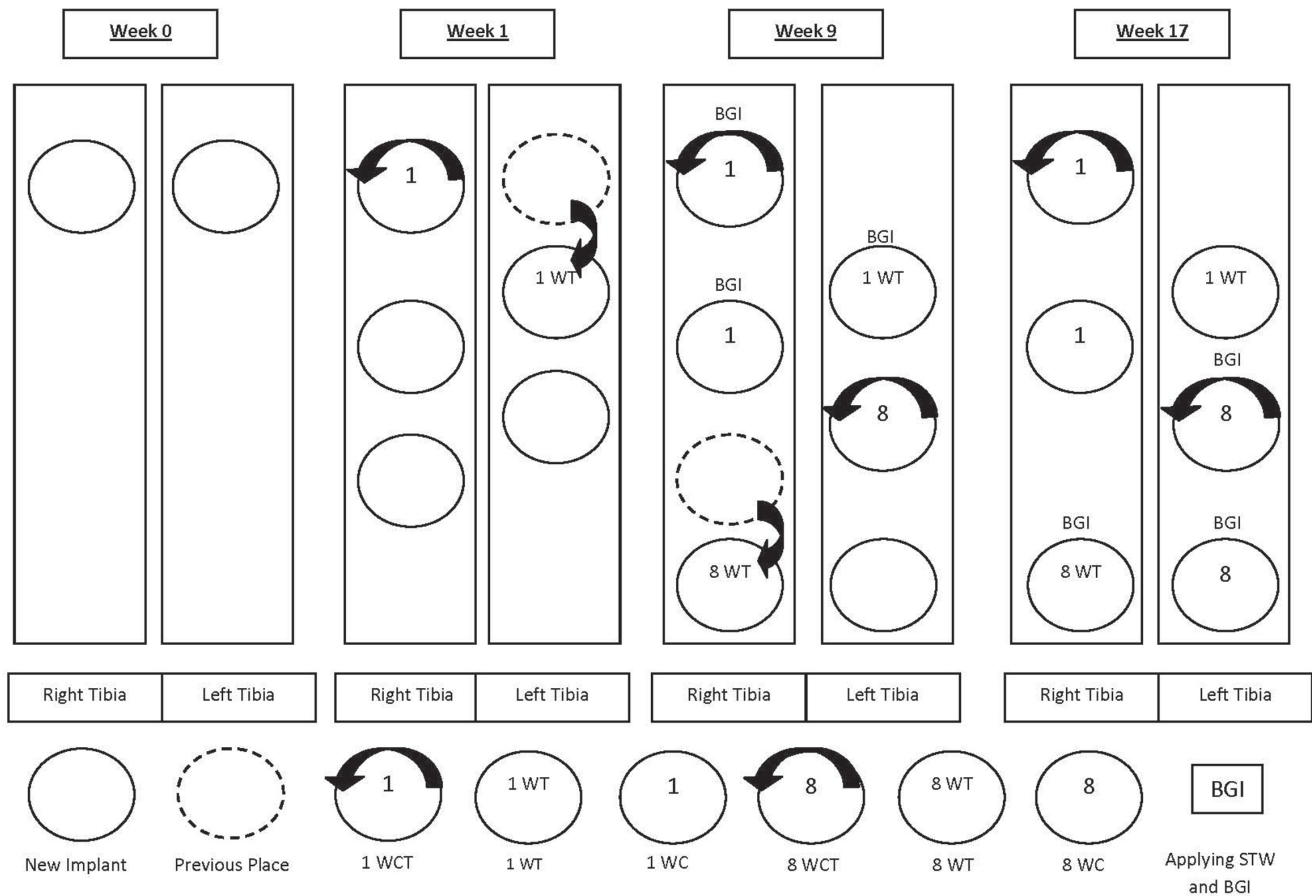
Week 9: After eight weeks, during the third session, the one week group implants and first control group implants were counter torqued using Mark-10 universal torque series sensor STW and the force values were read using a Mark-10 Force/torque Indicator Model BGI (JLW Instruments, Chicago, IL, USA).<sup>4</sup> The torque sensor was fitted with a special extension attached to the implant mount for access,<sup>4</sup> Once connected, the torque indicator system was placed in peak-force ready mode,<sup>4</sup> and the increasing counter torque was applied until the detachment from bone was observed,<sup>4</sup> then peak value was measured,<sup>4</sup> and the display on the indicator was recorded.<sup>4</sup> The implant was then pro-rotated back in to its original position. Afterwards, one implant which was not manipulated was counter torqued and another one was transposed in each dog (Fig. 2A, Fig. 2B and Fig. 2C). Thus, one new implant (in the tibia that had only two implant) was inserted in each dog that would be assumed as the second control group (Fig. 1).

Week 17: After another eight weeks, during the fourth session, the eight-week group and second control group implants were counter torqued to lose by applying STW and BGI which recorded the peak force required to detach the implant. The implants were then returned to their pre counter torque position (Fig. 1, Fig. 2D and Fig. 2E).

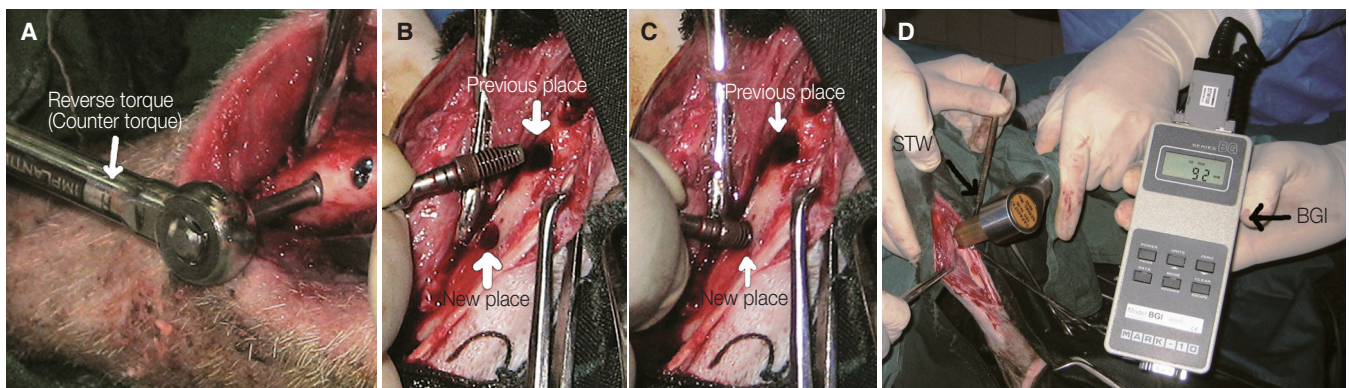
The data were analyzed with One-Sample Kolmogorov Smirnov and Leven. Thus, the groups were compared from the view of integration (Ncm) with Complete Randomized Block ANOVA. Statistical differences are indicated if  $P < .05$ .<sup>4</sup>

## RESULTS

There were 30 implants that were inserted in 5 dog tibiae. They were assigned to six groups for study: 1) first control;



**Fig. 1.** Timeline graphic of implants.



**Fig. 2.** Overview of surgical procedures in this study. (A) Performing counter torque the implant, (B) Exiting the implant of own cavity, (C) Transposing the implant to new cavity near the previous place immediately, (D) Reflecting periosteal flap at 17<sup>th</sup> week, (E) Applying STW and BGI for recording the peak force required to detach the implant.<sup>4</sup>

2) second control; 3) 1 WCT; 4) 1WT; 5) 8 WCT; and 6) 8 WT. All the manipulated and non-manipulated implants were osseointegrated. Two of the implants in dog #1 of the 8 WCT and 8 WT groups could not be liberated because the hexes of the implants were stripped. Therefore they were excluded and the second control in dog #1 was

excluded accordingly. During the third and fourth sessions of surgery a very thick bone was formed above the fixtures, they were carefully removed with trephine drills so that the implants were not injured.

The data of total 6 groups confirmed the normality with using One-Sample Kolmogorov with minimum even-

tuality of 0.796. Data variance equality was studied and assigned to three groups related to 1 week (first control - 1 WCT - 1 WT) with eventually 0.288 and in three groups related to eight week (second control - 8 WCT - 8 WT).

For comparing the quantity of osseointegration (Ncm), Completed Randomized Block ANOVA in three groups (first control - 1 WCT - 1 WT) was used. No statistically significant difference between the research groups ( $P=.052$ ) was shown. However the mean quantity of osseointegration revealed differences in the three groups (first control - 1 WCT - 1 WT) but they were not significant (Table 1). The mean is described in Fig. 3.

In order to compare the quantity of osseointegration (Ncm), Completed Randomized Block ANOVA in three groups (second control - 8 WCT - 8 WT) was used. No statistically significant difference between the study groups ( $P=.121$ ) was shown. But the mean quantity of osseointegration displayed differences in the three groups (second control - 8 WCT - 8 WT) but they were not significant (Table 2). The mean is described in Fig. 4.

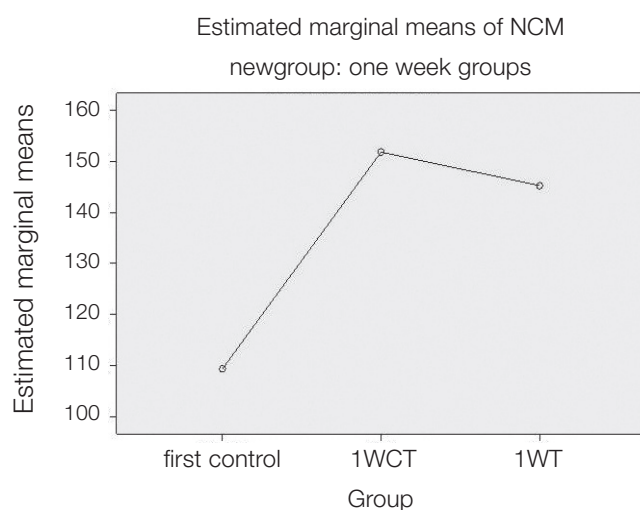
In this manner, No significant difference was discovered between the two study groups (first control - 1 WCT) with  $P=.90$ , two research groups (first control - 1 WT) with  $P=.116$ , two study groups (second control - 8 WCT) with

**Table 1.** Counter torque value (Ncm) between 3 experimental groups (first contro - 1 WCT - 1 WT)

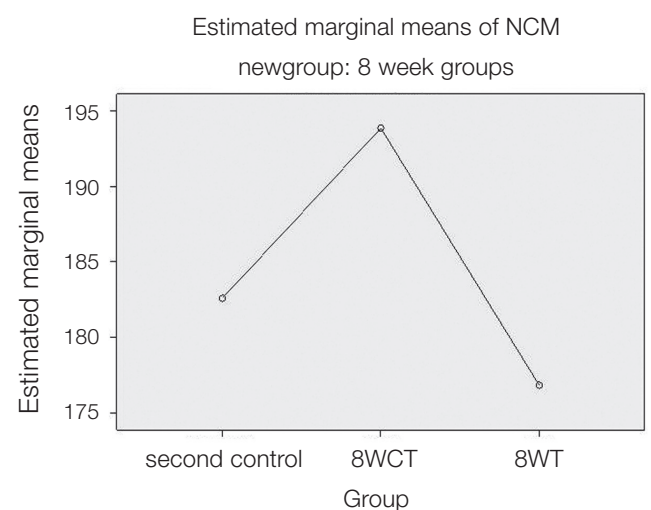
Group	N	Mean	Std. Deviation	95% confidence Interval for Mean		Minimum	Maximum
				Lower Bound	Upper Bound		
First Control	5	109.4	36.094	64.58	154.20	68	154
1 WCT	5	151.8	24.077	121.90	181.70	121	185
1 WT	5	145.2	24.284	115.05	175.35	122	184

**Table 2.** Counter torque value (Ncm) between 3 experimental groups (second control - 8 WCT - 8 WT)

Group	N	Mean	Std. Deviation	95% confidence Interval for Mean		Minimum	Maximum
				Lower Bound	Upper Bound		
Second Control	5	182.60	59.815	108.33	256.87	134	282
8 WCT	4	169.00	20.232	136.81	201.19	144	192
8 WT	4	152.00	18.815	122.06	181.94	127	167



**Fig. 3.** Counter torque value (Ncm) between 3 experimental groups (first control - 1 WCT - 1 WT).



**Fig. 4.** Counter torque value (Ncm) between 3 experimental groups (second control - 8 WCT - 8 WT).



$P=.145$ , two research groups (second control - 8 WT) with  $P=.536$ , two research groups (1 WCT - 8 WCT) with  $P=.234$ , two study groups (1 WT - 8 WT) with  $P=.592$ .

## DISCUSSION

The increased demand for early and immediate loading treatment plan in patients with implant supported dentures has led the clinicians to unscrew the implant's cover screw earlier. Regrettably, these installed implants may not have adequate primary stability. Therefore, they might rotate in the bone socket. This procedure is also likely to occur during abutment screw tightening. However, this eventuality could be expected because of not having adequate time for osseointegration.<sup>1,2,4</sup>

Bone healing around the implant depends on different factors. The stem cells which migrate there are only transformed into fibroblast as a result of micro movements then consequently fibrointegration occurs. So a parameter of assessing the attainment of osseointegration is a resistance to minimal 20 Ncm reverse torque for preventing micro-movement.<sup>4,12</sup> Many clinicians have tacitly accepted the counter torque test as a clinical indicator of successful integration.<sup>4,12,15</sup>

Currently, researches emphasize the formation of a strong bed for implant by a 'second callus'. Establishing and superimposing of this callus to the primary healing response will produce a stronger implant bed.<sup>4</sup> Another implication could be when implants were not inserted in an appropriate place or in close proximity to anatomic area such as maxillary sinus, inferior alveolar nerve and mental foramen. In these cases which force the implants to exit, the evaluation of the effect of utilizing counter torque is required.<sup>4,16</sup>

The present study is solely aimed at the clinical assessment of the resistance of implant following counter torque test in two intervals of one week and eight weeks. Definitely, this research should be confirmed by further histopathologic evaluation. The results of this study are supported by the findings in previous reports. In our study, reintegration is possible after counter torque test is carried-out on integrated implants. This outcome was achieved after eight weeks as healing time in eight-week rotation groups. The results of the present study also confirm the findings of Moriya *et al.*<sup>2</sup> while the counter torque is closer to implantation time, the result is more preferable and even higher than the control group. However, this was not observed in Lucente *et al.*<sup>4</sup> study. The samples of the Lucente's research were 11 humans therefore the number of the implants was statistically lower than this study.

The present study showed that implant reintegration is possible after counter torque test (physical dislocation of the implant from the healing bone) in integrated implant.<sup>4</sup> The result refers to the eight-week rotation groups. This is in accordance with findings of Ivanoff *et al.*<sup>1</sup> and Lucente *et al.* In the animal study of Morberg and Albrektsson,<sup>17</sup> who used rotational strain to the implant to break osseointegration,

subsequent integration was achieved.<sup>2</sup> Several studies have reported good prognosis of rotated implants finally functioned without any clinical difference from non-rotated implants.<sup>2,18-20</sup>

Transposition of the implant have been reported only in rare situations when the implant has been transposed with its surrounding bone to correct the implant position.<sup>21</sup> However in the present study, for the first time, implant transposition has been carried out without surrounded bone and, with/without detachment, the implant was separated from the adjacent bone and installed in the other cavity. A number of them were removed one week and the others eight weeks after the implantation. They were re-implanted in another site without any interruption.

The evaluation of the implants after eight weeks healing process revealed that the osseointegration has occurred. The mean value of the 1WT group (145/20 Ncm) has been increased in comparison with the control group (109/40 Ncm). On the other hand, the mean value of the 8 WT group (152 Ncm) has decreased in comparison with the control group (182/60). This is considered a suitable osseointegration while the implant surface is covered with some osseous particles and its uncontaminated transposition from one cavity to another will cause osseointegration.

Following the implantation, the clot is formed around the implant. This clot will then be organized after two days and the fibroendothelial cells and angiogenesis are observed. Also, because of different growth factors released, especially TGF (Transforming growth factor), there will be a proper condition for migrating and differentiating of cells that make up osseous matrix. An important factor in the first week is the high number of stem cells and osseous callus that are highly elastic. Also, due to the presence of stem cells, osteoid will be secreted and the calcification will take place. Therefore after the counter torque or transposition, the osseointegration will be achieved, proceeding the repair/healing phase. These values are higher than the control group. The important point in this time is that the implant surface is covered with GF (Growth Factor), stem cells, young connective tissue and primary osteoid. After eight weeks, the woven bone is formed at the site, the elastic callus is not present at this time, and if the counter torque or transposition is applied, due to the secondary pressure site, the resorption is also probable.<sup>22</sup> Even though following bone detachment some bone particles remain on the implant surface and cause new sites of early junctions.

Based on the Frost theory of the Regional acceleratory phenomenon (RAP),<sup>1,23-25</sup> which is one aspect of healing after operation, a noxious stimulus speeds up bone modeling and remodeling.<sup>1</sup> Therefore one can hypothesize that bone detachment from the implant as a result of counter torque or transposition leads to the activation of the cytokines (e.g., TGF $\beta$ 1, aF $\beta$ F, bF $\beta$ F and BMP2,7), which is the same mechanism as in any other traumatic event in the bone.<sup>4,26-41</sup> According to the mechanism of the action described by Davies,<sup>4,16</sup> it seems that the areas that did not have adherent bone were likely to be saturated with blood

released from disrupted local vessels after the counter torque or transposition.<sup>4</sup> In other words the reintegration success in these implants may be a function of the cellular processes in which the surfaces attach and secure the blood clot,<sup>4</sup> anchoring fibrin that provides a pathway for the osteoblasts to migrate to the surface of the implant and initiate de novo bone formation.<sup>4</sup> Therefore, at final evaluation, the counter torque force also had to overcome the resistance provided by newly formed interfacial bone.<sup>4,16,42</sup>

This research showed that if the implant was counter torqued or transposed after one or eight weeks following implantation, osseointegration was achieved after the healing period.

## CONCLUSION

The conclusions of this study are those that follow:

After the counter torque process, one week or eight weeks following the implantation, osseointegration was achieved. After transposing the implant, one week or eight weeks following the implantation, osseointegration was achieved. Comparing the one week and eight week intervals, the one week would result in a stronger osseointegration, when comparing to the values with the control group. Comparing the one week and eight week intervals, the implant transposing after one week is suggested due to its better results.

## REFERENCES

- Ivanoff CJ, Sennerby L, Lekholm U. Reintegration of mobilized titanium implants. An experimental study in rabbit tibia. *Int J Oral Maxillofac Surg* 1997;26:310-5.
- Moriya K, Maruo Y, Minagi S. Does rotational strain at screw tightening affect the attainment or maintenance of osseointegration? *Clin Oral Implants Res* 2006;17:451-8.
- Lang LA, May KB, Wang RF. The effect of the use of a counter-torque device on the abutment-implant complex. *J Prosthet Dent* 1999;81:411-7.
- Lucente J, Galante J, Trisi P, Kenealy JN. Reintegration success of osseotite implants after intentional countertorque liberation in the endentulous human mandible. *Implant Dent* 2006;15:178-85.
- Albrektsson T, Zarb G, Worthington P, Eriksson AR. The long-term efficacy of currently used dental implants: a review and proposed criteria of success. *Int J Oral Maxillofac Implants* 1986;1:11-25.
- Smith DE, Zarb GA. Criteria for success of osseointegrated endosseous implants. *J Prosthet Dent* 1989;62:567-72.
- Misch CE, Perel ML, Wang HL, Sammartino G, Galindo-Moreno P, Trisi P, Steigmann M, Rebaudi A, Palti A, Pikos MA, Schwartz-Arad D, Choukroun J, Gutierrez-Perez JL, Marenzi G, Valavanis DK. Implant success, survival, and failure: the International Congress of Oral Implantologists (ICOI) Pisa Consensus Conference. *Implant Dent* 2008;17:5-15.
- Sakka S, Coulthard P. Implant failure: etiology and complications. *Med Oral Patol Oral Cir Bucal* 2011;16:e42-4.
- Lekholm U, Adell R, Brånemark PI. Complications. In: Brånemark PI, Zarb GA, Albrektsson T, editors. *Tissue-integrated prostheses: Osseointegration in clinical dentistry*. Chicago; Quintessence; 1985. p. 233-40.
- Sennerby L, Meredith N. Implant stability measurements using resonance frequency analysis: biological and biomechanical aspects and clinical implications. *Periodontol* 2000 2008; 47:51-66.
- Renvert S, Polyzois I, Maguire R. Re-osseointegration on previously contaminated surfaces: a systematic review. *Clin Oral Implants Res* 2009;20:216-27.
- Friberg B, Jemt T, Lekholm U. Early failures in 4,641 consecutively placed Brånemark dental implants: a study from stage 1 surgery to the connection of completed prostheses. *Int J Oral Maxillofac Implants* 1991;6:142-6.
- Sullivan DY, Sherwood RL, Collins TA, Krogh PH. The reverse-torque test: a clinical report. *Int J Oral Maxillofac Implants* 1996;11:179-85.
- Turner AS, McIlwraith CW, Hull BL. *Techniques in large animal surgery*, 2nd ed. Philadelphia; Lea & Febiger; 1989. p. 87-9.
- Carvalho CM, Carvalho LF, Costa LJ, Sa MJ, Figueiredo CR, Azevedo AS. Titanium implants: a removal torque study in osteopenic rabbits. *Indian J Dent Res* 2010;21:349-52.
- Davies JE. Mechanisms of endosseous integration. *Int J Prosthodont* 1998;11:391-401.
- Morberg P, Albrektsson T. A histomorphometric and removal torque analysis of c.p. titanium implants inserted in reamed bone beds with or without acrylic cement. *J Mat Sci Mat Med* 1992;3:170-4.
- Roccuzzo M, Bunino M, Prioglio F, Bianchi SD. Early loading of sandblasted and acid-etched (SLA) implants: a prospective split-mouth comparative study. *Clin Oral Implants Res* 2001;12:572-8.
- Cochran DL, Buser D, ten Bruggenkate CM, Weingart D, Taylor TM, Bernard JP, Peters F, Simpson JP. The use of reduced healing times on ITI implants with a sandblasted and acid-etched (SLA) surface: early results from clinical trials on ITI SLA implants. *Clin Oral Implants Res* 2002;13:144-53.
- Salvi GE, Gallini G, Lang NP. Early loading (2 or 6 weeks) of sandblasted and acid-etched (SLA) ITI implants in the posterior mandible. A 1-year randomized controlled clinical trial. *Clin Oral Implants Res* 2004;15:142-9.
- Poggio CE, Salvato A. Implant repositioning for esthetic reasons: a clinical report. *J Prosthet Dent* 2001;86:126-9.
- Lindhe J, Lang NP, Karring T. *Clinical periodontology and implant dentistry*. 4th ed. China: Blackwell; 2003. p. 866-74.
- Misch CE. *Dental Implant prosthodontics* Misch. China: Mosby Elsevier; 2005. p. 340.
- Frost HM. *The regional acceleratory phenomenon. Intermediary organization of the skeleton*. Boca Raton, FL, USA: CRC Press; 1986. p. 109-29.
- Lundgren D, Lundgren AK, Sennerby L. The effect of mechanical intervention on jaw bone density. *Clin Oral Implants Res* 1995;6:54-9.
- Joyce ME, Jingushi S, Bolander ME. Transforming growth

- factor-beta in the regulation of fracture repair. *Orthop Clin North Am* 1990;21:199-209.
27. Bolander ME. Regulation of fracture repair by growth factors. *Proc Soc Exp Biol Med* 1992;200:165-70.
  28. Bourque WT, Gross M, Hall BK. Expression of four growth factors during fracture repair. *Int J Dev Biol* 1993;37:573-9.
  29. Sandberg MM, Aro HT, Vuorio EI. Gene expression during bone repair. *Clin Orthop Relat Res* 1993;289:292-312.
  30. Bostrom MP, Lane JM, Berberian WS, Missri AA, Tomin E, Weiland A, Doty SB, Glaser D, Rosen VM. Immunolocalization and expression of bone morphogenetic proteins 2 and 4 in fracture healing. *J Orthop Res* 1995;13:357-67.
  31. Onishi T, Ishidou Y, Nagamine T, Yone K, Imamura T, Kato M, Sampath TK, ten Dijke P, Sakou T. Distinct and overlapping patterns of localization of bone morphogenetic protein (BMP) family members and a BMP type II receptor during fracture healing in rats. *Bone*. 1998;22:605-12.
  32. Sakou T. Bone morphogenetic proteins: from basic studies to clinical approaches. *Bone* 1998;22:591-603.
  33. Trippel SB. Potential role of insulinlike growth factors in fracture healing. *Clin Orthop Relat Res* 1998;(355 Suppl): S301-13.
  34. Tatsuyama K, Maezawa Y, Baba H, Imamura Y, Fukuda M. Expression of various growth factors for cell proliferation and cytodifferentiation during fracture repair of bone. *Eur J Histochem* 2000;44:269-78.
  35. Nakajima A, Nakajima F, Shimizu S, Ogasawara A, Wanaka A, Moriya H, Einhorn TA, Yamazaki M. Spatial and temporal gene expression for fibroblast growth factor type I receptor (FGFR1) during fracture healing in the rat. *Bone* 2001;29: 458-66.
  36. Rundle CH, Miyakoshi N, Ramirez E, Wergedal JE, Lau KH, Baylink DJ. Expression of the fibroblast growth factor receptor genes in fracture repair. *Clin Orthop Relat Res* 2002;403: 253-63.
  37. Yu Y, Yang JL, Chapman-Sheath PJ, Walsh WR. TGF-beta, BMPs, and their signal transducing mediators, Smads, in rat fracture healing. *J Biomed Mater Res* 2002;60:392-7.
  38. Cho TJ, Gerstenfeld LC, Einhorn TA. Differential temporal expression of members of the transforming growth factor beta superfamily during murine fracture healing. *J Bone Miner Res* 2002;17:513-20.
  39. Ai-Aql ZS, Alagl AS, Graves DT, Gerstenfeld LC, Einhorn TA. Molecular mechanisms controlling bone formation during fracture healing and distraction osteogenesis. *J Dent Res* 2008;87:107-18.
  40. Sarahrudi K, Thomas A, Mousavi M, Kaiser G, Köttstorfer J, Kecht M, Hajdu S, Aharinejad S. Elevated transforming growth factor-beta 1 (TGF- $\beta$ 1) levels in human fracture healing. *Injury* 2011;42:833-7.
  41. Schmid GJ, Kobayashi C, Sandell LJ, Ornitz DM. Fibroblast growth factor expression during skeletal fracture healing in mice. *Dev Dyn* 2009;238:766-74.
  42. Davies JE. Understanding peri-implant endosseous healing. *J Dent Educ* 2003;67:932-49.