



Implant overdenture impressions using a dynamic impression concept

Byung-Kil Lee, Sang-Hun Park, Cheong-Hee Lee, Jin-Hyun Cho*

Department of Prosthodontics, School of Dentistry, Kyungpook National University, Daegu, Republic of Korea

A dynamic impression is a functional impression that records the functional movement of the patient's own muscle and muscle attachment. This process reduces the number of random factors. This article describes a method for making a special tray using a dynamic impression concept that was made from provisional dentures used for implant healing. The individual tray is used to make a wash-impression to record the features of the mucosa in detail. The main advantage of this technique is that it provides a functional relationship of the implant components to the supporting tissues without overextension because provisional denture had been used for 2 months and the border length of individual tray was nearly the same as that of provisional denture. The delivery of the prosthesis constructed using this impression technique is time-saving because there is no need for border molding and there are fewer post-insertion appliance adjustments. [*J Adv Prosthodont* 2014;6:66-70]

KEY WORDS: Implant overdenture; Dynamic impression; Tissue conditioner; Functional impression

INTRODUCTION

Bilateral distal extension removable partial denture (RPDs) (Kennedy Class I) and implant-retained overdentures have some similarities, such as force direction and distribution.¹ The occlusal forces on RPDs must be distributed uniformly to the supporting teeth and residual ridges. Similarly, in implant overdentures, equitable load sharing between the implants and mucosa might be related to the selected impression technique because of the difference in resilience.^{2,3} A range of functional impression techniques have been attempted to record the functional form of the edentulous ridge.^{2,4,5} The functional impression techniques can

be divided into two categories: (a) physiological techniques and (b) selective pressure technique. Physiological impression techniques record the edentulous ridge in its functional form by placing a load on the impression tray during the impression procedure (McLean-Hindels method, functional reline impression technique, and fluid wax method). The selective pressure impression attempts to direct more force to those portions of the ridge able to absorb stress and to protect the areas of the ridge least able to absorb stress. This is accomplished by relieving the tray in some areas with wax while allowing the impression tray to contact the ridge in other areas. Greater soft tissue displacement will occur in areas where relief is not provided.⁶ One of the functional impression methods is a dynamic impression with a tissue conditioner. These have been used principally for the conditioning of abused soft tissues underlying ill-fitting full dentures because of the introduction of tissue conditioners. In addition, these tissue conditioners have been reported to be suitable as functional impression materials.⁷ Their efficacy as reconditioners of abused tissues has been well established.⁸ The dynamic impression is a method that determines the size and form of movable oral tissue using a plastic impression material.⁹ The difference between dynamic impression and other impression methods are as follows. The other methods impress to record the oral tissues in the static, partial active, and pressed states according to impression concepts (e.g. mucostatic, definitive pressure, selective pressure impression technique) and are one-step

Corresponding author:
Jin-Hyun Cho

Department of Prosthodontics, School of Dentistry, Kyungpook National University, 2175, Dalgubeoldae-ro, Jung-Gu, Daegu, Republic of Korea
Tel. 82536007675; e-mail, prosth95@knu.ac.kr
Received May 7, 2013 / Last Revision November 1, 2013 / Accepted November 5, 2013

© 2014 The Korean Academy of Prosthodontics
This is an Open Access article distributed under the terms of the Creative Commons Attribution Non-Commercial License (<http://creativecommons.org/licenses/by-nc/3.0>) which permits unrestricted non-commercial use, distribution, and reproduction in any medium, provided the original work is properly cited.

This work was supported by Biomedical Research Institute Grant, Kyungpook National University Hospital (2012).
This research was supported by Kyungpook National University Research Fund (2012).

pick-up impression technique that uses border molding and tray holes.

In contrast, a dynamic impression is a functional impression that records the functional movement of the patient's own muscle and muscle attachment. This method reduces the number of random factors. This article describes a method for making a special tray using a dynamic impression concept that was made from provisional dentures used for implant healing. The individual tray is used to make a wash-impression to record the features of the mucosa in detail.

CASE REPORT

A male patient aged 57 years visited a clinic with the chief complaint of a common consultation on dentures. He showed a combination syndrome-like appearance with overall caries and a serious periodontal status of the remaining teeth at initial examination (Fig. 1). The panoramic view revealed severe bone resorption on the mandibular molar area and a combination syndrome-like appearance on the mandibular anterior area (Fig. 2). First, the teeth with a poor prognosis (#11, 14, 24, 31, 32, 41, 42)

were extracted while a periodontal flap surgery was conducted on the maxilla. Subsequently, the Kennedy Class II RPD was planned for the maxilla, and a four-implant-tissue supported bar overdenture was planned for the mandible. Four implants (Osstem, Seoul, Korea) were placed in the interforaminal area (Fig. 3B), in which alveoloplasty was performed first (Fig. 3A). All implants were 4.1 mm in diameter and had an anodized surface. A non-submerged, single-stage placement technique was performed according to the standard surgical procedure. Three temporary implants (Osstem, Seoul, Korea) were placed between the primary implants and the areas onto which the temporary fixed partial prosthesis was placed for aesthetic problems and no loading on the primary implants (Fig. 3B). One month later, a provisional denture was fabricated. Three months later, a tissue conditioner (Coe-Comfort; Coe Laboratories Inc., Chicago, USA) was used to take a dynamic impression with the provisional denture on the mandible (Fig. 4A). The following day, the tissue surface of the provisional denture was poured with yellow stone (Hi-Koseton, Maruishi, Japan) and the stone cast was removed. The stone cast was in accordance with the dynamic impression surface of the provisional denture (Fig.

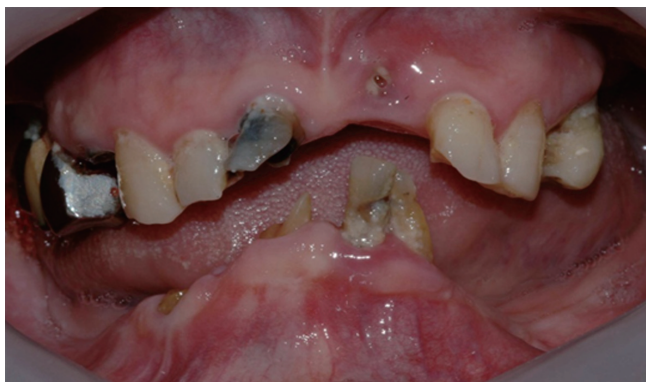

Fig. 1. Initial photo - combination syndrome like appearance; mandibular anterior region was elevated because of no opposing dentition.

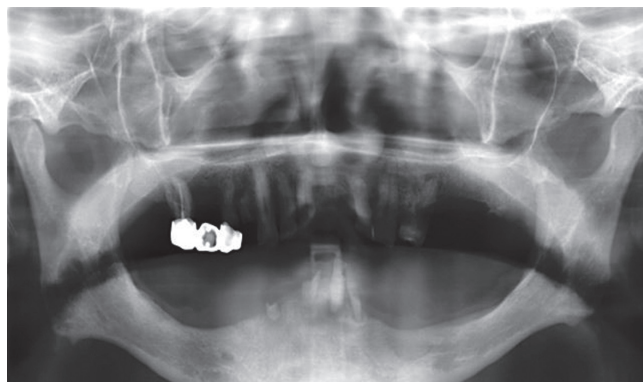


Fig. 2. Initial Panoramic view; severe periodontitis and severe bone resorption on the mandibular molar area.

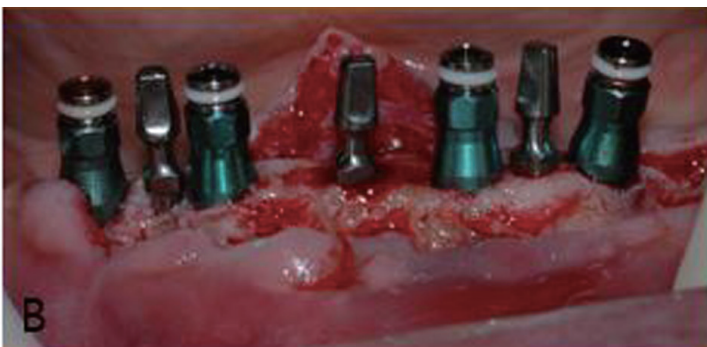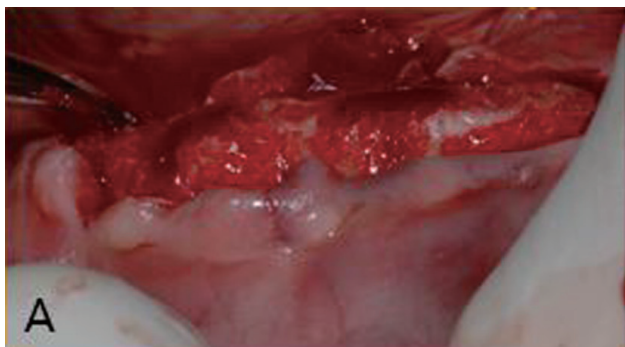


Fig. 3. (A) Mandibular alveoloplasty, (B) Four implants were placed on interforaminal area and 3 temporary implants were placed for provisional fixed prosthesis.

4B). Multiple layers of baseplate wax (Modeling wax; Kim's International Inc, Seoul, Korea) were adapted on the abutments to maintain space for the elastomeric impression material (Fig. 5A). The individual tray (Ostron 100; GC Corporation, Tokyo, Japan) was manufactured based on the cast to the full length of the border and trimmed with a denture bur to make the denture border 0.5 mm shorter and smooth the border. An individual tray adhesive was pasted with tray adhesive (Adhesive; GC Corporation,

Tokyo, Japan) (Fig. 5B). An implant impression was taken without border molding - wash impressions with polyvinyl siloxane impression material (Aquasil Ultra LF; Dentsply Caulk, Milford, USA) (Fig. 6). The bar overdenture was fabricated with a Haderbar (Sterngold, Attleboro, USA) and ERA attachment system (Sterngold, Attleboro, USA) (Fig. 7). The overdenture was delivered (Fig. 8) and the 5 years follow up result was favorable (Fig. 8B).

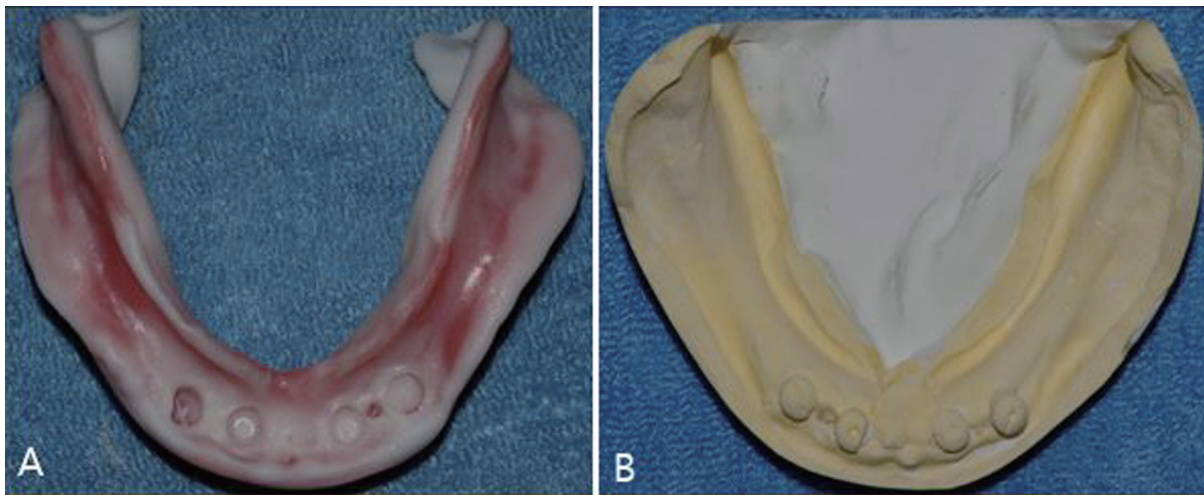


Fig. 4. (A) Tissue conditioning for provisional dentures, (B) The cast was made by pouring improved stone on the tissue conditioner of the impression surface.

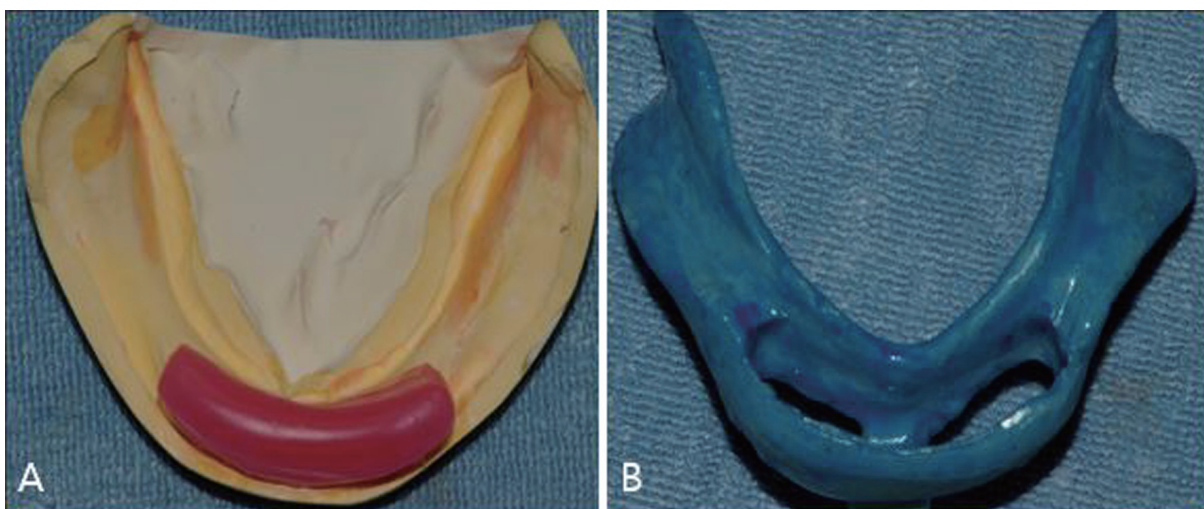


Fig. 5. (A) Block out for implant impression coping and undercut area, (B) Individual tray fabrication and adhesive was pasted.

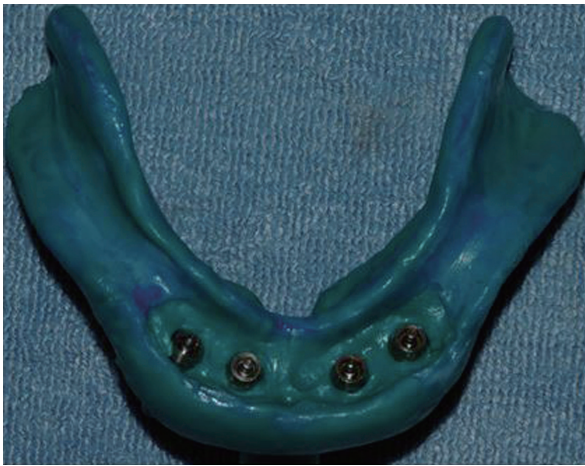

Fig. 6. Pick up impression (wash impression concept).

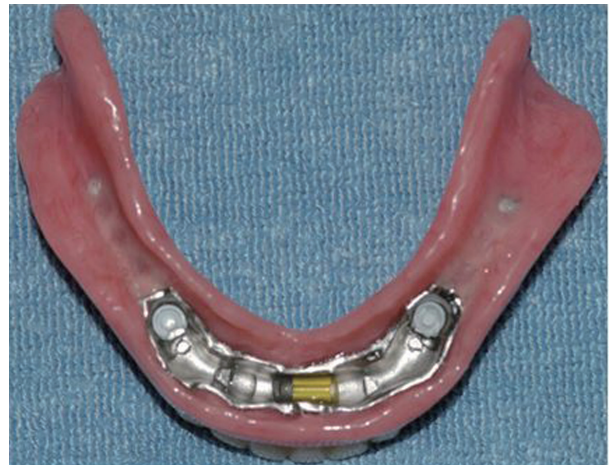

Fig. 7. Intaglio surface of the cured denture.

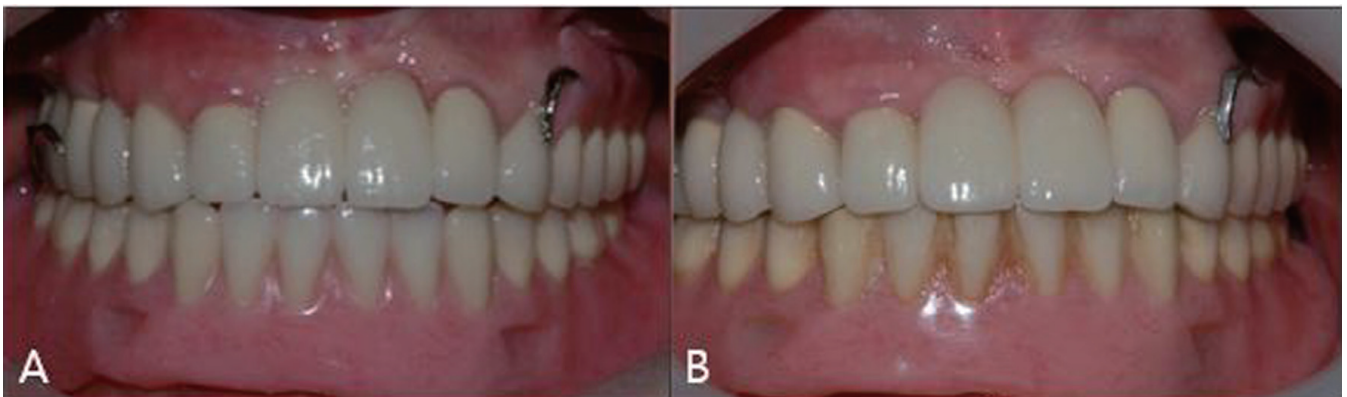


Fig. 8. (A) Denture delivery, (B) Follow up photo (5 years).

DISCUSSION

Recently functional impression technique is advocated in implant overdenture impression. Elsyad *et al.* reported that a definite pressure impression technique for an implant-retained mandibular overdenture is associated with minimal denture deformation during function when compared with the mucostatic and selective pressure techniques.¹⁰ Another form of functional impression is a dynamic impression technique. The advantages of dynamic impressions are: (1) avoidance of the dislocating effect of the muscles on improperly-formed denture borders, and (2) complete utilization of the potential active and passive tissue fixation of the denture. To take a dynamic impression, the patient is asked to perform swallowing, sucking and protruding the lips while the impression material has plasticity. At this time, the qualifications that the impression material must have are follows: (1) dimensional stability after removing from the mouth, (2) reproduction in detail, and (3) harmony with gypsum products. Otherwise, the micro surface

roughness of tissue conditioner can be the disadvantage of dynamic impression with tissue conditioner. When the existing provisional denture and tissue conditioner are used to take a dynamic impression and the dynamic impression surface of denture is applied to the fabrication of an individual tray. After that, pick-up impression (wash impression concept in edentulous ridge) is taken by without border molding that removes micro surface roughness. This impression method is not technique sensitive for providing a perfect border without border molding, only using polyvinyl siloxane impression materials for wash impression. In addition, when border molding is performed, it takes a long time to record a precise border extension because the patients who are planned to receive an implant overdenture on the mandible often show severe alveolar bone loss. Nevertheless, the use of such a dynamic impression will enable making an impression that is extended precisely. Consequently, such a method will allow decreased chair time in border molding procedure and impression taking procedure without overextension.

CONCLUSION

A method for making a special tray using a dynamic impression concept that was made from provisional dentures used for implant healing was useful method because there was no need for border molding and it was also time-saving in impression taking procedure without overextension.

REFERENCES

1. Chen IC, Brudvik JS, Mancl LA, Rubenstein JE, Chitswe K, Raigrodski AJ. Freedom of rotation of selected overdenture attachments: an in vitro study. *J Prosthet Dent* 2011;106:78-86.
2. Uludag B. An alternate pressure-free functional impression technique for implant-retained overdentures. *J Oral Implantol* 2010;36:205-7.
3. Uludag B, Ozturk O, Celik G. Alternate functional impression technique for implant-retained overdentures. *J Prosthet Dent* 2007;97:242-3.
4. Uludag B, Cogalan K, Polat S. An alternative impression technique for implant-retained overdentures with locator attachments. *J Oral Implantol* 2010;36:451-3.
5. Jannesar S, Siadat H, Alikhasi M. A dual impression technique for implant overdentures. *J Prosthodont* 2007;16:327-9.
6. Cho GC, Landesman M, Adomian JG. An alternative altered cast technique for a distal extension removable partial denture. *J Calif Dent Assoc* 1997;25:377-80.
7. Razek MK. Assessment of tissue conditioning materials for functional impressions. *J Prosthet Dent* 1979;42:376-80.
8. McCarthy JA, Moser JB. Tissue conditioners as functional impression materials. *J Oral Rehabil* 1978;5:357-64.
9. Wilson HJ, Tomlin HR, Osborne J. The assessment of temporary soft materials used in prosthetics. *Br Dent J* 1969;126:303-6.
10. Elsyad MA, El-Waseef FA, Al-Mahdy YF, Fouad MM. A comparison of mandibular denture base deformation with different impression techniques for implant overdentures. *Clin Oral Implants Res* 2013;24:127-33.