

A simplified chair-side remount technique using customized mounting platforms

Mamta Devendrakumar Chauhan*, BDS, Shankar Pandharinath Dange, MDS, Arun Narayan Khalikar, MDS, Smita Padmakar Vaidya, MDS

Department of Prosthodontics, Government Dental College & Hospital, Aurangabad, India

Correct occlusal relationships are part of the successful prosthetic treatment for edentulous patients. Fabrication of complete dentures comprises of clinical and laboratory procedures that should be executed accurately for achieving success with fabricated dentures. Errors occurring during the clinical and laboratory procedures of a denture may subsequently lead to the occlusal errors in the final prosthesis. These occlusal errors can be corrected in two ways: i) in patient's mouth ii) by recording new centric relation and remounting dentures on an articulator. The latter method is more feasible because the mobility of denture base on the mucosa in oral cavity does not permit the identification of premature contacts in centric occlusion and tooth guided eccentric excursions. This article describes a modest and effective clinical chair-side remount procedure using customized mounting platforms. [J Adv Prosthodont 2012;4:170-3]

KEY WORDS: Occlusal errors; Occlusal adjustments; Clinical remount; Customized mounting platforms

INTRODUCTION

Occlusion established during try-in stage is subject to change because of inaccuracies in mounting procedures, distortion of the recording bases, unfastened mounting rings, or processing errors. Minor faults can be corrected by selective grinding with dentures in patient's mouth, if a split cast remount procedure was used immediately after the dentures were processed.¹⁻⁶ However, a general dental practice survey revealed that less than 5% of dentists use the split cast procedure to rectify the errors of processing.⁷ Besides, the displaceable oral soft tissues and saliva also interferes with selective adjustment procedure. For these reasons, clinical remount is preferred by few practitioners.⁸ The clinical remount is an indispensable step in the fabrication of complete dentures and it is used to ascertain favorable occlusion.⁸⁻¹⁷

Many practitioners consider that the dentures should be permitted to "settle in" before occlusal corrections are performed.¹⁸⁻²³ With this philosophy, however, the dentist fails to control the change in occlusion because the denture bases will change position to accommodate occlusal interferences, leading to irregular pressure on the underlying soft and hard tissues. Intraoral occlusal adjustment is difficult because of the move-

ment of denture bases over resilient ridges and uneven tissue contact. Such corrections are less accurate than mounting the finished dentures in an articulator by means of a centric relation record and subsequent elimination of interceptive contacts. Routine remounting of dentures requires making remount casts or blocking out undercuts and then mounting with quick-setting plaster.^{4,24}

The purpose of this article was to provide a simplified remounting procedure that used customized mounting platforms (CMP) and has these advantages: (1) remount casts are not fabricated separately for remounting complete dentures; (2) the mandibular denture can be remounted quickly with a new centric relation record, in case of incorrect centric relation record; (3) blocking out undercuts from the tissue surface of denture is not necessary; (4) mounting can be performed at chair-side with minimal mess and; (5) the putty impression material can be conserved as a record to be used in successive appointments if needed. The putty material is costly; however, the procedure is expedient and little material is required because maximum expanse in the articulator will be occupied by the maxillary and mandibular CMPs and the edentulous ridges fabricated in acrylic resin.

Corresponding author: Mamta Devendrakumar Chauhan
Department of Prosthodontics, Government Dental College & Hospital,
Aurangabad-431001, Maharashtra, India

Tel. 919049411365; e-mail, drmyself5@gmail.com

Received September 15, 2011 / Last Revision December 29, 2011 / Accepted January 1, 2012

© 2012 The Korean Academy of Prosthodontics

This is an Open Access article distributed under the terms of the Creative Commons Attribution Non-Commercial License (<http://creativecommons.org/licenses/by-nc/3.0>) which permits unrestricted non-commercial use, distribution, and reproduction in any medium, provided the original work is properly cited.

PROCEDURE

This clinical remount technique utilizes maxillary and mandibular CMPs that are fabricated over mounting plates of articulator. They are made beforehand and used when required.

Fabrication of CMPs

1. Enfold boxing wax (Deepti Dental Products, Ratnagiri, India) around the outside edge of the maxillary and mandibular mounting plates to form diverging housing for holding the dental plaster (Fig. 1).
2. Reduce the boxing wax for the maxillary and mandibular mounting plates such that the diameter at the opening is 6.5 cm.
3. Similarly, trim the height of maxillary boxing wax at 2.5 cm and that of mandibular boxing wax at 2 cm.
4. Pour a mix of dental plaster (Kalstone, Kalabhai Karson, Mumbai, India) to fill both the divergent cylinders.
5. Allow the dental plaster to set and remove the boxing wax (Fig. 2).
6. Carve a horse-shoe shaped groove on the flat surfaces of both the divergent cylinders thus formed (Fig. 3).

7. Form a mix of self cure acrylic resin (DP cold cure, Dental Products of India, Mumbai, India) into two spoons and place over the grooves of both the maxillary and mandibular divergent cylinders to form U-shaped positive replica of edentulous ridges. Adjust the vertical height of the ridges to 5 to 6 mm.
8. Trim these acrylic edentulous ridges with fissure bur to make buccal and lingual undercuts that will provide port for the putty impression material during subsequent mounting of the dentures (Fig. 4).
9. Finish and polish both the customized mounting platforms.

Chair-side remounting of the dentures

1. Check the intaglio surface of each denture in the mouth with pressure-indicating pastes or waxes and make the needed adjustments.^{3,4}
2. Make a centric relation inter-occlusal record with a soft medium such as warm Aluwax (Bite Registration Wax, DupleP Global, Mumbai, India) to confirm closure without contact of the denture teeth or bases.⁴
3. Attach the maxillary and mandibular CMPs in the articulator (Fig. 5).




Fig. 1. Boxed mounting plate.



Fig. 3. Horse-shoe shaped grooves.




Fig. 2. Dental plaster poured in boxed mounting plates.

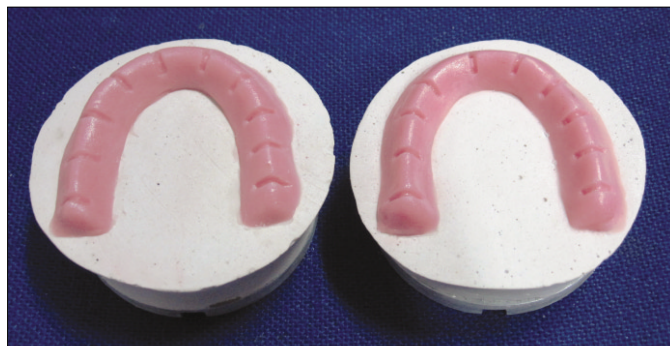

Fig. 4. Maxillary and mandibular customized mounting platforms (CMPs) with acrylic resin edentulous ridges.

4. Place the putty impression material (Zetaplus, Zhermack, Rovigo, Italy) in the form of a U-shaped roll over the mandibular acrylic resin edentulous ridge on the CMP and position the mandibular denture on it.
5. Secure the maxillary denture over mandibular denture with the help of the centric interocclusal record in aluwax, place the putty material in the denture in the region of alveolar

ridge, and close the upper member of the articulator into the putty material.

6. After the putty impression material has set, open the articulator and remove the interocclusal record (Fig. 6).
7. The putty material serves as remount casts (Fig. 7).
8. Close the denture onto articulating paper (PD, Vevey, Switzerland) and adjust the occlusion (Fig. 8).




Fig. 5. Customized mounting platforms secured on articulator.



Fig. 7. Remount casts obtained in putty impression material.

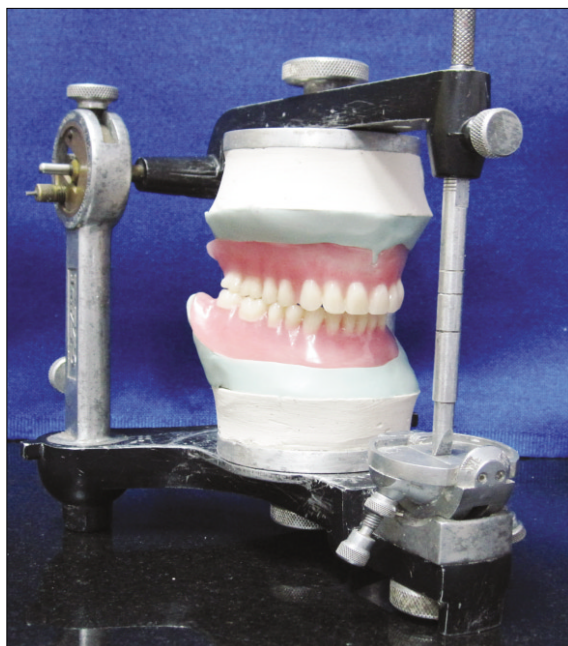

Fig. 6. Mounting done with centric inter-occlusal record.




Fig. 8. Articulating paper used to correct occlusal errors.

DISCUSSION

Correct occlusal relationships are a part of the success in prosthetic treatment for edentulous patients with complete dentures. A clinical remount procedure of the finished dentures is a constituent part of prosthetic patient treatment in practice of complete dentures. It corrects the clinical and laboratory inaccuracies in occlusion and establishes an occlusion that ensures even pressure in all areas of the arch. The clinical remount also maintains the stability of dentures when the mandible is in centric relation position. The clinical remount technique described in this article has utilized a Hanau H2 semi-adjustable articulator. The dimensions of CMPs are based on the authors' experience that making a 2.5 cm high maxillary CMP and a 2 cm high mandibular CMP leaves sufficient inter-ridge space on the articulator to accommodate almost any denture without interference. The remount casts obtained in putty impression material compensates for the setting expansion occurring with plaster remount casts. The remount platforms can be fabricated in advance, thereby saving the chair-side time of both the patient and the dentist. The only limitation of this technique is that the cases with decreased inter-ridge distance might require more amount of putty material for fabrication of the remount casts, thereby increasing the cost factor. For such cases, the height of the edentulous ridges in acrylic resin can be increased to compensate for decreased inter-ridge distance.

REFERENCES

1. Kyes FM. The laboratory's role in successful full dentures. *J Prosthet Dent*. 1951;1:196-203.
2. Gehl DH, Dresen OM. Complete denture prosthesis. 4th ed. Philadelphia; PA; WB Saunders; 1958. p. 327-9.
3. Heartwell CM, Rohn AO. Syllabus of complete dentures. 4th ed. Philadelphia; PA; Lea & Febiger; 1968. p. 324-34.
4. Zarb GA, Bolender CL. Prosthodontic treatment for edentulous patients. 12th ed. St. Louis: CV Mosby; 2004. p. 389-426.
5. Sherman H. Denture insertion. *Dent Clin North Am* 1977;21:339-57.
6. Sidhaye AB, Master SB. Efficacy of remount procedures using masticatory performance tests. *J Prosthet Dent* 1979;41:129-33.
7. Harrison A, Huggett R, Murphy WM. Complete denture construction in general dental practice: an update of the 1970 survey. *Br Dent J* 1990;169:159-63.
8. Firtell DN, Finzen FC, Holmes JB. The effect of clinical remount procedures on the comfort and success of complete dentures. *J Prosthet Dent* 1987;57:53-7.
9. Friedman S. A comparative analysis of conflicting factors in the selection of the occlusal pattern for edentulous patients. *J Prosthet Dent* 1964;14:30-44.
10. Kotwal KR. The need to use an arbitrary face-bow when remounting complete dentures with interocclusal records. *J Prosthet Dent* 1979;42:224-7.
11. Holt JE. Research on remounting procedures. *J Prosthet Dent* 1977;38:338-41.
12. Lytle RB. Complete denture construction based on a study of the deformation of the underlying soft tissues. *J Prosthet Dent* 1959;9:539-51.
13. Woelfel JB. Processing complete dentures. *Dent Clin North Am* 1977;21:329-38.
14. Friedman S. An effective pattern of occlusion in complete artificial dentures. *N Y State Dent J* 1951;17:78-88.
15. Brudvik JS, Wormley JH. A method of developing mono-plane occlusions. *J Prosthet Dent* 1968;19:573-80.
16. Hall WA Jr. Important factors in adequate denture occlusion. *J Prosthet Dent* 1958;8:764-75.
17. Ortman HR. Complete denture occlusion. *Dent Clin North Am* 1977;21:299-320.
18. Jones PM. Eleven aids for better complete dentures. *J Prosthet Dent* 1962;12:220-8.
19. Young HA. Denture insertion. *J Am Dent Assoc* 1962;64:505-11.
20. Jankelson B. Adjustment of dentures at time of insertion and alterations to compensate for tissue change. *J Am Dent Assoc* 1962;64:521-31.
21. Gronas DG, Stout CJ. Lineal occlusion concepts for complete dentures. *J Prosthet Dent* 1974;32:122-9.
22. Samant A, McDermott I, Cinotti WR. Delivery complete dentures: preventing problems after insertion. *Gen Dent* 1984;32:229-31.
23. Watt DM, MacGregor AR. Designing complete dentures. 2nd ed. Bristol, England: Wright; 1986. p. 193-5.
24. Ansari IH. A procedure for making remount casts without blocking out undercuts. *J Prosthet Dent* 1993;70:482.