



CASE REPORT

# Ticagrelor washout bridged with GPIIb/IIIa inhibitor infusion to facilitate surgical care following placement of pipeline flow diverters: a case report

Aaron Zweig, BS<sup>1</sup>; James S Stanley, PharmD<sup>2</sup>; Ronak Patel, MD<sup>3</sup>;  
John Agola, MD<sup>4</sup>; Michael R Halstead, MD, MPH<sup>3,5</sup>

<sup>1</sup>School of Medicine, Eastern Virginia Medical School, Norfolk, VA, USA

<sup>2</sup>Department of Pharmacy, Sentara Norfolk General Hospital, Norfolk, VA, USA

<sup>3</sup>Division of Neurocritical Care, Sentara Pulmonary, Critical Care, and Sleep Specialists, Sentara Norfolk General Hospital, Norfolk, VA, USA

<sup>4</sup>Division of Interventional Neuroradiology, Medical Center Radiologists, Sentara Norfolk General Hospital, Norfolk, VA, USA

<sup>5</sup>Department of Neurology, Eastern Virginia Medical School, Norfolk, VA, USA

Received: April 27, 2023

Revised: June 7, 2023

Accepted: June 12, 2023

Corresponding Author:

Aaron Zweig, BS

School of Medicine, Eastern Virginia  
Medical School, 825 Fairfax Ave,  
Norfolk, VA 23507, USA

E-mail: [azweig1@terpmail.umd.edu](mailto:azweig1@terpmail.umd.edu)

**Background:** Pipeline flow diverters (PFDs) are becoming increasingly common. Antiplatelet medication is required to minimize periprocedural ischemic events. Short-acting GPIIb/IIIa inhibitors are frequently administered intraprocedurally; however, the role of these agents in postprocedural PFD management in the neurocritical care unit (NCCU) has been overlooked.

**Case Report:** A patient with an unruptured internal carotid artery aneurysm presented for PFD placement. PFD placement was complicated by post-procedure intra-PFD thrombosis and hemispheric ischemia. Aspirin and ticagrelor were restarted, and the surgery department consulted for tracheostomy and percutaneous endoscopic gastrostomy tube placement. Short-half-life GPIIb/IIIa infusions served as bridges to surgery after aspirin and tirofiban washout.

**Conclusion:** NCCU management of complications of PFD placement remains under-researched. The use of long-acting antiplatelet agents post-PFD limits the safe administration of surgical procedures. Bridging with GPIIb/IIIa infusion may facilitate the safe delivery of intensive care in these cases.

**Keywords:** Half-life; Platelet aggregation inhibitors; Thrombosis; Aneurysm; Ischemia; Stents

## INTRODUCTION

In recent decades, endovascular approaches for treating unruptured intracranial aneurysms (IA) have become increasingly common. Coil embolization has been the mainstay endovascular approach for the treatment of IA for many years; however, pipeline flow diverters (PFD) are an alternative endovascular approach that have been used with increasing frequency. PFDs offer an alternative approach to aneurysm treatment with high rates of com-

plete aneurysmal occlusion. However, PFD placement is associated with several potential complications, including intracranial hemorrhage and ischemic stroke [1]. These complications and routine postprocedural care for IA treated with PFD placement are likely to be managed in a neurocritical care unit (NCCU) and may be encountered in that setting with increasing frequency as PFD placement becomes more common.

In a meta-analysis, Brinjikji et al. [2] found that 6% of patients with IAs experienced ischemic stroke after PFD placement, with

higher rates found in patients with large and giant aneurysms. Intraprocedurally, GPIIb/IIIa inhibitor infusions are often used to prevent thrombosis. Additionally, several PFD design innovations have been tested and implemented in recent years to decrease the likelihood of thromboembolic formation within the device after placement, such as covalently bonded coatings composed of polar molecules [3]. Nevertheless, careful antiplatelet management, preferably in the NCCU setting, in post-PFD IA patients is crucial.

There is no consensus on antiplatelet regimens for post-PFD IA patients, and the approaches differ greatly among institutions. Dual aspirin-clopidogrel therapy is common, with ticagrelor sometimes used instead of clopidogrel [4]. Both clopidogrel and ticagrelor have relatively long half-lives (7–8 and 7–9 hours, respectively) and, when administered without a loading dose at steady-state dosing, can require as many as seven days to reach maximum platelet inhibition [5,6]. At steady-state concentrations, commonly used antiplatelets, such as clopidogrel, require long washout periods to eliminate their antiplatelet effects [7]. Therefore, in patients requiring surgical intervention after PFD placement, especially early after placement, antiplatelet therapy should be temporarily discontinued. Given its relatively long half-life, a washout of typically 7 days is suggested for both clopidogrel and ticagrelor, and neuroaxial procedures should be required [8]. Should emergent neuroaxial intervention be required, in the absence of any acute, direct reversal agents, platelet transfusion in addition to medication cessation is typically employed to minimize the risk of life-threatening hemorrhage [9]. Whether related to an emergent complication or a planned elective procedure, an interdisciplinary intensive care team must conduct patient-specific consideration of the risk of thromboembolic and hemorrhagic complications and administer antiplatelet agents to mitigate the risk. To date, no guidelines have been established for the management of this condition. However, the interim transition to a short half-life and rapidly reversible antiplatelet infusion with rapid washout periods, such as with a GPIIb/IIIa inhibitor, may be useful in post-PFD IA patients requiring elective surgical intervention in an intensive care setting.

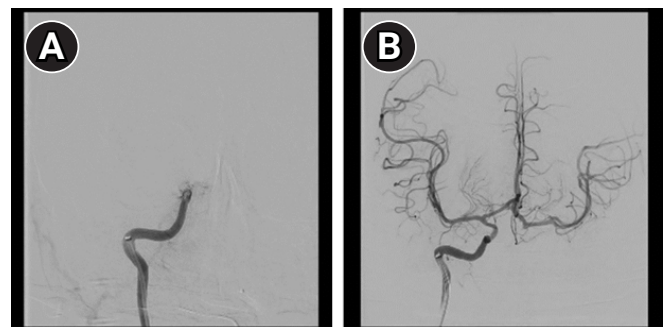## CASE REPORT

A 47-year-old female with no prior history of ischemic or hemorrhagic stroke and without any known coagulopathy presented for planned staged treatment of bilateral internal carotid artery aneurysm (right side 6–7 mm in diameter with a depth of 2–3 mm; left side significantly larger) with PFDs (left-sided PFD first, followed by the right side eight weeks later, with comparable preparation

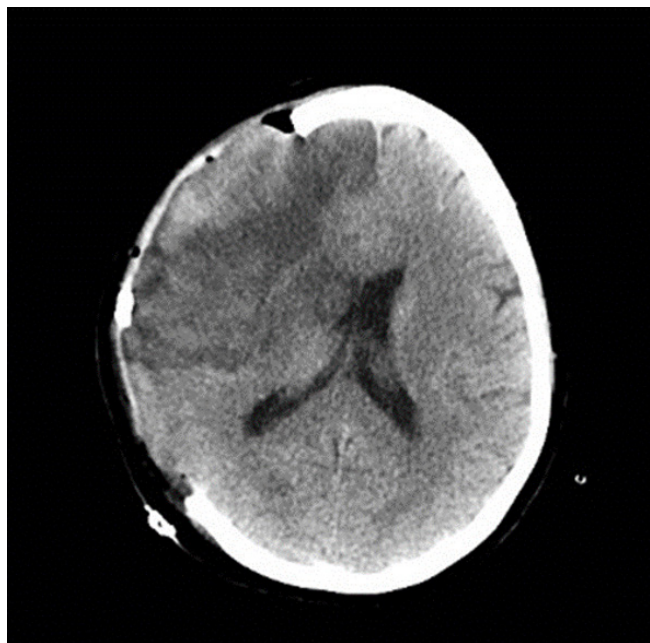
and procedure carried out for each). The left-sided PFD was placed on March 5, 2021, without complications. The patient was discharged after left-sided PFD placement, and ticagrelor and aspirin were initiated and continued through and after right-sided placement 8 weeks later. Three days prior to left-sided placement and antiplatelet initiation, the baseline P2Y<sub>12</sub> level was 237. After 48 hours of ticagrelor and aspirin therapy, the P2Y<sub>12</sub> value was 48. Three days before right-sided PFD placement, the P2Y<sub>12</sub> value was 9, suggesting a therapeutically appropriate response.

The patient continued the 8-week course of preprocedural aspirin/ticagrelor antiplatelet therapy until April 29, 2021, when the patient was admitted for scheduled right-sided PFD placement. Immediately after the placement, the patient was admitted to the NCCU for routine recovery. In the acute post-procedural phase, the patient developed drowsiness and headache (initially attributed to a post-anesthesia effect). Several hours later, the patient became increasingly unresponsive and developed posturing and right gaze deviation. Emergency endovascular intervention revealed in-stent thrombosis causing complete right hemispheric ischemia (Fig. 1). Revascularization was successful and completed within 8 hours of the initial documentation of drowsiness and headaches. Subsequent head computed tomography revealed a resultant complete hemispheric ischemic stroke complicated by subarachnoid hemorrhage and diffuse cerebral edema with subfalcine herniation (Fig. 2). Ticagrelor and aspirin were discontinued to allow decompressive hemicraniectomy. Following the procedure, ticagrelor and aspirin were reinitiated due to concerns regarding repeat in-stent thrombosis. The P2Y<sub>12</sub> value immediately before antiplatelet initiation was 403, suggesting normal platelet function.

One week later, the patient was admitted to the NCCU for sup-



**Fig. 1.** Digital subtraction angiography performed on the second day of admission. Images were captured by interventional radiologist utilizing digital subtraction angiography. (A) Image demonstrates thrombus present in the internal carotid artery with downstream circulation blocked. (B) Image demonstrates revascularization after successful removal of thrombus via thrombectomy.



**Fig. 2.** Head computed tomography imaging captured on the third day of admission. Decompressive right hemicraniectomy evident. Continued subfalcine herniation also demonstrated.

portive care. As per family discussion, and in line with the patient and family wishes, the surgery department was consulted to begin planning for a scheduled tracheostomy and percutaneous endoscopic gastrostomy tube placement. The risk of hemorrhage occurring during these surgeries in patients on ticagrelor and aspirin was weighed against the risk of repeat thrombosis if antiplatelet therapy was discontinued for washout and for the procedure. The surgery and NCCU teams agreed to use a perioperative bridging strategy to mediate these risks and facilitate the planned procedures. To implement this plan, ticagrelor and aspirin were discontinued, and an eptifibatide (GPIIb/IIIa inhibitor; half-life, 2.5 hours) bridge infusion was initiated during the washout period [10]. Due to medication shortages, eptifibatide was replaced by tirofiban (GPIIb/IIIa inhibitor; half-life, 2 hours) [11]. After a planned five-day washout with a GPIIb/IIIa bridge, tirofiban was administered the morning of the scheduled surgery and restarted in the evening. No excessive bleeding was observed during the surgery. The following day, ticagrelor and aspirin were reintiated with the agreement of the general surgery team, and tirofiban infusion was discontinued.

## DISCUSSION

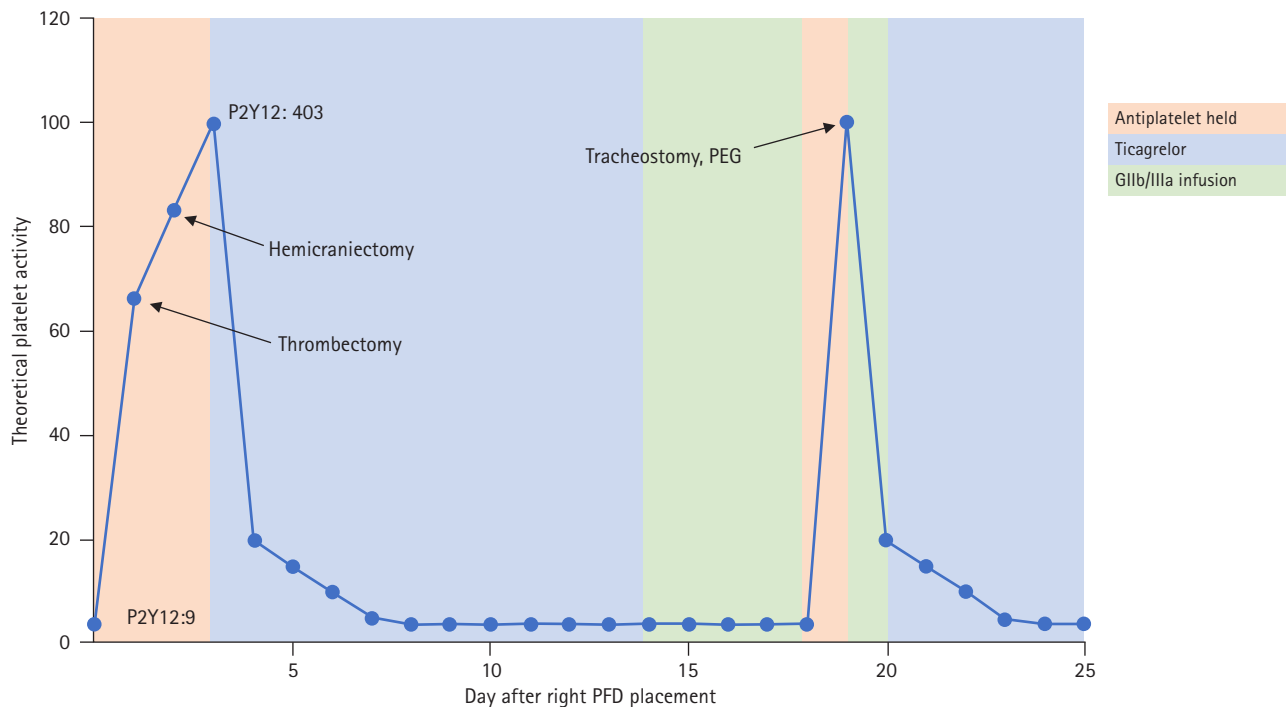
Careful management of platelet activity and antiplatelet medication use in patients with unruptured IA undergoing endovascular

treatments is important. As PFD utilization increases, cases similar to the one described above are likely to occur with increasing frequency and are likely to be managed in NCCUs. This case highlights a challenging conundrum: balancing the risk of hemorrhage during urgent surgery with the risk of intra-PFD thrombosis. Although the general conundrum of balancing the risks of hemorrhage and thrombosis is regularly encountered in intensive care settings, there are no established guidelines for antiplatelet management within the specific context of PFD placement for IA.

In this case, we propose a potential approach to balance these risks: a short-half-life antiplatelet bridge via GPIIb/IIIa inhibitor infusion. The GPIIb/IIIa inhibitor clears rapidly, allowing surgery to be performed on the same day as discontinuation. This minimizes the at-risk period for thromboembolic events with antiplatelet discontinuation, thereby reducing the risks of hemorrhage and thrombosis during surgery. In our case, the theoretical platelet activity and risk were estimated and tracked using the P2Y<sub>12</sub> values (Fig. 3).

However, one potential concern is that the antiplatelet effects of these agents may persist for a long time despite discontinuation and plasma clearance. Studying the pharmacokinetics of tirofiban, Kereiakes et al. [12] found that ex vivo platelet aggregation was restored rapidly after the discontinuation of tirofiban infusion, lagging only slightly behind the tirofiban clearance rate at higher doses. At lower doses of tirofiban, the time taken to restore platelet aggregation was closely in line with its half-life. Kam and Egan [13] stated that platelet aggregation is also restored rapidly after discontinuation of eptifibatide infusion, again closely in line with its half-life. They also noted that along with restored platelet aggregation, hemostasis was clinically normal within a few hours after discontinuation. Evidently, the plasma concentrations of tirofiban and eptifibatide closely align with platelet inhibition; as these agents clear, platelet function and hemostasis rapidly recover.

Cangrelor is a P2Y<sub>12</sub> inhibitor that was recently Food and Drug Administration-approved. The drug rapidly reaches a plasma steady state and has a short half-life of 3–5 minutes. Currently, cangrelor is increasingly being used as a “bridge” antiplatelet. A small number of pharmacokinetic studies have found that platelet aggregation is restored rapidly after discontinuation; most patients show baseline aggregation within an hour or less [14]. Van Tuyl et al. [15] compared eptifibatide, tirofiban, and cangrelor as antiplatelet-bridging agents in patients with perioperative cardiac disease. They found that eptifibatide and tirofiban had similar efficacies in this role. However, because of their significant reliance on renal clearing, cangrelor may be a better option for patients with elevated creatinine levels. While not explored, to the best of the



**Fig. 3.** Day post-pipeline flow diverters (PFD) placement vs. patient's theoretical platelet activity. PEG, percutaneous endoscopic gastrostomy.

authors' knowledge, this approach of using bridging antiplatelets will likely play an increasingly important role in the NCCU, as PFD devices are used with increasing frequency. Most clinical trials on cangrelor have explored its use in a cardiac context. Overall, there is a dearth of literature on the use of GPIIb/IIIa inhibitors or cangrelor as antiplatelet bridges in neurocritical care settings.

This study has several limitations. First, this was a single-patient, single-center study. Additionally, no extensive pharmacokinetic analysis was performed on our patient. Clinically available laboratory studies, such as P2Y12 analysis, have been used to represent real-world clinically applicable experiences. Thromboelastograph platelet mapping, an assay that provides detailed numerical data to better gauge clotting and bleeding risk, could also have been considered; however, at the time of patient management, it was not routinely used in our NCCU.

In light of these limitations, the authors present this report as a real-world, hypothesis-generating case, illustrating the dearth of literature and suggesting further exploration of short-half-life GPIIb/IIIa inhibitors or cangrelor as antiplatelet bridging agents in the neurocritical care context. Antiplatelet management techniques in acute neurology, specifically in the perioperative and intensive care management of patients with PFD for IA, require further research to minimize risk. Irrespective of the specific pharmacological antiplatelet agents used, the efficacy of this regimen and bridging strategies require further study. We present this case to il-

lustrate the clinical framework. However, large-scale clinical data and guidelines are needed to establish an effective approach for antiplatelet management in the NCCU for PFD complications.

## ARTICLE INFORMATION

### Ethics statement

The retrospective chart review for this report was conducted after receiving Institutional Review Board approval through the Eastern Virginia Medical School (No. 22-03-NH-0036). The institution also provided a "non-research" determination. Informed consent to write this report was obtained from the patient's husband.

### Conflict of interest

No potential conflict of interest relevant to this article.

### ORCID

Aaron Zweig

<https://orcid.org/0009-0006-4756-370X>

### Author contributions

Conceptualization: AZ, MRH, JSS. Methodology: AZ, MRH, JSS. Formal analysis: AZ, MRH, JSS. Data curation: AZ, MRH, JA, RP. Visualization: AZ, JA. Project administration: AZ, MRH. Writing—original draft: AZ. Writing—review & editing: AZ, MRH, JSS, JA, RP.



## REFERENCES

1. Bhatia KD, Kortman H, Orru E, Klostranec JM, Pereira VM, Krings T. Periprocedural complications of second-generation flow diverter treatment using Pipeline Flex for unruptured intracranial aneurysms: a systematic review and meta-analysis. *J Neurointerv Surg* 2019;11:817-24.
2. Brinjikji W, Murad MH, Lanzino G, Cloft HJ, Kallmes DF. Endovascular treatment of intracranial aneurysms with flow diverters: a meta-analysis. *Stroke* 2013;44:442-7.
3. Hanel RA, Aguilar-Salinas P, Brasiliense LB, Sauvageau E. First US experience with Pipeline Flex with Shield Technology using aspirin as antiplatelet monotherapy. *BMJ Case Rep* 2017;2017:bcr2017219406.
4. Texakalidis P, Bekelis K, Atallah E, Tjoumakaris S, Rosenwasser RH, Jabbour P. Flow diversion with the pipeline embolization device for patients with intracranial aneurysms and antiplatelet therapy: a systematic literature review. *Clin Neurol Neurosurg* 2017;161:78-87.
5. Darwhekar G, Jain DK, Patidar VK. Formulation and evaluation of transdermal drug delivery system of clopidogrel bisulfate. *Asian J Pharm Life Sci* 2011;1:269-78.
6. Dobesh PP, Oestreich JH. Ticagrelor: pharmacokinetics, pharmacodynamics, clinical efficacy, and safety. *Pharmacotherapy* 2014;34:1077-90.
7. Savcic M, Hauert J, Bachmann F, Wyld PJ, Geudelin B, Cariou R. Clopidogrel loading dose regimens: kinetic profile of pharmacodynamic response in healthy subjects. *Semin Thromb Hemost* 1999;25 Suppl 2:15-9.
8. Stanford School of Medicine. Anticoagulation guidelines for neuraxial procedures: guidelines to minimize risk spinal hematoma with neuraxial procedures. Stanford School of Medicine; 2013.
9. Yeung LY, Sarani B, Weinberg JA, McBeth PB, May AK. Surgeon's guide to anticoagulant and antiplatelet medications part two: antiplatelet agents and perioperative management of long-term anticoagulation. *Trauma Surg Acute Care Open* 2016;1:e000022.
10. Curran MP, Keating GM. Eptifibatide: a review of its use in patients with acute coronary syndromes and/or undergoing percutaneous coronary intervention. *Drugs* 2005;65:2009-35.
11. McClellan KJ, Goa KL. Tirofiban: a review of its use in acute coronary syndromes. *Drugs* 1998;56:1067-80.
12. Kereiakes DJ, Kleiman NS, Ambrose J, Cohen M, Rodriguez S, Palabrica T, et al. Randomized, double-blind, placebo-controlled dose-ranging study of tirofiban (MK-383) platelet IIb/IIIa blockade in high risk patients undergoing coronary angioplasty. *J Am Coll Cardiol* 1996;27:536-42.
13. Kam PC, Egan MK. Platelet glycoprotein IIb/IIIa antagonists: pharmacology and clinical developments. *Anesthesiology* 2002;96:1237-49.
14. Fugate SE, Cudd LA. Cangrelor for treatment of coronary thrombosis. *Ann Pharmacother* 2006;40:925-30.
15. Van Tuyl JS, Newsome AS, Hollis IB. Perioperative bridging with glycoprotein IIb/IIIa inhibitors versus cangrelor: balancing efficacy and safety. *Ann Pharmacother* 2019;53:726-37.