

## Unique case of a geminated supernumerary tooth with trifold crown

Amber Ather, Hunaiza Ather\*, Sanket Milan Sheth, Vidya Saraswathi Muliya

Department of Conservative Dentistry and Endodontics, Manipal College of Dental Sciences, Manipal, India

\*Department of Pedodontics and Preventive Dentistry, Manipal College of Dental Sciences, Manipal, India

### ABSTRACT

Gemination, a relatively uncommon dental anomaly, is characterized by its peculiar representation as a tooth with a bifid crown and a common root and root canal. It usually occurs in primary dentition. To come across gemination in a supernumerary tooth is a rare phenomenon. The purpose of this paper is to present a unique case of hyperdontia wherein gemination in an impacted supernumerary tooth resulted in a trifold crown unlike the usual bifid crown. The role of conventional radiographs as well as computed tomography, to accurately determine the morphology and spatial location, and to arrive at a diagnosis, is also emphasized in this paper. (*Imaging Sci Dent* 2012; 42 : 197-200)

**KEY WORDS:** Tooth, Supernumerary; Radiography; Tooth, Impacted; Multidetector Computed Tomography

Gemination is a developmental disturbance of the shape of teeth and is usually recognized as a partial cleavage of a single tooth germ resulting in one root and one pulp space with two partially or totally separated crowns.<sup>1</sup> Although the exact etiology is unclear, hereditary and local metabolic interference during the morphodifferentiation stage of the tooth germ are considered to be the prime cause.<sup>2</sup> It has a greater tendency to occur in the maxillary anterior region<sup>3</sup> and is more prevalent in the mongoloid population with no apparent gender predilection.<sup>4</sup>

Supernumerary teeth are defined as teeth that exceed the normal dental formula, regardless of their location and morphology.<sup>5</sup> They may be single, multiple, unilateral, or bilateral in their distribution but have a predilection for the premaxilla.<sup>6,7</sup> The presence of one or more supernumerary teeth in the dentition has been referred to as “hyperdontia”.<sup>8</sup>

We present here an incidental radiographic finding of a geminated supernumerary tooth with trifold crown in a case of hyperdontia, which to the best of our knowledge, is extremely rare.

### Case Report

A 19-year-old male patient of Malay ethnicity was referred to our department for the treatment of a decayed upper right second premolar (Fig. 1A). Initial periapical radiograph confirmed endodontic involvement of the offending tooth. Additionally, it revealed the presence of two radiopacities in the maxillary canine-premolar region (Fig. 1B). The first radiopacity was cast due to the presence of a paramolar, whereas the second radiopacity gave an image of a transversely positioned “Y” shaped structure, consisting of supernumerary crowns and a short root and root canal, suggestive of a geminated supernumerary tooth. A pericoronal radiolucency of approximately 2 mm surrounding the geminated crown was found.

Panoramic radiograph revealed the presence of supernumerary teeth in both the maxilla and mandible (Fig. 2). To gain further insight into the buccolingual positioning of the supernumeraries, maxillary and cross sectional mandibular occlusal radiographs were recommended (Fig. 3).

After obtaining informed consent from the patient, computed tomographic (CT) examination was performed with a 64-slice multidetector computed tomography (MDCT) scanner (Brilliance CT 64-channel, Philips Healthcare, Andover, MA, USA) using the dental software program DentaScan (GE Healthcare, Milwaukee, WI, USA). CT slices

Received April 15, 2012; Revised May 17, 2012; Accepted June 6, 2012

Correspondence to : Dr. Amber Ather

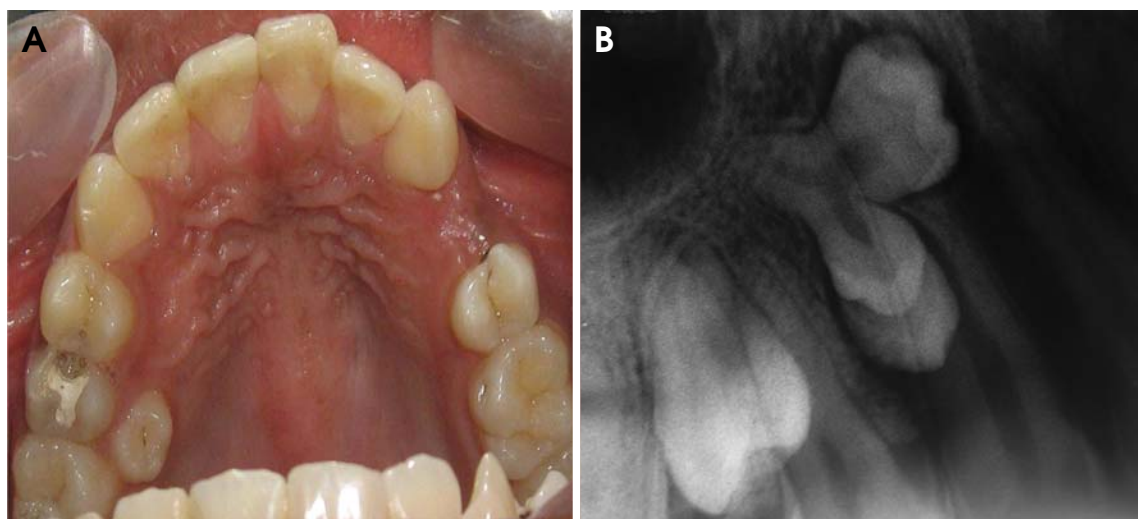
Department of Conservative Dentistry and Endodontics, Manipal College of Dental Sciences, Manipal University, Manipal-576104, Karnataka, India

Tel) 91-900-8417793, Fax) 91-820-2571966, E-mail) amberather03@yahoo.co.in

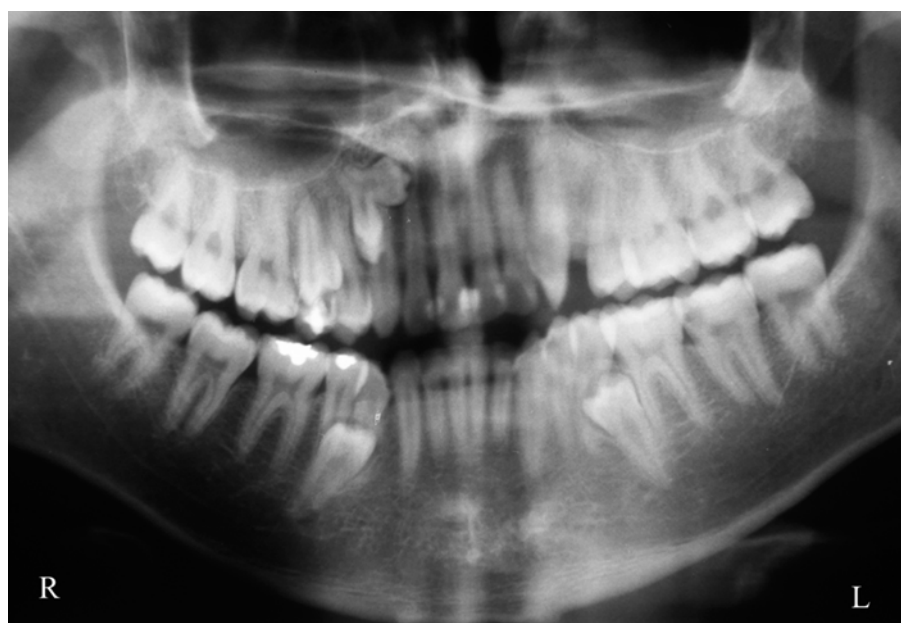
Copyright © 2012 by Korean Academy of Oral and Maxillofacial Radiology

This is an Open Access article distributed under the terms of the Creative Commons Attribution Non-Commercial License (<http://creativecommons.org/licenses/by-nc/3.0>) which permits unrestricted non-commercial use, distribution, and reproduction in any medium, provided the original work is properly cited.

Imaging Science in Dentistry • pISSN 2233-7822 eISSN 2233-7830



**Fig. 1.** A. Intraoral examination shows a decayed maxillary right second premolar and a paramolar palatal to the right maxillary first molar. B. Periapical radiograph shows the presence of a paramolar and a “Y” shaped radiopacity depicting supernumerary crowns with a common root and root canal.



**Fig. 2.** Panoramic radiograph reveals the presence of hyperdontia.

of 0.7 mm thickness were obtained (Fig. 4) along with the 3D reconstructed images (Fig. 5) which revealed the precise internal and external morphology of the supernumeraries. The ‘Y’ shaped structure consisted of a common root and root canal for three crowns: a medially directed molariform crown with a slight widening of the pericoronal space and two partially separated “premolar-like” crowns directed inferiorly, thereby confirming the diagnosis of geminated supernumerary tooth with trifold crown. Loss of the corti-

cal plate of the palatal vault was also evident in the axial slices.

Owing to the possibility of causing interference in the restorative treatment plan, the erupted maxillary paramolar was extracted, whereas the other impacted supernumerary teeth, except for their slight pericoronal radiolucency, displayed no associated pathology or danger to the adjacent vital structures. Hence, a decision was made to keep the patient under periodic follow-up evaluation.

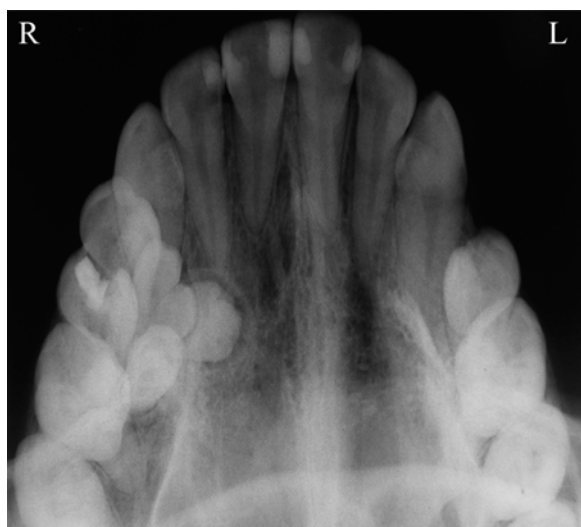## Discussion

Variation in the form and number of teeth is not an uncommon finding in clinical practice; however, their simultaneous presentation is a rare phenomenon. This report shows the occurrence of gemination in a supernumerary tooth, which to our knowledge is extremely rare. On reviewing the literature, we came across only two reports of geminated supernumerary teeth. Liu et al<sup>9</sup> first described the occurrence of gemination in a supernumerary tooth in the mandibular premolar region in 2007 and proposed a

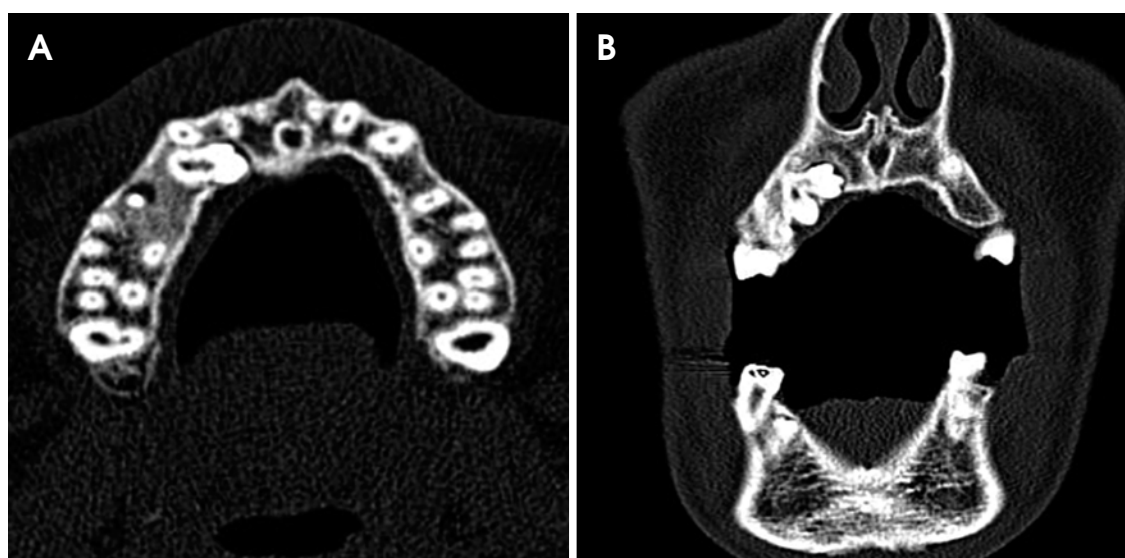
new morphologic class “geminated-premolar-like” for the same. Yang<sup>10</sup> reported a case of a geminated supernumerary tooth with two crowns and one root in the maxillary premolar region in 2012.

Our case was unique in that gemination of the supernumerary resulted in the formation of three crowns with a common root and root canal. After a thorough review of the literature and conducting a PubMed search using the keywords “gemination” or “geminated supernumerary” or “trifid tooth” or “triple tooth”, we did not come across any report of a geminated supernumerary with three crowns. Interestingly, there was a similarity between this case and the one reported by Yang<sup>10</sup> in terms of demographics of the patient, i.e. race (mongoloid) and gender (male). This could be a coincidental finding or might be an indication towards an increased prevalence of geminated supernumerary in this population, taking into account that supernumerary teeth tend to occur with high frequency in mongoloid males.<sup>11</sup>

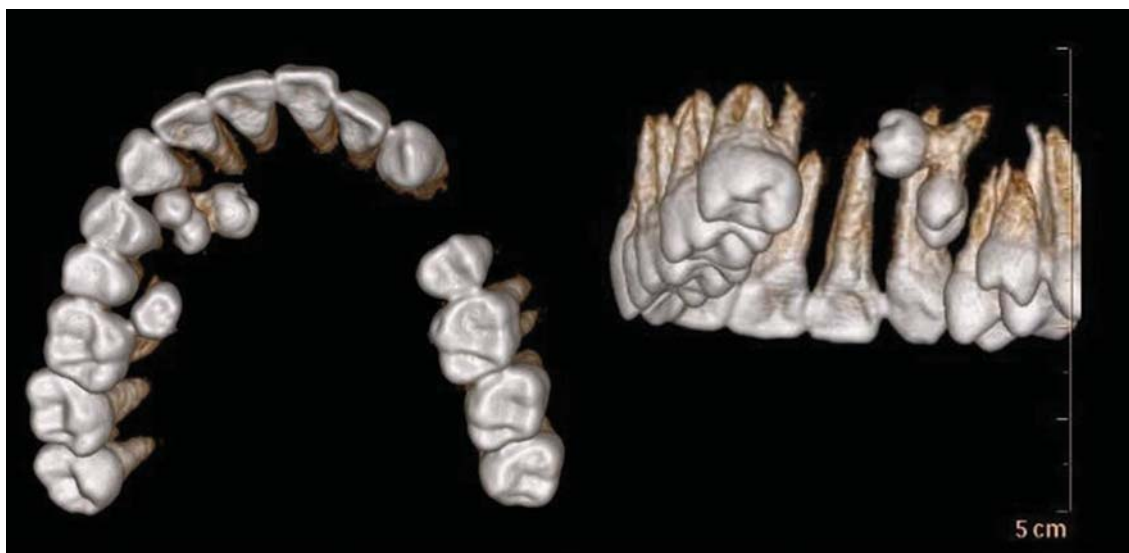
As approximately 75% of supernumerary teeth are asymptomatic and remain impacted,<sup>12</sup> they often present as an incidental finding on routine radiographic examination. Although conventional radiographs are usually able to provide sufficient details, they fail to provide definitive information concerning the 3-dimensional relationship of the supernumerary teeth and the surrounding structures for surgical planning.<sup>13</sup> In our case, computed tomography (CT) was able to clearly reveal the intra-osseous location and morphology of the supernumerary teeth, as well as their proximity to the adjacent teeth, sinus, and cortical bone.



**Fig. 3.** Maxillary occlusal radiograph shows the buccolingual positioning of supernumerary teeth.



**Fig. 4.** A. Axial CT slice through maxilla shows the medially directed molariform crown of the geminated supernumerary tooth. B. Coronal CT slice shows the loss of the cortical plate around the geminated supernumerary tooth in the maxilla.



**Fig. 5.** Three-dimensional reconstructed CT images display the paramolar and geminated supernumerary tooth with trifold crown along with their spatial orientation.

Although MDCT was taken in this case, cone beam computed tomography (CBCT) would be a superior alternative in terms of radiation exposure.<sup>14</sup>

Surgical intervention for the removal of supernumerary teeth may be considered only if they pose a risk of cystic transformation and show a potential to cause local disturbances such as root resorption, rotation, and malformation of permanent teeth.<sup>15</sup> In order to prevent future complications in cases of impacted supernumerary teeth, periodic follow-up evaluations are essential.

To conclude, geminated supernumerary teeth might often go undetected in routine dental practice, which can be attributed to their subtle presentation and the limitations of conventional radiography. Therefore, it seems worthwhile to draw more attention to gemination in supernumerary teeth and call for keen interest on the part of the dentist to recognise and report such cases with greater frequency.

## References

1. Chen RJ, Wang CC. Geminatio of a maxillary premolar. *Oral Surg Oral Med Oral Pathol* 1990; 69 : 656.
2. Grover PS, Lorton L. Geminatio and twinning in the permanent dentition. *Oral Surg Oral Med Oral Pathol* 1985; 59 : 313-8.
3. Duncan WK, Helpin ML. Bilateral fusion and gemination: a literature analysis and case report. *Oral Surg Oral Med Oral Pathol* 1987; 64 : 82-7.
4. Crawford NL, North S, Davidson LE. Double permanent incisor teeth: management of three cases. *Dent Update* 2006; 33 : 608-10.
5. Yague-Garcia J, Berini-Aytes L, Gay-Escoda C. Multiple supernumerary teeth not associated with complex syndromes: a retrospective study. *Med Oral Patol Oral Cir Bucal* 2009; 14 : E331-6.
6. Primosch RE. Anterior supernumerary teeth-assessment and surgical intervention in children. *Pediatr Dent* 1981; 3 : 204-15.
7. Nazif MM, Ruffalo RC, Zullo T. Impacted supernumerary teeth: a survey of 50 cases. *J Am Dent Assoc* 1983; 106 : 201-4.
8. King NM, Lee AM, Wan PK. Multiple supernumerary premolars: their occurrence in three patients. *Aust Dent J* 1993; 38 : 11-6.
9. Liu DG, Zhang WL, Zhang ZY, Wu YT, Ma XC. Three-dimensional evaluations of supernumerary teeth using cone-beam computed tomography for 487 cases. *Oral Surg Oral Med Oral Pathol Oral Radiol Endod* 2007; 103 : 403-11.
10. Yang G. Supernumerary teeth and gemination. *Br J Oral Maxillofac Surg* 2012; 50 : e15.
11. Davis PJ. Hypodontia and hyperdontia of permanent teeth in Hong Kong schoolchildren. *Community Dent Oral Epidemiol* 1987; 15 : 218-20.
12. Acikgoz A, Acikgoz G, Tunga U, Otan F. Characteristics and prevalence of non-syndrome multiple supernumerary teeth: a retrospective study. *Dentomaxillofac Radiol* 2006; 35 : 185-90.
13. Kim KD, Ruprecht A, Jeon KJ, Park CS. Personal computer-based three-dimensional computed tomographic images of the teeth for evaluating supernumerary or ectopically impacted teeth. *Angle Orthod* 2003; 73 : 614-21.
14. Yang Y, Xia X, Wang W, Qin M. Uncommon fusion of teeth and lateral periodontal cyst in a Chinese girl: a case report. *Oral Surg Oral Med Oral Pathol Oral Radiol Endod* 2011; 112 : e18-20.
15. Anthonappa RP, Omer RS, King NM. Characteristics of 283 supernumerary teeth in southern Chinese children. *Oral Surg Oral Med Oral Pathol Oral Radiol Endod* 2008; 105 : e48-54.