

Transoral Robotic Thyroidectomy

Dawon Park, Hong Kyu Kim and Hoon Yub Kim

Department of Surgery, KUMC Thyroid Center, Korea University Anam Hospital, Korea University College of Medicine, Seoul, Korea

Transoral approach for thyroidectomy recently gains a lot of attention among the thyroid surgeons, with definite merits over previously developed remote-access approaches. The approach not only resulted in the ideal cosmetic outcome but less postoperative pain with smaller dissection plane in comparison with other approaches. We have successfully introduced the robotic surgical system and its related techniques to this transoral surgical approach for thyroidectomy, which enables the surgeon to have the three-dimensional operative vision and to use the articulating instruments to enhance the optimal surgical outcomes. Herein, our unique procedures of transoral robotic thyroidectomy (TORT) are described, and possible advantages and disadvantages of the operation are discussed.

Key Words: Transoral thyroidectomy, Remote-access thyroidectomy, Transoral robotic thyroidectomy

Introduction

Thyroidectomy has been the standard treatment of choice for thyroid cancer and for the intractable benign thyroid diseases. Subsequently the visible scar on the neck has been the concern for patients receiving this surgery. Since the first report of endoscopic parathyroid surgery in 1996, numerous approaches have been developed for endoscopic thyroidectomy in attempt to avoid the visible scar on the neck.¹⁾ The feasibility and safety of endoscopic thyroidectomy have been reported in large series of patients,^{2,3)} and these studies allowed the techniques to progress in time. However, previously developed methods of endoscopic or robotic thyroidectomy have been criticized for not being truly minimally invasive – the existing methods require extensive dissection of the chest, axilla and/or neck region along with the long operation time. To fulfill such demand for a truly

minimally invasive approach in thyroidectomy, and to achieve the goal of the scar-less surgery rather than the scar-hidden surgery as well, the transoral thyroid surgery was developed.

The first human series of transoral thyroidectomy study was reported by Wilhelm and Metzger.⁴⁾ Nakajo et al.⁵⁾ also reported their clinical trials in human transoral endoscopic thyroidectomy method, named TOVANS, which was performed without gas insufflation. These inspirations led us to develop the new approach for transoral thyroid surgery, using mandibular periosteal access, which was named as the transoral periosteal thyroidectomy (TOPOT). In order to construct anatomically feasible and applicable approach, TOPOTs were first performed in seven fresh human cadavers. Based on the experiments with cadavers, anatomical spaces were defined, and the mandibular periosteal approach was developed to permit endoscopic instrument movements and to reduce the risk of injuries to the upper teeth, nose, and mental nerves.⁶⁾ Furthermore,

Received May 4, 2018 / Accepted May 18, 2018

Correspondence: Hoon Yub Kim, MD, PhD, FACS, Department of Surgery, Korea University College of Medicine, 73 Incheon-ro, Seongbuk-gu, Seoul 02841, Korea

Tel: 82-2-920-6849, Fax: 82-2-928-1631, E-mail: hoonyubkim@korea.ac.kr

Copyright © 2018, the Korean Thyroid Association. All rights reserved.

© This is an open-access article distributed under the terms of the Creative Commons Attribution Non-Commercial License (<http://creativecommons.org/licenses/by-nc/4.0/>), which permits unrestricted non-commercial use, distribution, and reproduction in any medium, provided the original work is properly cited.

using TOPOT, we were able to identify the recurrent laryngeal nerves and parathyroid glands to preserve them in all cadavers. Then the TOPOT was performed in ten live pigs to show the clinical safety. In the swine experiments, no major intra-/post-operative complications were observed, just except for a postoperative fluid collection in the operative field when no drain was placed.⁷⁾

In recent years, robotic thyroidectomy is markedly popularized, especially in the large-volume institutes in Korea,^{8,9)} because surgeons prefer magnified three-dimensional operative view offered by dual-channel endoscope in robotic system, which enables surgeons to perform more precise, safe surgery with less fatigue.¹⁰⁾ Articulating instruments also allows tremor-free dissection with fine movements. Copiously embracing the merits of robotic surgery, with the foundation of the positive cadaver and animal trial outcomes, the transoral robotic thyroidectomy (TORT) was able to be proceeded on to human patients to report the successful outcomes to date.¹¹⁾

Steps of TORT

Working Space Formation

The patient is positioned supine and placed under general anesthesia. After intubated with nerve monitoring endotracheal electromyogram tube, the neck is

placed in slight extension. Three incisions are made in the gingival-buccal sulcus; one in the midline, a 1.5-cm-length inverted U shape incision approximately 2 cm above the frenulum labii inferioris, and two 0.5-cm-length incisions laterally near the angle of mouth (Fig. 1A). The central incision is addressed first. Once the periosteum is identified through the midline incision, a submental subplatysmal pocket is formed by blunt dissection with mosquito and Kelly forceps to create a tunnel from the edge of the mandible to lower neck by injecting 1:200,000 epinephrine saline mixture for hydro-dissection of the subplatysmal plane. Then, blunt dissection with 8-mm-tipped vascular surgical tunneler is gently performed to elevate the platysma off the strap muscles all the way down towards the suprasternal notch (Fig. 1B).

Once an adequate flap is created, the endoscope cannula is inserted. CO₂ insufflation (5–7 mmHg) is introduced and maintained via the central port. A similar blunt dissection is also performed through the two lateral incision sites, allowing insertion of the instrument cannulae into the subplatysmal working space. Next, standard laparoscopic instruments – a suction electrocautery and an ultrasonic shears – are used to elevate the platysma from the level of the mandible to the sternum inferiorly and laterally to the sternocleidomastoid muscles (Fig. 2A). Subsequently, an 8-mm bariatric trocar can be inserted through an incision made along the patient's right axillar fold into the sub-

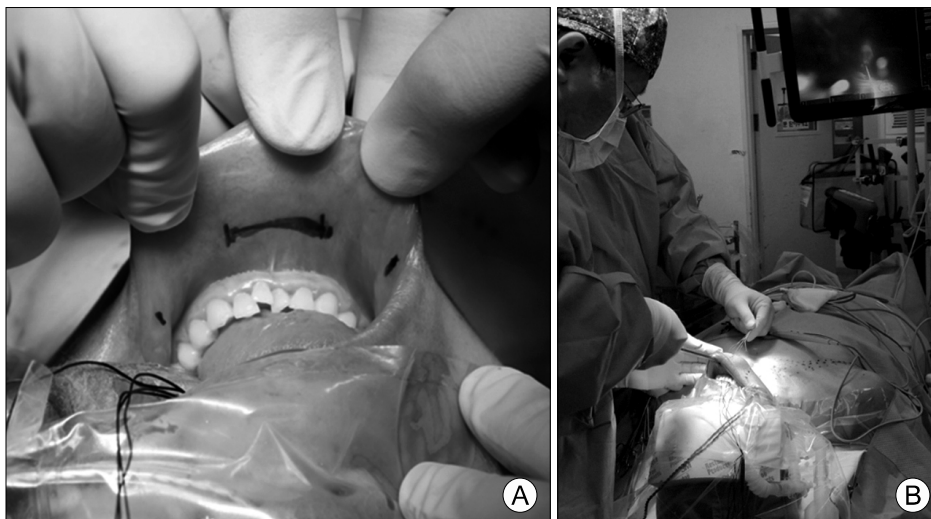

Fig. 1. (A) Location of incisions. (B) Blunt dissection with 8-mm-tipped vascular surgical tunneler.

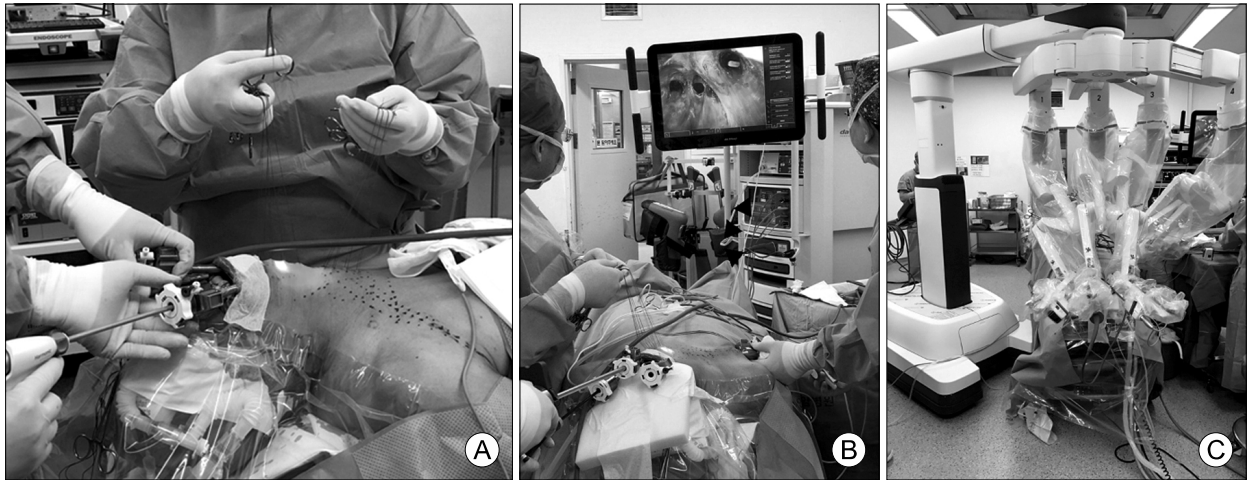


Fig. 2. Flap formation of transoral robotic thyroidectomy and docking of robot. (A) Subplatysmal dissection using a suction electrocautery and an ultrasonic shears. (B) The axillary port was made on the right side for countertraction and to be used later for drain insertion. (C) Docking of da Vinci-Xi surgical system.

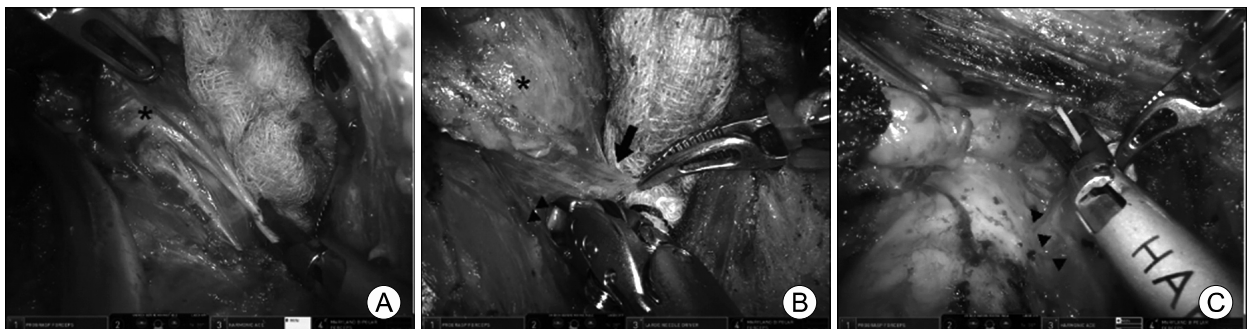


Fig. 3. The surgical steps of transoral robotic thyroidectomy. (A) Ligation of the superior thyroidal vessels of the right thyroid gland. (B) Identification of the left recurrent laryngeal nerve (arrowheads) and superior parathyroid gland (black arrow). (C) Completion of left thyroidectomy preserving recurrent laryngeal nerve (arrowheads). *: thyroid gland

platysmal working space for counter-traction of the strap muscles or perineural tissue during the operation and for later insertion of the closed suction drain if desired (Fig. 2B). A few vicryl stitches can be used to help retract the subplatysmal flap superiorly in order to create a larger working space.

Docking Stage

Once the working space formation is complete, the robotic system is deployed. The cannulae are docked into the robotic arms, starting with the central cannula to secure the position of the endoscope (30°, down facing). A Maryland dissector and the Harmonic scalpel are inserted into the left and right ports, respectively (Fig. 2C).

Console Stage

Dissection in the midline raphe is performed to separate the strap muscles. The strap muscles are dissected off the thyroid gland, exposing the lobe(s) of interest. The pyramidal lobe is dissected off from the thyroid cartilage if it is identified, and isthmusectomy is performed subsequently. Once the thyroid lobe is freed off the trachea medially, the superior pole is addressed. Careful dissection of the superior lobe is performed ligating one vessel at a time (Fig. 3A). The superior parathyroid gland is identified and preserved first. Then the thyroid lobe is retracted inferiorly to facilitate the identification of the recurrent laryngeal nerve (RLN) at its entry point into the larynx around cricothy-

roid articulation (Fig. 3B). Once the RLN is identified and carefully preserved, the Berry's ligament is addressed. The dissection is then carried out inferiorly to identify and to preserve the inferior parathyroid gland. Once the inferior lobe is free off of its surrounding soft tissue, hemithyroidectomy is complete. The contralateral lobectomy can be completed at the same time if necessary without any additional incision.

Ipsilateral central compartment dissection with tracing the RLN into the thoracic inlet may be followed if it is needed, and the lympho-adipose tissue in the central compartment can be retrieved en-bloc with the resected thyroid lobe (Fig. 3C). The nerve stimulator probe is used to stimulate the RLN and to test neurophysiologic integrity during and after the procedure. The specimen can be removed through the additional axillar incision in an endoscopic plastic bag without any disruption usually. Meticulous hemostasis is achieved and the wound is irrigated. A Jackson Pratt drain is inserted through the axillary port and the middle raphe of the strap muscles are re-approximated with a self-locking absorbable suture. The oral vestibule incisions are closed in a layer with absorbable sutures. A compression dressing is placed across the neck and chin after the patient has been extubated.

Postoperative Management

Patients can be permitted to sips of water 4 hours after surgery. A soft bland diet and ice cream intake are recommended in the evening of the operation day, and the normal regular diet can be proceeded on the postoperative first day. Intraoral stitches are removed in the second week after discharge at the outpatient clinic.

Advantages and Disadvantages of TORT

In technical aspects, TORT shows several distinctions. First, surgeons can approach deep upper part of thyroid glands with much ease in TORT despite the cephalad to caudal approach direction since endo-wrists allow articulated movements. Secondly, fine

and detailed dissection around the critical structures, such as parathyroid glands or RLNs, are readily available with robotic tremor-filtering system. Furthermore, operative view of TORT provides magnified three-dimensional field to the operator.

Yet, one of the most outstanding outcomes of transoral thyroidectomy is that TORT shows cosmetically superior results over any other thyroidectomy approaches because intraoral scars are not only hidden from exterior but also can completely disappear in a few months. Furthermore, compare to gasless transaxillary and bilateral axillo-breast approach, transoral thyroidectomy does not require extensive flap dissection. While gasless transaxillary and bilateral axillo-breast approach requires wide flap dissection at axilla and upper chest, the extent of dissection for transoral thyroidectomy is similar to conventional open thyroidectomy – from sternal notch to thyroid cartilage level. Small dissection area also means lesser sensory loss and reduced postoperative pain.

Yet, transoral thyroidectomy has been associated with some serious complications, infection being one of them. The transoral technique is potentially at risk for spreading oral microflora into the neck exploration plane. This issue was dealt in advance during the animal experiments and none of the pigs showed any signs of severe infection after the transoral thyroidectomy. Prophylactic intravenous antibiotics and closed suction drain to the operation field through the axillary port can also help in preventing such complications. So far, no patients have experienced severe infections to the anterior neck area or the oral wounds after TORT. These results suggest that, if prophylactic antibiotics are given and the drain is inserted, postoperative infection in transoral thyroidectomy can be prevented.

In addition, transoral thyroidectomy has also been encountered with the mental nerve injury. Mental nerve is a sensory nerve innervating the skin of the lower lip and chin; hence, injury to this nerve can cause permanent numbness around lower lip and chin. Such complication can be avoided through modification of port placement. To be more specific, mental foramen is located below canine root, and after

branching, mental nerve runs medially to the foramen. Therefore, the risk of nerve injury can be reduced if the ports are placed more distal and lateral to canine root (Fig. 3).

Some other minor complications such as zygomatic region bruise and tearing of oral commissures can be prevented via protective sponge application over zygomatic bone and careful monitoring of the robotic arm movement range by assistant, respectively.

In conclusion, TORT may be a suitable alternative for patients undergoing a thyroidectomy who prefer a scar-free surgery with favorable outcomes.

References

- 1) Gagner M. *Endoscopic subtotal parathyroidectomy in patients with primary hyperparathyroidism. Br J Surg* 1996;83(6):875.
- 2) Kang SW, Jeong JJ, Yun JS, Sung TY, Lee SC, Lee YS, et al. *Gasless endoscopic thyroidectomy using trans-axillary approach; surgical outcome of 581 patients. Endocr J* 2009;56(3):361-9.
- 3) Choi JY, Lee KE, Chung KW, Kim SW, Choe JH, Koo do H, et al. *Endoscopic thyroidectomy via bilateral axillo-breast approach (BABA): review of 512 cases in a single institute. Surg Endosc* 2012;26(4):948-55.
- 4) Wilhelm T, Metzger A. *Endoscopic minimally invasive thyroidectomy (eMIT): a prospective proof-of-concept study in humans. World J Surg* 2011;35(3):543-51.
- 5) Nakajo A, Arima H, Hirata M, Mizoguchi T, Kijima Y, Mori S, et al. *Trans-Oral Video-Assisted Neck Surgery (TOVANS). A new transoral technique of endoscopic thyroidectomy with gasless premandible approach. Surg Endosc* 2013;27(4):1105-10.
- 6) Lee HY, Richmon JD, Walvekar RR, Holsinger C, Kim HY. *Robotic transoral periosteal thyroidectomy (TOPOT): experience in two cadavers. J Laparoendosc Adv Surg Tech A* 2015;25(2):139-42.
- 7) Lee HY, Hwang SB, Ahn KM, Lee JB, Bae JW, Kim HY. *The safety of transoral periosteal thyroidectomy: results of Swine models. J Laparoendosc Adv Surg Tech A* 2014;24(5):312-7.
- 8) Lee KE, Kim E, Koo do H, Choi JY, Kim KH, Youn YK. *Robotic thyroidectomy by bilateral axillo-breast approach: review of 1,026 cases and surgical completeness. Surg Endosc* 2013;27(8):2955-62.
- 9) Ban EJ, Yoo JY, Kim WW, Son HY, Park S, Lee SH, et al. *Surgical complications after robotic thyroidectomy for thyroid carcinoma: a single center experience with 3,000 patients. Surg Endosc* 2014;28(9):2555-63.
- 10) Richmon JD, Kim HY. *Transoral robotic thyroidectomy (TORT): procedures and outcomes. Gland Surg* 2017;6(3):285-9.
- 11) Lee HY, You JY, Woo SU, Son GS, Lee JB, Bae JW, et al. *Transoral periosteal thyroidectomy: cadaver to human. Surg Endosc* 2015;29(4):898-904.