

Case Report

Received: June 1, 2018
Revised: July 4, 2018
Accepted: July 9, 2018

Correspondence to:

In Yong Whang, M.D.
Department of Radiology, The
Catholic University of Korea,
Uijeongbu St. Mary's Hospital,
271 Cheonbo-ro, Uijeongbu City,
Gyeonggi-do 11765, Korea.
Tel. +82-31-820-3136
Fax. +82-31-846-3080
E-mail: tiger@catholic.ac.kr

This is an Open Access article distributed under the terms of the Creative Commons Attribution Non-Commercial License (<http://creativecommons.org/licenses/by-nc/3.0/>) which permits unrestricted non-commercial use, distribution, and reproduction in any medium, provided the original work is properly cited.

Copyright © 2018 Korean Society of Magnetic Resonance in Medicine (KSMRM)

Primary Angiosarcoma of the Breast: MRI Findings

Kanghun Lee¹, Kyung Jin Seo², In Yong Whang¹

¹Department of Radiology, The Catholic University of Korea, Uijeongbu St. Mary's Hospital, College of Medicine, Uijeongbu, Korea

²Department of Hospital Pathology, The Catholic University of Korea, Uijeongbu St. Mary's Hospital, College of Medicine, Uijeongbu, Korea

We present image findings, especially rare MRI of a primary breast angiosarcoma with its histopathology, and also analyze the relevant medical literature reports in terms of the MRI findings. As our patient had unique features of a primary breast angiosarcoma, this case could be very helpful for future diagnosis of this rare breast malignancy by MRI.

Keywords: Breast; Angiosarcoma; Breast MRI

INTRODUCTION

Primary breast angiosarcoma (PBA) is a very rare breast malignancy with a poorer prognosis than that of the usual ductal carcinoma. There have already been published studies and case reports regarding the clinical behavior and pathologic appearance of PBA. However, in those manuscripts it is difficult to find a description of breast MRI that has an important role in the differential diagnosis in clinical practice. Furthermore, the number of studies with appropriate T1, T2, and dynamic contrast enhancement (DCE) sequences using dedicated breast MRI, i.e. the basis of current breast MRI analysis, is very small and the results are quite variable (1-4). Therefore, a larger number of radiology reports will be required in order to diagnose PBA using breast MRI. We present a case of PBA we experienced along with a set of helpful MRI findings. We also attempted to help diagnose this rare clinical entity using breast MRI by summarizing the articles that have been published to date.

CASE REPORT

A 50-year-old woman with no previous medical history presented with a diffuse enlargement of the left breast which she had already noticed for four months. On physical examination, the left breast was seen to be swollen but without skin changes or sign of inflammation. There was also no apparent axillary lymphadenopathy. Mammography demonstrated an extremely dense breast without a definite mass or microcalcifications. Sonography revealed irregular indistinct heterogeneous echoic mass of the upper inner quadrant of the breast and demonstrated increased vascularity in the hypoechoic portion (Fig. 1). The patient underwent a core biopsy with a 14-gauge

needle and pathology suggested angiosarcoma of the breast. MRI revealed a 4.9×4.5 cm, irregularly shaped, low signal mass on T1-weighted imaging (T1WI). Several, dot-like, high signals, suggesting internal hemorrhagic foci within the mass, were noted. The mass showed high signal intensity on T2WI. The central portion of the mass showed early dynamic contrast enhancement (DCE) and a washout pattern (Type III). The periphery of the mass showed persistent trapping of contrast medium as irregularly margined enhancing portion (Type I) as well as the surrounding edema. Large, draining vessels around the mass were very visible on maximum intensity projection (MIP) imaging. Positron emission tomography computed tomography (PET-CT) showed inhomogeneous fluorodeoxyglucose (FDG) uptake with a 2.2–2.9 standardized uptake value (SUV) of the mass without an extra-mammary lesion (Fig. 2). Core needle biopsy of the left breast revealed a combination of the numerous, inter-anastomosing vascular spaces and more solid, spindle-cell areas effacing the normal lobular architecture. On immunohistochemistry, tumor cells are diffusely and strongly positive for CD34 and focally positive for factor VIII. The estimated Ki-67 index in cellular areas is

approximately 40% (Fig. 3). Modified radical mastectomy was performed and the final diagnosis of this patient was intermediate-grade PBA. Following modified radical mastectomy, the patient underwent two cycles of AC (Doxorubicin/Cyclophosphamide) and 12 cycles of Taxol adjuvant chemotherapy and received adjuvant radiotherapy. However, the patient expired after subsequent skin, liver, and spleen metastases developed.

DISCUSSION

Breast sarcomas are a heterogeneous group of malignancy arising from the mammary stroma, and angiosarcoma is the most common sarcoma of the breast. PBA is regarded as a vascular malignancy arising within breast parenchyma with or without minimal extension into overlying skin. It is a very rare, accounting for only 0.04% of all malignancy of breast.

PBA often occurs in young and fertile women between 20 and 50 years of age and who are younger than those with ductal cancer and below the recommended age for mammographic screening. Discoloration of the overlying

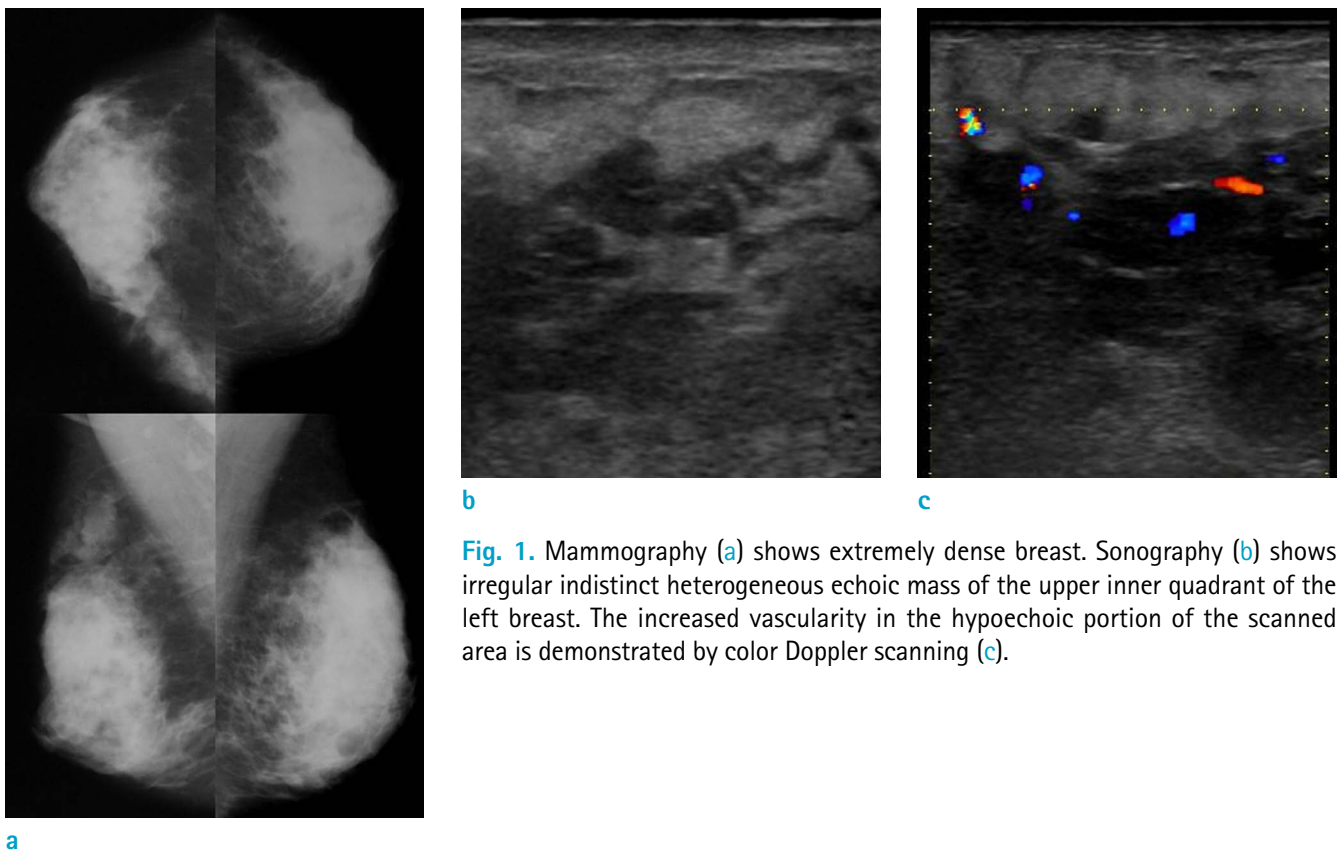


Fig. 1. Mammography (a) shows extremely dense breast. Sonography (b) shows irregular indistinct heterogeneous echoic mass of the upper inner quadrant of the left breast. The increased vascularity in the hypoechoic portion of the scanned area is demonstrated by color Doppler scanning (c).

skin is the most typical sign of PBA, although this only occurs in 17% of all diagnosed cases (5). The PBA may have an insidious clinical onset, presenting as a painless, discrete, palpable mass that grows rapidly. Patients may complain of a painful mass with tenderness. Approximately 2% of patients present with diffuse enlargement of the breast and a bluish discoloration of the skin (6). Generally, discharge and retraction of nipple or axillary node involvement are absent. Some patients are diagnosed during pregnancy or shortly after delivery (7); it is believed that there is a hormonal effect on the development of this disease. However, there are several cases of bilateral tumors diagnosed in postmenopausal period (8).

On mammography, PBA appears as a not circumscribed mass and lacking the spiculations usually seen in ductal origin breast cancer. Rarely, the tumor may show a soap

bubble appearance. They rarely manifest coarse, non-branching microcalcifications (8). PBA could be seen as having focal asymmetry, an oval or lobular mass feature, and rarely there may be skin thickening (1). In many cases of some case reports, PBA was not detected on mammography as in our case. The authors explained the dense breast parenchyma, characteristic of young women could obscure PBAs (1-2, 9).

Sonography usually shows a solid mass that may have well-defined or lobulated margins and with either hypoechoic or hyperechoic appearance. There is often no posterior shadowing (8). PBA can be seen as a complex mass with both cystic and solid regions (10) which can show adjacent tubular structures consistent with vessels (9). Irregular, spiculated hypoechoic masses, overlying skin thickening, and diffuse edematous change also can be seen

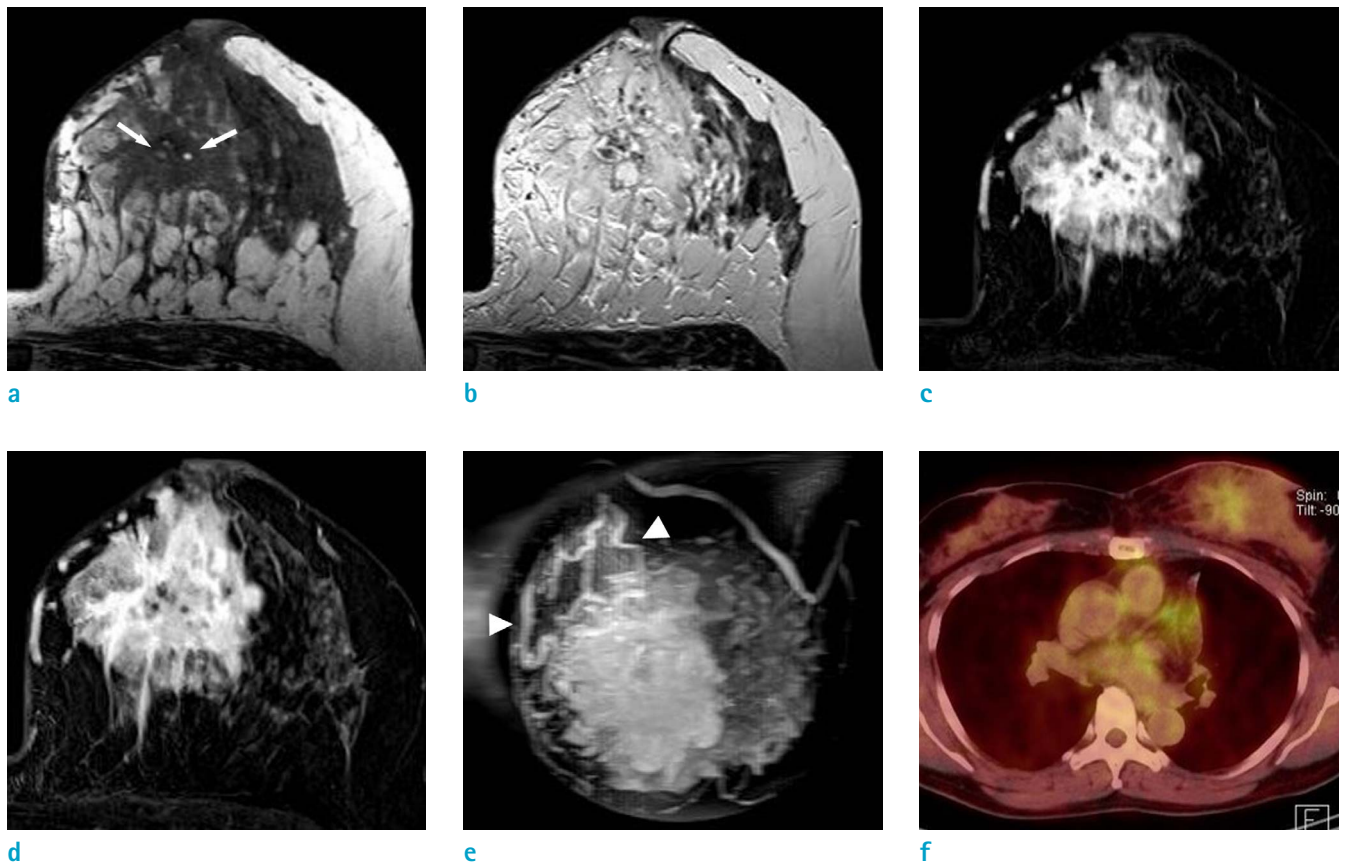


Fig. 2. MRI shows an irregularly shaped, 4.9 × 4.5 cm sized, low signal mass on T1WI (a) and several, dot-like, high signals (arrows), suggesting internal hemorrhagic foci within a mass. The mass shows high signal intensity on T2WI (b). The central portion of the mass shows early dynamic-phase enhancement (c) and a washout pattern on the delayed phase (d). The periphery of the mass shows persistent trapping of contrast medium in the irregular enhancing portion and surrounding edema. Large, draining vessels (arrowheads) around the mass are well seen on MIP imaging (e). PET-CT (f) shows the inhomogeneous FDG uptake (SUV = 2.2-2.9) of the mass.

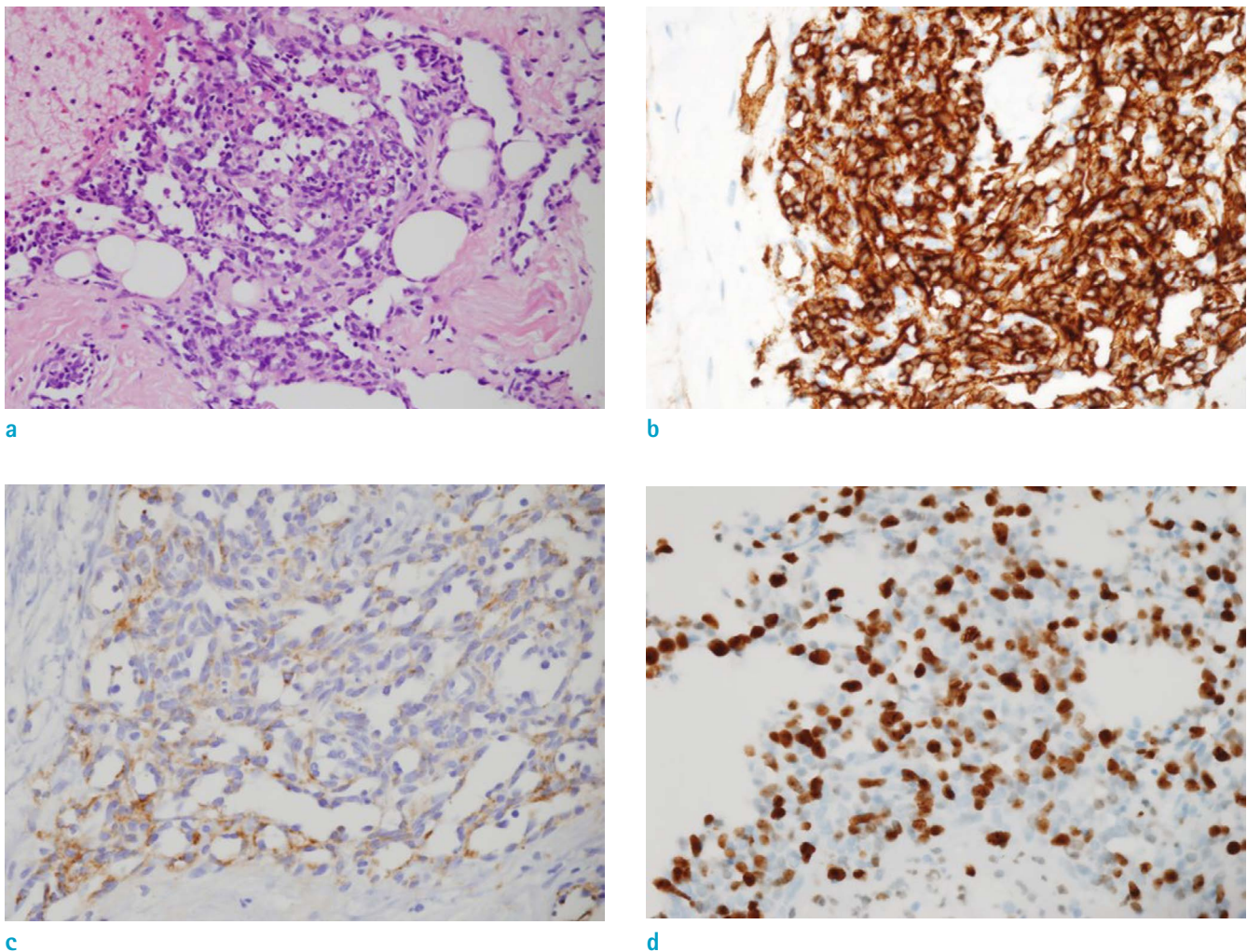


Fig. 3. A photomicrograph shows the combination of the numerous, inter-anastomosing vascular spaces and more solid, spindle-cell areas effacing the normal lobular architecture (Hematoxylin & Eosin staining, $\times 200$) (a). On immunohistochemical staining, tumor cells are diffusely and strongly positive for CD34 (b) and focally positive for factor VIII (c). The estimated Ki-67 index in the cellular areas is approximately 40% ($\times 400$) (d).

(11). In one published study, PBAs were all hypervascular on color Doppler (1).

In clinical practice, when a breast lesion is detected, MRI is the best imaging modality for its characterization. We searched for a published study regarding the MRI findings of PBA. Since Liberman et al. (9) first described the MRI findings for PBA, 10 published articles have shown MRI findings for PBA (Table 1). Based on these articles, most PBAs show irregular shape, poorly defined margin heterogeneous echoic mass with architectural distortion. T1WI shows a low signal, and in areas with a hemorrhagic nature or intratumoral hematoma, T1WI may show a high-signal-intensity focus. T2WI usually has high signal intensity. Slow flowing blood in a large anastomotic

vascular space seems to cause high signal intensity in T2WI. When this structure forms a venous lake, it shows a cystic cavity. The kinetic study is shown in seven out of 10 studies in which a total of 21 patients with PBAs were enrolled. The most frequent type (12) I pattern was in 11 patients, followed by eight patients with the type III pattern and two patients with the type II pattern. The Type I pattern can be defined as trapping of the contrast medium within the anastomotic vascular space. Other findings may include showing a large draining vessel around the tumor (Table 1).

Architectural and kinetic features are valuable for interpreting breast MRI. The specificity of breast MRI could be enhanced by adding information from the DCE study to the architectural features of a lesion. Therefore, assessment

Table 1. MRI Findings of Primary Breast Angiosarcoma in Articles: the Original MRI Descriptions of Each Article were Used

Articles	No. of preop. MRI	No. of MRI presented with images	MRI sequences			
			T1	T2	Dynamic contrast enhancement	Others sequences/ findings
Liberman et al. Radiology 1992 (9)	1	1	Low to intermediate SI (Chest MRI)	SI increased than T1 (Chest MRI)	N/A	Heavily T2 - Tubular areas of the mass, very high SI; vascular channels containing slow flowing blood
Marchant et al. AJR Am J Roentgenol 1997 (10)	2	2	N/A	N/A	N/A	3D gadolinium enhanced fast spoiled gradient echo Right breast - Enhancing mass with irregular borders. Large draining vessel. Cystic cavity within the mass containing blood. Left breast - Mildly irregular contour enhancing mass.
Glazebrook et al. AJR Am J Roentgenol 2005 (14)	1	1	Increased SI of the area of blood lakes (no image)	N/A	N/A	3D fast spoiled gradient echo - Multiple nodular areas of rapid and intense contrast enhancement within the mass. Large draining vein
Yang et al.* Radiology 2007 (1)	6	2	Large, lobulated mass Heterogeneously hypointense Irregularly high SI; hemorrhagic nature Markedly heterogeneous architecture	Heterogeneously hyperintense Cystic cavities representing a venous lake	Intense and heterogeneous enhancement with rapid initial enhancement followed by washout kinetic features	Partially irregular and diffuse infiltration Skin thickening Extension to the pectoralis fascia without invasion
Kim et al. J Korean Surg Soc 2012 (11)	1	1	N/A	N/A	Early rapid enhancement with plateau	
Dashevsky et al.* Radiol Case Rep 2013 (2)	1	1	Smooth, lobulated, hypointense mass	Hyperintense	A rapid rise to the peak with washout	STIR - Increased circumferential signal surrounds the mass: edema
O'Neill et al. J Med Imaging Radiat Oncol 2014 (15)	1	1	Low SI (no image)	High SI (no image)	Irregular, heterogeneous enhancement and plateau kinetics (no Extension to the pectoralis fascia without invasion)	MIP - An area of high signal within low signal parenchyma
Lin et al.* Medicine 2016 (3)	1	1	Center - hyperintensity ; central intratumoral hematoma Periphery - hypointensity ; tumor location	←	Remarkable inhomogeneous enhancement at the periphery (early) Persist pattern of enhancement (delay) Non-enhancement at the center	Large amount of bridging anastomotic vascular spaces at the tumor periphery; trapping of contrast medium
Iacoponi et al. Int J Surg Case Rep 2016 (16)	1	1	N/A	N/A	Type 3 pattern	DWI - Solid and hypervascularized components with significant enhancement High ADC Areas with intratumoral bleeding
Wang et al.* Breast J 2017 (4)	13	1	(10/13) Poorly defined lesions with low SI	High SI	Rapid enhancement (early)	A persistent and prolonged enhancement (late)

*Articles with proper T1, T2, and dynamic contrast enhancement sequences.

ADC = apparent diffusion coefficient; DWI = diffusion-weighted imaging; MIP = maximum intensity projection; N/A = not available; preop. = preoperative; SI = signal intensity; STIR = short-T1 inversion recovery

of all breast lesions should depend not only on architectural but also on kinetic criteria. In this context it can be said that an appropriate evaluation of PBA was made in only four out of 10 studies (1-4). Among them, only five out of 21 cases were presented with figures that can be referenced for the actual radiological diagnosis. Therefore, there has been a total of 10 articles that have described MRI of PBA, however, as there are limitations to referencing them, our case presentation, including our proper MRI setting, is important.

Our case has all of the characteristic MRI findings of PBA presented earlier, although it differs from the previously introduced cases in that the central and the periphery of the mass have different kinetic curves.

PET-CT is useful for confirming preoperative axillary involvement and distant metastasis.

The prognosis of the PBA is similar to other histopathology type of sarcoma and is related to the tumor size, grade, and the status of resection margin (13). Surgical removal followed by adjuvant chemotherapy seems to improve the patient prognosis (7). However, the overall prognosis is poor compared to that of mammary carcinoma. Total mastectomy is mandatory because the PBA often invades microscopically beyond its gross limits, and axillary lymph node dissection is not necessary since nodal metastasis is rare.

In summary, mammography and sonography findings of PBA are indistinguishable from those of other breast malignancies. However, this rare malignancy is distinguished from other malignancies by several characteristic MRI findings, i.e. T2WI high signal intensity, hemorrhage foci at T1WI, and a kinetic curve which could be interpreted as a benign tumor. The center and periphery of the mass could show different DCE kinetics, as was the case in our patient. Draining vein is also a feature of the tumor periphery. A PBA should be included in the differential diagnosis in breast tumors with the MRI findings listed above.

Acknowledgment

I would like to thank Bonnie Hami for her editorial assistance in the preparation of the manuscript.

REFERENCES

1. Yang WT, Hennessy BT, Dryden MJ, Valero V, Hunt KK, Krishnamurthy S. Mammary angiosarcomas: imaging findings in 24 patients. *Radiology* 2007;242:725-734
2. Dashevsky BZ, Charnoff-Katz K, Shin SJ, Babagbemi K, Rosenblatt R. A case of primary breast angiosarcoma. *Radiol Case Rep* 2013;8:741
3. Lin WM, Juan YH, Lin YC, Ueng SH, Lo YF, Cheung YC. Awareness of primary spontaneous hemorrhagic angiosarcoma of the breast associated with Kasabach-Merritt syndrome in a pregnant woman by enhanced magnetic resonance imaging: a CARE-compliant case report. *Medicine (Baltimore)* 2016;95:e5276
4. Wang L, Lao IW, Yu L, Yang W, Wang J. Primary breast angiosarcoma: a retrospective study of 36 cases from a single Chinese medical institute with clinicopathologic and radiologic correlations. *Breast J* 2017;23:282-291
5. Chen KT, Kirkegaard DD, Bocian JJ. Angiosarcoma of the breast. *Cancer* 1980;46:368-371
6. Georgiannos SN, Sheaff M. Angiosarcoma of the breast: a 30 year perspective with an optimistic outlook. *Br J Plast Surg* 2003;56:129-134
7. Bennani A, Chbani L, Lamchahab M, et al. Primary angiosarcoma of the breast: a case report. *Diagn Pathol* 2013;8:66
8. Bhosale SJ, Kshirsagar AY, Patil MV, Wader JV, Nangare N, Patil PP. Primary angiosarcoma of breast: a case report. *Int J Surg Case Rep* 2013;4:362-364
9. Liberman L, Dershaw DD, Kaufman RJ, Rosen PP. Angiosarcoma of the breast. *Radiology* 1992;183:649-654
10. Marchant LK, Orel SG, Perez-Jaffe LA, Reynolds C, Schnall MD. Bilateral angiosarcoma of the breast on MR imaging. *AJR Am J Roentgenol* 1997;169:1009-1010
11. Kim YS, Kim YJ, Yim KI, Park WC. A case report of primary breast angiosarcoma with fatal pulmonary hemorrhage due to thrombocytopenia. *J Korean Surg Soc* 2012;82:251-255
12. Kuhl CK, Mielcareck P, Klaschik S, et al. Dynamic breast MR imaging: are signal intensity time course data useful for differential diagnosis of enhancing lesions? *Radiology* 1999;211:101-110
13. Wang XY, Jakowski J, Tawfik OW, Thomas PA, Fan F. Angiosarcoma of the breast: a clinicopathologic analysis of cases from the last 10 years. *Ann Diagn Pathol* 2009;13:147-150
14. Glazebrook KN, Morton MJ, Reynolds C. Vascular tumors of the breast: mammographic, sonographic, and MRI appearances. *AJR Am J Roentgenol* 2005;184:331-338
15. O'Neill AC, D'Arcy C, McDermott E, O'Doherty A, Quinn C, McNally S. Magnetic resonance imaging appearances in primary and secondary angiosarcoma of the breast. *J Med Imaging Radiat Oncol* 2014;58:208-212
16. Iacoponi S, Calleja J, Hernandez G, Sainz de la Cuesta R. Primary breast angiosarcoma in a young woman. *Int J Surg Case Rep* 2016;24:101-103