



Sequential Bilateral Rapid Destructive Inflammatory Coxarthrosis in a Patient with Human Immunodeficiency Virus

Hyeon Jun Kim, MD, Sung Soo Kim, MD, Su Jin Kim, MD*, Kyung Ho Lee, MD

Department of Orthopedic Surgery, Department of Pathology,
Dong-A University College of Medicine, Busan, Korea*

The diagnostic criteria for sequential rapidly destructive coxarthrosis remain unclear and this condition is rarely reported in patients with human immunodeficiency virus (HIV). Here, we report a case of an HIV-infected 73-year old female who experienced hip joint destruction. The patient was diagnosed with HIV in 2012 (at age 68 years) and began continuous treatment with nucleoside reverse transcriptase and protease inhibitors.

Twenty-nine months after her HIV diagnosis, the patient experienced osteonecrosis of the right hip and underwent a total hip arthroplasty (THA). Twelve months post right-hip THA, X-ray results showed good outcomes. Eight months later (20 months post THA), however, osteolysis of the left femoral head was detected upon radiological exam and THA of the left hip was performed; chronic inflammation and fibrosis were identified in the resultant biopsy. Favorable results were obtained at 3 months after the second surgery.

Key Words: Femur head, Osteonecrosis, Rapidly destructive coxarthrosis, Human immunodeficiency virus

Since its initial appearance in 1985, human immunodeficiency virus (HIV) infection and its late-stage manifestation, the acquired immune deficiency syndrome (AIDS) have affected a growing number of persons in Korea and around the world¹⁾. As of December

2000, more than 1,280 HIV infections and 286 deaths from AIDS in Korea have been reported to the Korean National Institute of Health (Korean Ministry of Health and Welfare, 2000). Whilst degenerative arthritis may be relatively rare in patients with HIV (who are predominantly of a younger age group), osteonecrosis, inflammatory and post-traumatic problems are seen on a regular basis in areas of high HIV seroprevalence. Whether osteonecrosis is an HIV-related complication, an adverse effect of antiretroviral (ARV) therapy or is caused by another HIV-associated condition remains unclear²⁾. The reported estimated incidence of osteonecrosis of femoral head (ONFH) in patients with HIV ranges from 0.45% to 1.33%³⁾, which is greater than in the general population.

Rapidly destructive coxarthrosis (RDC) is a rare condition with an elusive etiology that involves rapid destruction and collapse of the femoral head within 12 months of symptom onset⁴⁻⁶⁾. The joint destruction is typically unilateral, more common in elderly women and manifests with severe

Submitted: September 4, 2017 **1st revision:** December 20, 2017

2nd revision: January 9, 2018 **3rd revision:** January 14, 2018

Final acceptance: January 15, 2018

Address reprint request to

Hyeon Jun Kim, MD

(<https://orcid.org/0000-0002-3775-6421>)

Department of Orthopedic Surgery, Dong-A University Hospital,
26 Daesingongwon-ro, Seo-gu, Busan 49201, Korea

TEL: +82-51-240-2757 **FAX:** +82-51-254-6757

E-mail: hyeonjun@dau.ac.kr

This is an Open Access article distributed under the terms of the Creative Commons Attribution Non-Commercial License (<http://creativecommons.org/licenses/by-nc/4.0>) which permits unrestricted non-commercial use, distribution, and reproduction in any medium, provided the original work is properly cited.

pain in the hip and claudication. In this case, a patient with HIV infection had sequential arthritis of both sides of her hip, with the left side identified 8 months after the right side. An initial radiographic presentation of either normal anatomy or mild arthritis evolves into rapid destruction of the femoral head within months of the onset of clinical manifestations. In the case presented here, we aim to: i) assess and/or identify additional risk factors of ONFH in an HIV-positive patient and determine if these associations may be multifactorial, ii) explore the alleged association of ONFH and ARV, and iii) assess our patient's early response to hip replacement surgery. In HIV-diagnosed patients, joint pain should not be ignored and should always be observed.

CASE REPORT

In April 2015, a 71-year-old female patient was referred to our group for osteopathic care after complaining of right hip pain. This patient was diagnosed with HIV 29 months prior (November 2012; 68-years old) and began a continuous ARV treatment regimen (nucleoside reverse transcriptase [lamivudine] and protease inhibitor cocktail [ritonavir+ darunavir]) at this time. A plain spine radiograph obtained near the time of referral revealed potential osteonecrosis of

the right femoral head. As part of the patient's care for HIV, a medical examination (including a computed tomography scan) was performed 8 months before her referral to our group. We reviewed this assessment and saw no indication of osteonecrosis (Fig. 1). Additionally, the patient had not received steroids since the time of diagnosis with HIV. Following our initial assessment, we recommended a magnetic resonance imaging (MRI) but it was not obtained because of the cost. Clinical (laboratory tests and physical examination) and radiological (pelvic computed tomography with contrast) assessments revealed no signs of infection. Total hip arthroplasty (THA) surgery of the right hip was then performed through a posterolateral approach under general anesthesia and taking all precautions published by AAOS (American Academy of Orthopedic surgeons) for surgery on HIV-positive patients to protect staff against HIV transmission. Specifically, the operating surgeon, two assistants and one scrub nurse wore disposable impervious gowns, helmets with facial shields and a body exhaust system, double hand gloves and impermeable boots. Disposable impervious drapes were used for draping. Instruments contaminated with blood were treated with well-established sterilization methods (e.g., autoclaving) and a 0.5% sodium hypochlorite solution was used to treat any blood spills.

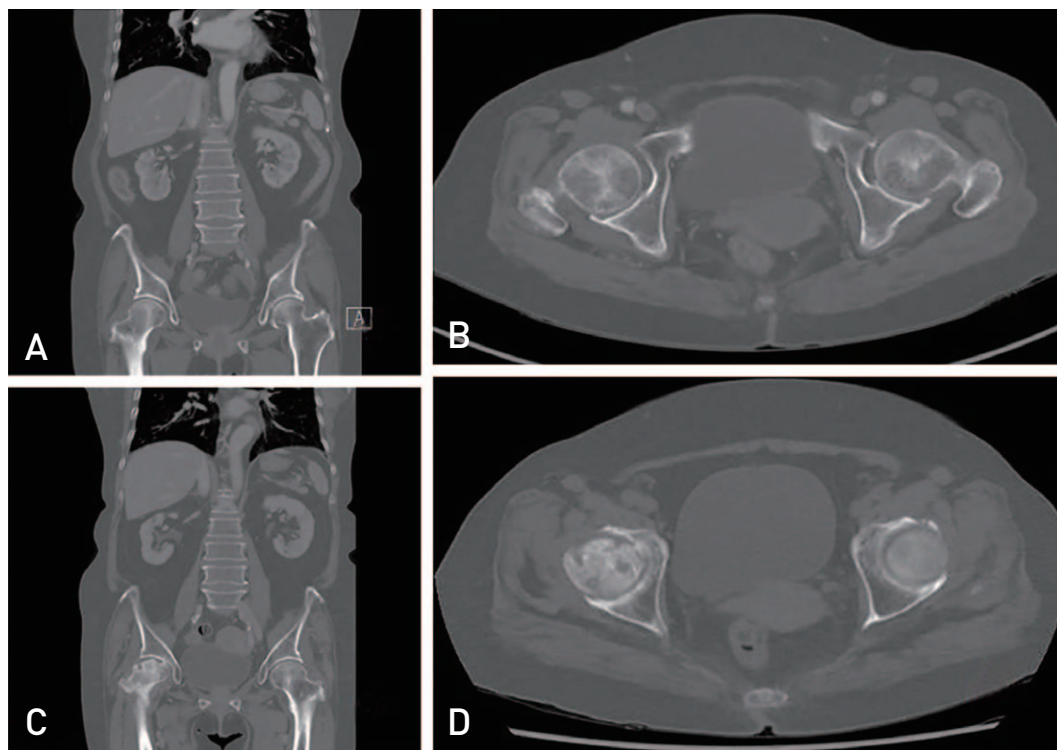


Fig. 1. Initial computed tomography (CT) images are intact; (A) coronal image, (B) axial image. After 8 months, CT images show that femoral head collapse and subchondral bone cysts are formed (C) coronal image, (D) axial image.

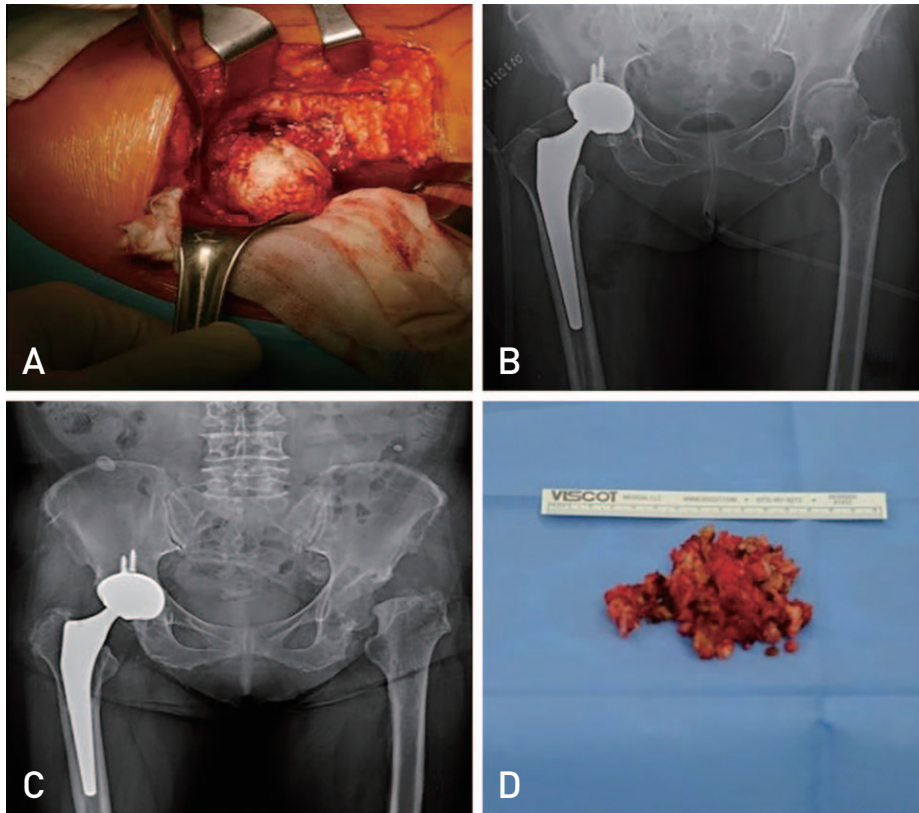


Fig. 2. (A) Intraoperative image shows that femoral head was collapsed. (B) Anteroposterior view of X-ray image shows that right hip joint was changed with implant and right hip joint is intact. The implant was used by Bencox ID stem and cup (Corentec, Seoul, Korea). (C) The follow-up image after 8 months shows that right femoral head was replaced by implant and left femoral head was collapsed. (D) Removed soft tissue and femoral head show that inflammatory change.

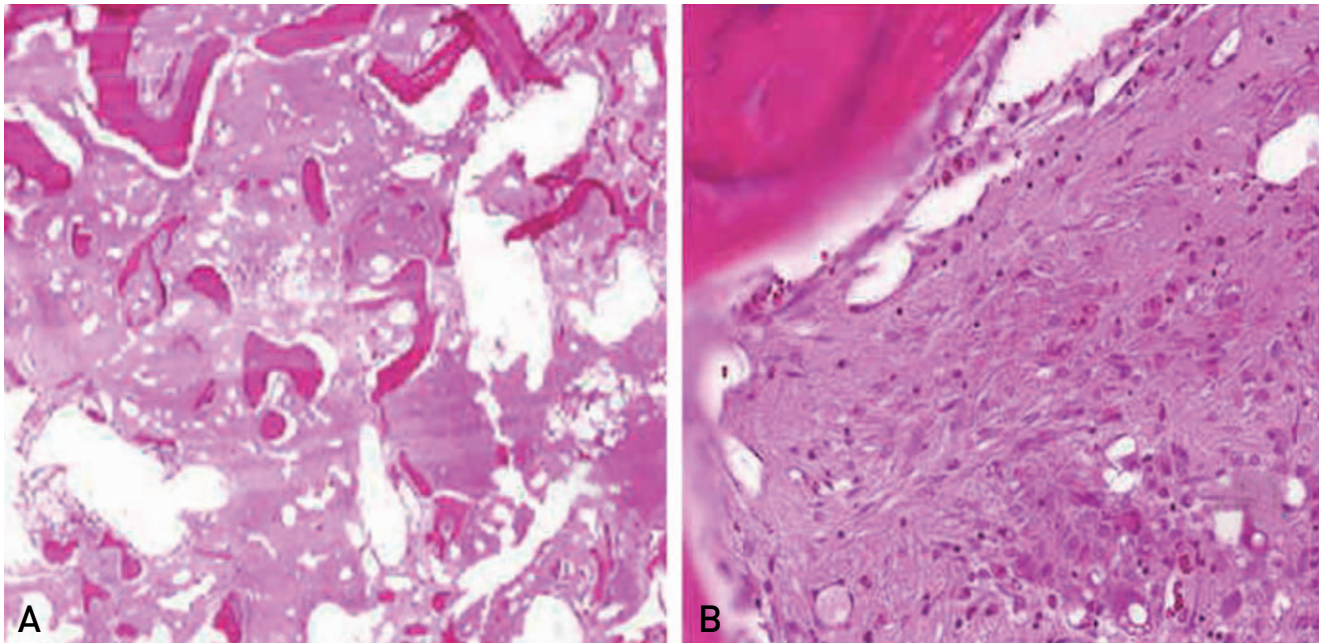


Fig. 3. (A) The femur head shows diffuse destructive architecture with dense fibrotic change (H&E stain, $\times 40$). (B) On high magnification, the bone is necrotic (left upper portion) and marrow space shows fibrosis and chronic inflammatory cells infiltration (right lower portion) (H&E stain, $\times 200$).

Intraoperative finding revealed femoral head collapse consistent with common osteonecrosis (Fig. 2A). The anteroposterior view of an X-ray image confirmed repair of the right hip joint with implant and an intact left hip joint is intact. Bencox ID stem and cup (Corentec, Seoul, Korea) were used (Fig. 2B). The test results for intraoperative bacterial identification was negative, and no signs of infection were observed during outpatient follow-up. No complications were apparent through the 12-month follow up; however, the patient began experiencing left hip pain 17 months after the right-hip THA. Three months later (20 months post right-hip THA), an X-ray revealed loss of the left femoral head (Fig. 2C). A THA of the left hip was then performed using the same technique described above. Intraoperative results revealed more severe femoral head loss and osteolysis of the left hip compared with the right hip, but no signs of infection were observed (Fig. 2D). Furthermore, intraoperative tests for bacteria were negative. Non-specific findings revealing chronic inflammation and fibrotic changes were identified upon histological exam (Fig. 3). No clinical or radiologic manifestations were present 3 months following the second THA (Fig. 4).

DISCUSSION

RDC was first described in 1970 by Postel and Kerboul⁷⁾. This idiopathic condition usually involves unilateral joint destruction and progressive hip pain that evolves into rapid destruction of the femoral head despite a relatively preserved

range of motion, within several months of symptom onset. The exact etiology of RDC is unknown; however, a number of proposed etiological theories have been published. Several authors have alluded to an association between ARV drugs—particularly protease inhibitors—and the onset of RDC²⁾. Additional proposed factors associated with RDC include rheumatoid arthritis, deposition of hydroxyapatite or calcium phosphate crystals, and the use of anti-inflammatory drugs (e.g., indomethacin)⁸⁾.

Yoo et al.⁹⁾ suggest that RDC could be a subtype of femoral head osteonecrosis since insignificant histological differences in hip cartilage was observed between osteonecrosis and 29 cases of RDC. In our case report, histological examination revealed fibrosis and chronic inflammation, conditions that may be associated with osteonecrosis of the femoral head.

HIV patients commonly complain of arthralgia and are likely to have localized osteoporosis, fractures and/or fat embolisms due to the long-term use of corticosteroids that may lead to vascular occlusion¹⁰⁾. Because multiple arthralgias are common among this patient population, there is a risk of overlooking other potential complications such as avascular necrosis or rapid-destruction arthropathy. Early diagnosis with a highly sensitive tool (e.g., MRI) is recommended. In this case report, the patient was a 73-year old HIV positive woman with no known comorbidities and no history of alcohol consumption or steroid use. Our patient was subjected to prolonged use of antiviral medications—treatments that are associated with an increased risk of femoral head osteonecrosis compared with healthy patients. The patient was later diagnosed with RDC based on X-rays which showed femoral head loss 8 months after symptom onset. A limitation in our case report is that MRI scans were not obtained due to financial restrictions.

The rapid onset of femoral head loss (i.e., within several months of symptom onset) in the present case report distinguishes it from typical femoral head osteonecrosis. The multiple arthralgias that often afflict patients with HIV require pain control and accurate diagnosis with X-ray and MRI. In addition, careful assessment of radiographs taken during follow-up is required. Surgery should be considered as a treatment option for patients with arthralgias, and may help lead to accurate diagnosis and clarify etiology.

CONFLICT OF INTEREST

The authors declare that there is no potential conflict of interest relevant to this article.

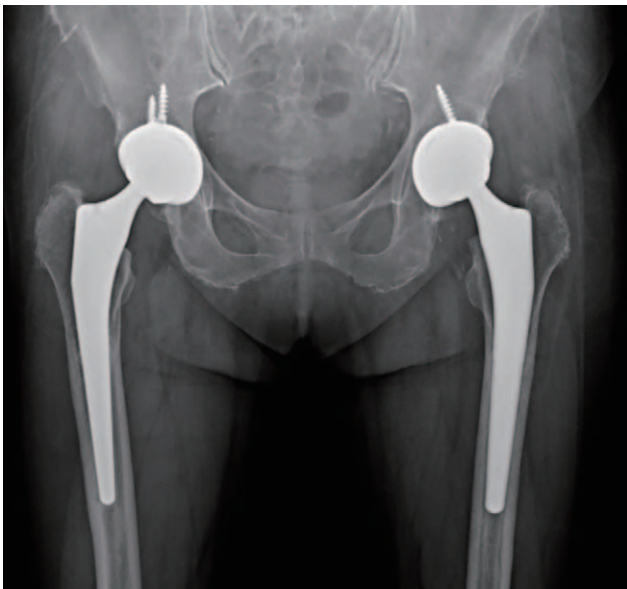

Fig. 4. Anteroposterior view of after 3 months follow-up image shows implant fixation state.

REFERENCES

1. UNAIDS/WHO global AIDS statistics. *AIDS Care*. 1999; 11:253-64.
2. Gutiérrez F, Padilla S, Masiá M, et al; HIV-related Osteonecrosis Study Group. *Osteonecrosis in patients infected with HIV: clinical epidemiology and natural history in a large case series from Spain. J Acquir Immune Defic Syndr*. 2006;42:286-92.
3. Matos MA, Alencar RW, Matos SS. Avascular necrosis of the femoral head in HIV infected patients. *Braz J Infect Dis*. 2007;11:31-4.
4. Deshayes P, Thomine JM, Hemet J, Seruzier E, Biga N, Ducastelle C. [Hip diseases with rapid chondrolysis. Clinical and anatomical comparison]. *Rev Rhum Mal Osteoartic*. 1975;42:345-53. French.
5. Rosenberg ZS, Shankman S, Steiner GC, Kastenbaum DK, Norman A, Lazansky MG. Rapid destructive osteoarthritis: clinical, radiographic, and pathologic features. *Radiology*. 1992;182:213-6.
6. Komiya S, Inoue A, Sasaguri Y, Minamitani K, Morimatsu M. Rapidly destructive arthropathy of the hip. Studies on bone resorptive factors in joint fluid with a theory of pathogenesis. *Clin Orthop Relat Res*. 1992;(284):273-82.
7. Postel M, Kerboull M. Total prosthetic replacement in rapidly destructive arthrosis of the hip joint. *Clin Orthop Relat Res*. 1970;72:138-44.
8. Allison GT, Bostrom MP, Glesby MJ. *Osteonecrosis in HIV disease: epidemiology, etiologies, and clinical management. AIDS*. 2003;17:1-9.
9. Yoo MC, Lee SH, Cho YJ, Kim YH, Lee YS, Kang CH. Rapidly destructive coxarthrosis. *J Korean Orthop Assoc*. 1997;32:1566-74.
10. Glesby MJ, Hoover DR, Vaamonde CM. *Osteonecrosis in patients infected with human immunodeficiency virus: a case-control study. J Infect Dis*. 2001;184:519-23.