

제5중족골 피로골절의 형태 분석: 시상면 및 관상면상의 위치

이경태 정형외과¹, 을지대학교 의과대학 정형외과학교실 족부클리닉², 아주대학교 의과대학 정형외과학교실³

이경태¹ · 양기원² · 박영욱³ · 제갈혁¹ · 서정현³

Morphologic Analysis of the Fifth Metatarsal Stress Fracture: The Precise Coronal and Sagittal Location

Kyung Tai Lee¹, Ki Won Young², Young Uk Park³, Hyuk Jegal¹, Jeong Hyun Seo³

¹Foot and Ankle Service, KT Lee's Orthopedic Hospital, Seoul, ²Foot and Ankle Clinic, Department of Orthopedic Surgery, Eulji Medical Center, Eulji University School of Medicine, Seoul, ³Department of Orthopedic Surgery, Ajou University Hospital, Ajou University School of Medicine, Suwon, Korea

From a biomechanical standpoint, the main pathologic abnormality of fifth metatarsal stress fracture is the location where repetitive tensile stress concentrated. Decreasing tensile force in this region would be a proper treatment. Therefore, the purpose of this study is to evaluate the precise sagittal and coronal location of the fifth metatarsal stress fracture. Between June 2012 and May 2013, 38 athletes with a fifth metatarsal stress fracture were treated. To evaluate the precise sagittal location of the fracture, the entire length of the fifth metatarsal was measured and the distance from tuberosity to the fracture line was measured. To evaluate the precise coronal location of the fractures, coronal computed tomography images were obtained for incomplete fracture cases. The fracture location was classified as four quadrants. Thirty patients were classified into zone III fracture. However, the fracture is located in zone II for remaining eight cases. The median value of ratio between whole length and the distance from tuberosity to the fracture was 0.35 (range, 0.29-0.40). Among 33 incomplete fracture cases, there were 28 patients whose fracture developed in plantolateral quadrant, four patients at the lateral side and a patient for plantar side. The main pathologic abnormality is at the plantar lateral side because of the repetitive stress concentrated there.

Keywords: Metatarsal bones, Fracture, Stress

Received: August 26, 2016 Revised: October 29, 2016 Accepted: November 1, 2016

Correspondence: Young Uk Park

Department of Orthopedic Surgery, Ajou University Hospital, Ajou University School of Medicine, 164 Worldcup-ro, Yeongtong-gu, Suwon 16499, Korea

Tel: +82-31-219-5220, Fax: +82-31-219-5229

E-mail: parkyounguk@gmail.com

Copyright ©2016 The Korean Society of Sports Medicine

© This is an Open Access article distributed under the terms of the Creative Commons Attribution Non-Commercial License (<http://creativecommons.org/licenses/by-nc/4.0>) which permits unrestricted non-commercial use, distribution, and reproduction in any medium, provided the original work is properly cited.

Introduction

There has been much controversy and confusion regarding fractures of the proximal fifth metatarsal since 1902, when Sir Robert Jones¹⁾ first reported a series of four such cases, including his own injury.

Quill²⁾ proposed a useful classification for the fracture patterns that occur in the proximal fifth metatarsal. The classification scheme divides fractures in this region of the foot into tuberosity avulsion fractures, acute Jones fractures, and proximal diaphyseal stress fractures. The fifth metatarsal stress fractures were reported to develop in proximal diaphysis as zone III. He reported that each of these fracture patterns has its own mechanism of injury, specific location, treatment options, and prognosis regarding delayed union and nonunion. However, Zwitter and Breederveld³⁾ reported that the distinction between Jones and proximal diaphyseal fractures is often difficult because of their close anatomic proximity. Although reports in the literature have indicated the potential difficulties in the treatment of Jones fractures, prevailing guidelines for their management are ambiguous. It is important to note that zone II fracture could be a metatarsal stress fracture.

Intramedullary screw fixation has become a most popular method for the surgical management of Jones fractures. However, it is criticized that it is not a causal treatment. From a biomechanical standpoint, the main pathologic abnormality of fifth metatarsal stress fracture is the location where repetitive tensile stress concentrated⁴⁾. Therefore, it is important to decrease tensile force in this region by conservative means such as using insole or to change tensile force into compressive force by surgical means like tension band wiring in the treatment of fifth metatarsal stress fracture^{5,6)}.

Therefore, the purpose of this study is to evaluate the precise sagittal and coronal location of the fifth metatarsal stress fracture.

Methods

Approval from our Institutional Review Board was obtained. Between June 2012 and May 2013, 38 patients (all males) with a fifth metatarsal stress fracture were treated using modified tension band wiring. This consecutive series of patients had a mean age 19.3 years (range, 14 to 29 years) at surgery⁷⁾. Among the 38

cases, 13 were right-sided and 25 were left-sided. Thirty-four patients were soccer players, one patient was a boxer, one a handball player, and two were basketball players. There were two cases of Torg type I, 34 cases of type II, and two cases of type III. According to the classification by Lee et al.⁵⁾, there were two type A1, three type A2, 25 type B1, and eight type B2. All patients were treated using modified tension band wiring, and inlay bone grafting in cases with Torg's type III or Lee's type B2 fractures^{5,8)}.

All subjects underwent anteroposterior, lateral, and 30-degree medial oblique radiographs of the feet. In addition, preoperative computed tomography (CT) scan was routinely performed to view fracture pattern and to evaluate coronal location of the fracture.

First, all the cases were classified according to Quill²⁾. Therefore, they were divided into tuberosity avulsion fractures (zone I), Jones fractures (zone II), and proximal diaphyseal stress fractures (zone III).

To evaluate the precise sagittal location of the fracture, the whole length of the fifth metatarsal was measured on a 30-degree internal oblique view. The distance from tuberosity to the fracture line was measured. The ratio between the entire length and the distance from tuberosity to the fracture was calculated (Fig. 1).

To evaluate the precise coronal location of the fracture, coronal CT images were obtained for incomplete fracture cases. For complete fracture cases, the fracture line was extended into medial cortex. Therefore, it was impossible to locate the osteolytic fracture region. However, for an incomplete fracture, the osteolytic fracture is located in specific region where the pathologic process has begun. Therefore, we limited the cases of incomplete fracture to evaluate the coronal location of the fifth metatarsal stress fracture. We chose one section of the coronal image that the largest seen osteolytic fracture region. The fracture location was classified into four quadrant as dorsomedial, dorsolateral, plantomedial, and plantolateral. When it is located between two quadrants, it was regarded as dorsal, plantar, medial or lateral. The quadrant was made as a reference to the line that is formed between the most inferior margin of the first metatarsal and fifth metatarsal (Fig. 2).

Results

Thirty patients were classified with zone III fractures. The

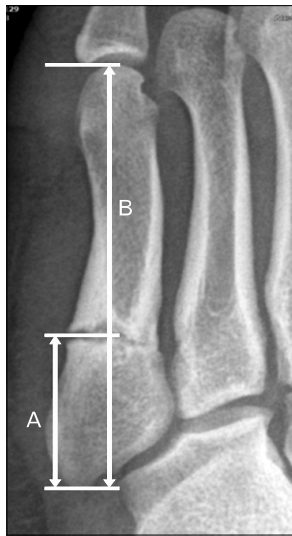

Fig. 1. The entire length of the fifth metatarsal was measured on a 30-degree internal oblique view. The distance from tuberosity to the fracture line was measured. The ratio between the entire length and the distance from tuberosity to the fracture (A, B) were calculated.

fracture line was limited to the proximal diaphyseal region for those patients. However, the fracture was located in zone II for the remaining eight cases. The fracture line was extended into fourth-fifth intermetatarsal articulation in five cases. The fracture line was limited in zone II even though there was no extended fracture line into medial cortex for three incomplete fracture cases.

The average whole length of the fifth metatarsal on 30-degree internal oblique view was 87.4 ± 5.9 . The average distance from tuberosity to the fracture line was 30.2 ± 2.8 . The median value of ratio between the entire length and the distance from tuberosity to the fracture was 0.35 (range, 0.29–0.40).

Among 33 incomplete fracture cases, fracture developed in plantolateral quadrant in 28 patients. In addition, there were four patients at the lateral side and a patient for the plantar side. There was no patient having the osteolytic fracture region in dorsal or medial side.

Discussion

The distinction between Jones and proximal diaphyseal fractures of the fifth metatarsal is confusing for many surgeons. A Jones fracture currently is defined as an acute fracture of the fifth metatarsal at the junction between the proximal diaphysis and

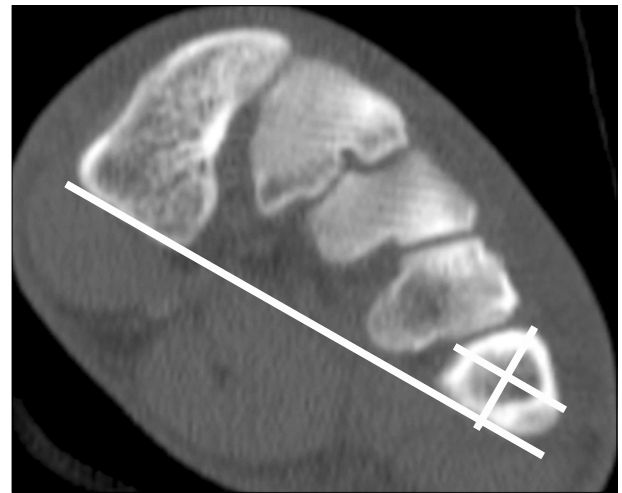


Fig. 2. The fracture location was classified into four quadrants: dorsomedial, dorsolateral, plantomedial, and plantolateral. The quadrant was made as a reference to the line formed between the most inferior margin of the first metatarsal and the fifth metatarsal. The second line was drawn parallel to this line centered to the fifth metatarsal center. The third line was drawn perpendicular to the second line centered to the fifth metatarsal.

metaphysis of the fifth metatarsal without distal extension beyond the fourth to fifth intermetatarsal articulation⁹⁾. The mechanism of injury is believed to be an abduction force applied to the forefoot with simultaneous ankle plantar flexion^{10,11)}. A proximal diaphyseal fifth metatarsal stress fracture is defined as a stress fracture in the zone of the proximal fifth metatarsal immediately distal to the Jones fracture's anatomic area¹²⁾. The mechanism of this injury is believed to be a repetitive load applied under the metatarsal head over a relatively short time, resulting in an overuse phenomenon. However, Polzer et al.¹³⁾ reported in their review article that it is not necessary to differentiate between these two diagnoses. Chuckpaiwong et al.¹⁴⁾ also reported that they did not find a reason to distinguish between fractures of the fifth metatarsal in these two locations. They suggest referring to fifth metatarsal base fractures (excluding avulsions) as Jones fractures. The results in our patients are similar to results of patients reported in their studies^{13,14)}. In this study, in many of the patients (30/38) the fractures developed in zone III. But, there were no patients whose fracture developed in zone I. We observed that in 21% (8/38) of the patients, the fractures were located in zone II. Therefore, there is no meaning to differentiate the stress fractures based on their anatomic location into Zone II

or Zone III. Regardless of zonal classification, the sagittal location of the fracture is the 35th percentile (range, 29–40) area from tuberosity for the entire length of the fifth metatarsal.

There have been many reports about sagittal location of the fifth metatarsal stress fracture and fracture of the fifth metatarsal base^{2,3,10,14-21}). To our knowledge, there is no report of coronal location of the fifth metatarsal stress fracture. According to Lee et al.⁴⁾, patients with a wide plantar gap preoperatively usually do not have a good outcome; they require more time for bone union and have complications more frequently. The plantar gap was defined as the distance between the fracture margins seen on a standard oblique X-ray view of the foot that showed the plantar lateral side of the fifth metatarsal⁵⁾. However, it was based on simple X-ray. This study is the first report of coronal location of the fifth metatarsal stress fracture using CT analysis.

We observed that osteolytic fracture region was located in the plantolateral quadrant on coronal CT image for all of the incomplete fifth metatarsal fracture. In addition, there was no patient for which the osteolytic fracture region was located in dorsal or medial side. This observation could be an evidence of the plantar gap. This is the region where tensile force is concentrated. The plantar lateral side is displaced more because of tension forces. On the other hand, the dorsomedial side is not displaced due to compressive forces. An increase in the stress reaction to repetitive tensile forces in this region can cause the gap to expand, and this might be correlated with a poor prognosis⁴⁾.

Strategies for operative intervention include intramedullary screw fixation, bone grafting, and tension band wiring. Intramedullary screw fixation has become a popular method for the surgical management of Jones fractures, and several reports have described increased union rates and rapid recovery^{16,17,22)}. However, many recent reports have described failures after screw fixation in athletes^{3,6,23-26)}. In the literature, the tension band wiring technique has been mentioned as an alternative method for treating proximal fractures of the fifth metatarsal^{6,11,20,27,28)}. For such reasons of this study and from a biomechanical standpoint, the main pathologic abnormality is at the plantar lateral side because of the repetitive stress concentrated there. Therefore, it is important to decrease tensile force in this region by conservative means such as using insole or to change tensile force into compressive force by surgical means like tension band wiring in the treatment of fifth metatarsal

stress fracture.

Limitations of this study is that we did not have a choice to use weight-bearing CT. Instead, we routinely draw a line that is formed between the most inferior margin of the first metatarsal and fifth metatarsal. This line is not parallel to the sole, but it is thought to be enough to divide the fifth metatarsal into four quadrants.

In conclusion, the fifth metatarsal stress fracture was not limited in zone III, but zone II. The precise sagittal location of the fracture is distally 35 percentiles (range, 29–40) area from tuberosity for whole length of the fifth metatarsal. The precise coronal location of the fracture is plantar and lateral side of the bone. According to this, the main pathologic abnormality is at the plantar lateral side because of the repetitive stress concentrated there. Therefore, it is important to decrease tensile force in this region.

Conflict of Interest

No potential conflict of interest relevant to this article was reported.

References

1. Jones R. I: fracture of the base of the fifth metatarsal bone by indirect violence. *Ann Surg* 1902;35:697-700.
2. Quill GE Jr. Fractures of the proximal fifth metatarsal. *Orthop Clin North Am* 1995;26:353-61.
3. Zwitter EW, Breederveld RS. Fractures of the fifth metatarsal; diagnosis and treatment. *Injury* 2010;41:555-62.
4. Lee KT, Park YU, Young KW, Kim JS, Kim JB. The plantar gap: another prognostic factor for fifth metatarsal stress fracture. *Am J Sports Med* 2011;39:2206-11.
5. Lee KT, Park YU, Jegal H, Park JW, Choi JP, Kim JS. Prognostic classification of fifth metatarsal stress fracture using plantar gap. *Foot Ankle Int* 2013;34:691-6.
6. Lee KT, Young KW, Park SY, Lee YK, Na SE. Surgical results of 5th metatarsal stress fracture using two cortical screws and wire determining of time of return to full sports activity in soccer players. *Korean J Sports Med* 2009;27:14-8.
7. Magnan B, Bragantini A, Regis D, Bartolozzi P. Metatarsal lengthening by callotaxis during the growth phase. *J Bone Joint Surg Br* 1995;77:602-7.
8. Torg JS, Balduini FC, Zelko RR, Pavlov H, Peff TC, Das M.

- Fractures of the base of the fifth metatarsal distal to the tuberosity: classification and guidelines for non-surgical and surgical management. *J Bone Joint Surg Am* 1984;66:209-14.
9. Lawrence SJ, Botte MJ. Jones' fractures and related fractures of the proximal fifth metatarsal. *Foot Ankle* 1993;14:358-65.
10. Dameron TB Jr. Fractures and anatomical variations of the proximal portion of the fifth metatarsal. *J Bone Joint Surg Am* 1975;57:788-92.
11. Rosenberg GA, Sfera JJ. Treatment strategies for acute fractures and nonunions of the proximal fifth metatarsal. *J Am Acad Orthop Surg* 2000;8:332-8.
12. Dameron TB Jr. Fractures of the proximal fifth metatarsal: selecting the best treatment option. *J Am Acad Orthop Surg* 1995;3:110-4.
13. Polzer H, Polzer S, Mutschler W, Prall WC. Acute fractures to the proximal fifth metatarsal bone: development of classification and treatment recommendations based on the current evidence. *Injury* 2012;43:1626-32.
14. Chuckpaiwong B, Queen RM, Easley ME, Nunley JA. Distinguishing Jones and proximal diaphyseal fractures of the fifth metatarsal. *Clin Orthop Relat Res* 2008;466:1966-70.
15. Carp L. Fracture of the fifth metatarsal bone: with special reference to delayed union. *Ann Surg* 1927;86:308-20.
16. Clapper MF, O'Brien TJ, Lyons PM. Fractures of the fifth metatarsal: analysis of a fracture registry. *Clin Orthop Relat Res* 1995;(315):238-41.
17. DeLee JC, Evans JP, Julian J. Stress fracture of the fifth metatarsal. *Am J Sports Med* 1983;11:349-53.
18. Hatch RL, Alsobrook JA, Clugston JR. Diagnosis and management of metatarsal fractures. *Am Fam Physician* 2007;76:817-26.
19. Hens J, Martens M. Surgical treatment of Jones fractures. *Arch Orthop Trauma Surg* 1990;109:277-9.
20. Hulkko A, Orava S, Nikula P. Stress fracture of the fifth metatarsal in athletes. *Ann Chir Gynaecol* 1985;74:233-8.
21. Zelko RR, Torg JS, Rachun A. Proximal diaphyseal fractures of the fifth metatarsal: treatment of the fractures and their complications in athletes. *Am J Sports Med* 1979;7:95-101.
22. Kavanaugh JH, Brower TD, Mann RV. The Jones fracture revisited. *J Bone Joint Surg Am* 1978;60:776-82.
23. Glasgow MT, Naranja RJ Jr, Glasgow SG, Torg JS. Analysis of failed surgical management of fractures of the base of the fifth metatarsal distal to the tuberosity: the Jones fracture. *Foot Ankle Int* 1996;17:449-57.
24. Hunt KJ, Anderson RB. Treatment of Jones fracture nonunions and refractures in the elite athlete: outcomes of intramedullary screw fixation with bone grafting. *Am J Sports Med* 2011;39:1948-54.
25. Josefsson PO, Karlsson M, Redlund-Johnell I, Wendeberg B. Jones fracture: surgical versus nonsurgical treatment. *Clin Orthop Relat Res* 1994;(299):252-5.
26. Wright RW, Fischer DA, Shively RA, Heidt RS Jr, Nuber GW. Refracture of proximal fifth metatarsal (Jones) fracture after intramedullary screw fixation in athletes. *Am J Sports Med* 2000;28:732-6.
27. Mindrebo N, Shelbourne KD, Van Meter CD, Rettig AC. Outpatient percutaneous screw fixation of the acute Jones fracture. *Am J Sports Med* 1993;21:720-3.
28. Sarimo J, Rantanen J, Orava S, Alanen J. Tension-band wiring for fractures of the fifth metatarsal located in the junction of the proximal metaphysis and diaphysis. *Am J Sports Med* 2006;34:476-80.