

잠수병에 의한 폐부종

이화여자대학교 의과대학 이대목동병원 영상의학교실

이소원 · 심성신 · 최진하 · 김유경

Pulmonary Involvement in Decompression Sickness of a Self Contained Underwater Breath Apparatus Diver

So Won Lee, Sung Shine Shim, Jinha Choi, Yookyung Kim

Department of Radiology, Ewha Womans University Mokdong Hospital, Ewha Womans University School of Medicine, Seoul, Korea

Decompression sickness is a self contained underwater breath apparatus (SCUBA)-related injury with various symptoms and is considered an extreme emergency condition. This is a case of pulmonary involvement in decompression sickness in a 26-year-old SCUBA diver. Although pulmonary involvement in decompression sickness is a potentially severe condition that requires immediate treatment, this condition can be under- or misdiagnosed, and evaluation of this disease by imaging findings is not clearly understood. We experienced a case of pulmonary involvement in decompression sickness and herein present the chest computed tomography and simple radiograph findings associated with this condition.

Keywords: Self contained underwater breath apparatus diving, Dyspnea, Decompression sickness

Introduction

Currently, it is estimated that there is more than 300,000 self contained underwater breath apparatus (SCUBA) divers in Korea with increase of approximately 20,000 divers per year. The two most important and often life-threatening SCUBA-related injuries

are decompression sickness (DCS) and arterial gas embolism (AGE). These injuries are often referred to as decompression illness^{1,2)}. The signs and symptoms of DCS are extremely variable and include the bends (pain most often in or near a joint), neurologic manifestations of almost any degree, and the chokes (respiratory distress followed by circulatory collapse-an extreme emergency). These signs and symptoms occur alone or with other symptoms^{3,4)}. Because this condition is usually an emergency, radiologists, and clinicians should be aware of the clinical symptoms and the appearance of this potentially lethal disease on imaging studies. Initial prompt recognition and proper treatment of an injured diver can save a life.

Received: March 27, 2013 Revised: May 16, 2013

Accepted: May 19, 2013

Correspondence: Sung Shine Shim

Department of Radiology, Ewha Womans University Mokdong Hospital, Ewha Womans University School of Medicine, 1071 Anyangcheon-ro, Yangcheon-gu, Seoul 158-710, Korea

Tel: +82-2-2650-5380, Fax: +82-2-2650-8891

E-mail: sinisim@ewha.ac.kr

Copyright ©2013 The Korean Society of Sports Medicine

© This is an Open Access article distributed under the terms of the Creative Commons Attribution Non-Commercial License (<http://creativecommons.org/licenses/by-nc/3.0>) which permits unrestricted non-commercial use, distribution, and reproduction in any medium, provided the original work is properly cited.

Case Report

A 26-year-old woman presented to the emergency room with

a sudden onset of mild dyspnea and a cough producing pink sputum. She denied any chest pain, fever, chilling, arthralgia, tingling sensation, dizziness, or water aspiration. History obtained from the patient showed that 1 day before this event, she had been SCUBA diving at a depth of approximately 23 m of saltwater and had ascended rapidly. She had a history of an anxiety disorder without recent medication and a smoking history (1 pack daily for 6 years). She was an otherwise healthy woman without additional medical or surgical history. Her physical examination was normal except for slightly decreased breath sounds at the lung base. Her vital signs were stable: temperature, 36.5°C; blood pressure, 120/80 mm Hg; heart rate, 102 beats/min; and respiratory

rate, 27 breaths/min. Cardiac examination demonstrated normocardia with a regular rhythm.

An initial chest radiograph and chest computed tomography (CT) scan were performed. Initial chest radiography (Fig. 1) showed faint patchy consolidations and ground-glass opacities (GGO) in both lower lung zones. The possibility of pneumonia including *Mycoplasma* infection, pulmonary edema, and pulmonary endometriosis were considered, and further evaluation by CT was recommended. On the chest CT scan (Fig. 2), GGO and consolidations in the right middle lobe, both lower lobes, and a small portion of the right upper lobe were observed. No hypertrophied bronchial arteries were seen in the mediastinum. Stable pulmonary tuberculosis with calcified granulomas in the left upper lobe was seen. No abnormalities were detected in the large airways, mediastinum, or pleural or chest walls. Laboratory examination revealed a white blood cell (WBC) count of $7.5 \times 10^3/\text{mm}^3$, hematocrit of 38.0%, hemoglobin of 12.3 g/dL, platelet count of $234,000/\text{mm}^3$ and erythrocyte sedimentation rate of 2 mm/hr. Arterial blood gas analysis was: PH 7.46, partial pressure of carbon dioxide 35.1 mm Hg, partial pressure of oxygen 82.8 mm Hg, and oxygen saturation 94.5%. Serum chemistry values were all normal: blood urea nitrogen/creatinine 12.0/0.7 mg/dL, aspartate aminotransferase/alanine aminotransferase 25/9 units/L, glucose 99 mg/dL, and C-reactive protein 0.83 mg/dL. Blood tests including serologic studies to exclude conditions that can cause pulmonary

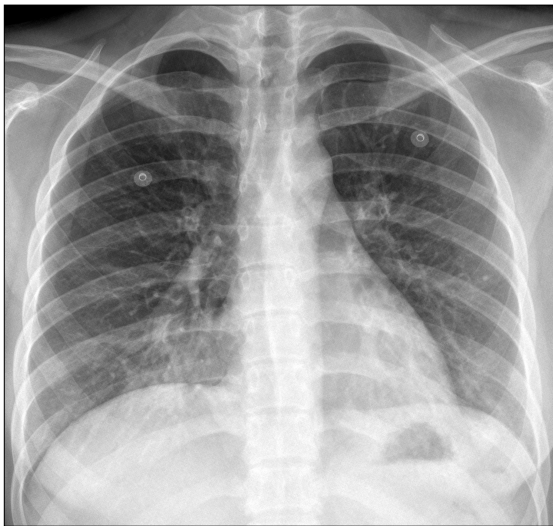


Fig. 1. Initial chest radiography shows patchy increased opacities in both lower lung zones.

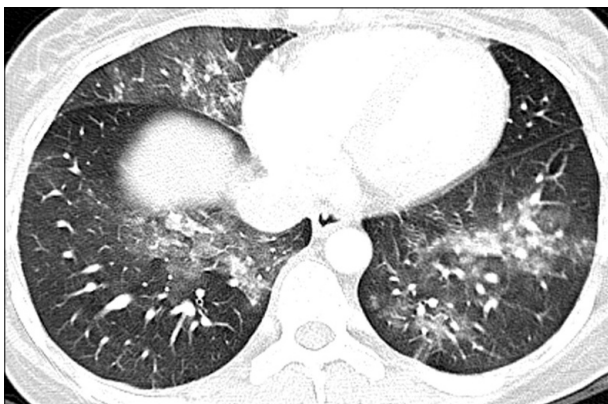


Fig. 2. Chest computed tomography scan shows patchy ground-glass opacities in the right-middle lobe, both lower lobes, and a small portion of the right-upper lobe.

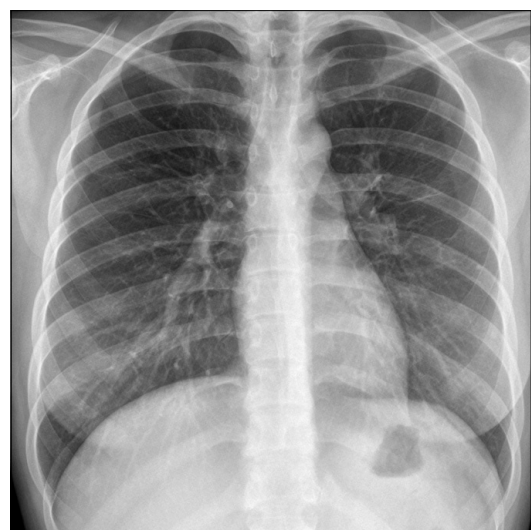


Fig. 3. Chest radiography obtained 4 days after that presented in Fig. 1 shows complete resolution of pulmonary edema.

hemorrhage such as a vasculitis or collagen vascular disease were within normal limits: fluorescent antinuclear antibody of negative, rheumatoid factor of 8.2 units/mL, and complement C₃ level of 95.5 mg/dL and C₄ of 23.0 mg/dL. Serological test for anti-Mycoplasma IgM antibody was negative at 638.5 U/mL and anti-Mycoplasma IgM/IgG titer was 1.1. Urinary analysis was PH of 6.0 and there was no free hemoglobin or WBC.

Pulmonary involvement of decompression sickness was suspected, and the patient was prescribed a Transamin for 3 days with management by 100% oxygen therapy. On the third hospital day, she was discharged with resolution of her symptoms and opacities as evidenced by chest radiography (Fig. 3). At the 1-year follow-up, she had not developed hypertension or signs of DCS.

Discussion

This diagnosed case based on the patient's history of recent SCUBA diving (<24 hours) exposed to rapid decompression; presence of dyspnea with corresponding radiologic finding; without any signs of infection or comorbidities.

The two most noteworthy and often life-threatening SCUBA-related injuries are DCS and AGE. These injuries are often referred to as decompression illness. Differentiating the two is often difficult, but DCS can occur hours after a dive and range in severity from uncomfortable to life-threatening. On the other hand, significant symptoms of AGE will be apparent within moments of surfacing from a dive. In our case, we believe the patient had DCS based on the onset and severity of her symptoms. DCS is the term applied to the syndrome associated with the liberation of gas originally held in solution into a free gas phase within the tissues of the body consequent to a reduction in a barometric pressure. This gas phase can most easily be detected in the form of venous bubbles³.

DCS is divided into two groups, type I and type II. In type I, gas microemboli are located in periarticular soft tissue, causing pain (most often in or near a joint) or cutaneous manifestations. In type II, gas microemboli are passed into the circulation, causing cardiorespiratory insufficiency or neurologic manifestations⁵. In the case of an extremely high load of gas microemboli in the pulmonary arteries (so-called "chokes"), substernal chest pain (usually described as burning), shortness of breath, dyspnea, and

cough are characteristic symptoms⁶. Acute pulmonary edema in decompression sickness is rare, but can occur *in situ* when an increase in pulmonary vascular distension generates negative airway pressures. Divers with hypertension are likely to have pulmonary edema, and non-hypertensive divers who experience DCS are predisposed to developing hypertension in the years that follow. In addition, immersion, cold, vigorous exercise, hyperventilation, and poorly functioning breathing regulators are known to be possible risk factors⁷. Pulmonary edema usually resolves rapidly, but may be the cause of some deaths attributed to drowning. In most instances, marked clearing of the lungs occurs within 3 to 5 days, with complete resolution of pulmonary edema within 7 to 10 days.

In our case, uncommon manifestation of type II DCS was suggested showing noncardiogenic pulmonary edema improved in 3 days without complication. Despite the frequent occurrence of limb/joint pain as a manifestation of DCS (the so-called "bends"), our patient had no symptoms characterized by deep, boring pain in a large joint. The patient did not complain of symptoms associated with the other known syndromes of DCS, including skin bends and spinal cord DCS⁸.

Studies about DCS in Korea are still insufficient considering current rapid increase of diver population^{9,10}. Radiologic findings of decompression sickness associated with SCUBA in Korea have been reported by Huh⁹ and spinal, cardiovascular and brain images of DCS have been presented. Park et al.¹⁰ have reported about proper management of DCS with 62 cases of Korean divers.

Definitive treatment for DCS of any type is recompression in a hyperbaric facility, which mechanically shrinks bubbles and increases the gradient to drive gas back into solution. Type I DCS often resolves by itself, but most physicians recommend observation for at least 24 hours to ensure symptoms are not aggravated¹¹.

References

1. McMullin AM. Scuba diving: what you and your patients need to know. *Cleve Clin J Med* 2006;73:711-2.
2. Salahuddin M, James LA, Bass ES. SCUBA medicine: a first-responder's guide to diving injuries. *Curr Sports Med Rep* 2011;10:134-9.
3. Klingmann C, Gonnermann A, Dreyhaupt J, Vent J, Praetorius

- M, Plinkert PK. Decompression illness reported in a survey of 429 recreational divers. *Aviat Space Environ Med* 2008; 79:123-8.
4. Fitz-Clarke JR. Risk of decompression sickness in extreme human breath-hold diving. *Undersea Hyperb Med* 2009;36:83-91.
5. Rozali A, Khairuddin H, Sherina MS, Zin BM, Sulaiman A. Decompression illness secondary to occupational diving: recommended management based current legislation and practice in Malaysia. *Med J Malaysia* 2008;63:166-9.
6. Sammut MA, Cassar A, Felice H. Coronary artery air embolism causing pulmonary edema secondary to acute coronary syndrome in a diver. *J Invasive Cardiol* 2008;20:E331-3.
7. Slade JB Jr, Hattori T, Ray CS, Bove AA, Cianci P. Pulmonary edema associated with scuba diving: case reports and review. *Chest* 2001;120:1686-94.
8. Gao GK, Wu D, Yang Y, et al. Cerebral magnetic resonance imaging of compressed air divers in diving accidents. *Undersea Hyperb Med* 2009;36:33-41.
9. Huh JT. Study of radiological findings and management of decompression sickness. *J Korean Soc Emerg Med* 1999;10: 667-79.
10. Park IC, Park SG, Han J, Choi BS, Kim HD. Hyperbaric oxygen therapy in decompression sickness. *J Korean Soc Emerg Med* 1999;10:97-107.