

Leiomyosarcoma of the Ovarian Vein: a Case Report with Radiological Findings

Hyeon Je Cho, MD¹
Ho Kyun Kim, MD¹
Jung Ho Suh, MD¹
Ghi Jai Lee, MD¹
Jae-Chan Shim, MD¹
Young Hwa Kim, MD¹
Hyuck-Sang Lee, MD²
Yun Kyung Kang, MD³

Index terms:

Leiomyosarcoma
Retroperitoneal space, neoplasms
Veins, ovarian
Veins, CT
Veins, US

DOI:10.3348/kjr.2008.9.s.s14

Korean J Radiol 2008;9:S14-17

Received April 23, 2007; accepted
after revision June 18, 2007.

¹Department of Diagnostic Radiology, Inje University College of Medicine, Seoul Paik Hospital, Seoul 100-032, Korea;

²Department of General Surgery, Inje University College of Medicine, Seoul Paik Hospital, Seoul 100-032, Korea;

³Department of Pathology, Inje University College of Medicine, Seoul Paik Hospital, Seoul 100-032, Korea

Address reprint requests to:

Hyeon Je Cho, MD, Department of
Diagnostic Radiology, Inje University
College of Medicine, Seoul Paik Hospital,
85, 2-Ga, Jeo-dong, Jung-gu, Seoul 100-
032, Korea.
Tel. (822) 2270-0138
Fax. (822) 2266-6799
e-mail: mediterian@hanmail.net

Leiomyosarcomas of the ovarian vein are very rare. Four cases have been reported in the English language clinical literature. We present a case of leiomyosarcomas where the use of multi-detector CT had a substantial role in the establishment of the preoperative diagnosis. The radiological images as well as intraoperative features are illustrated. We also discuss the radiological findings of the ovarian vein leiomyosarcoma in comparison with those of other venous or retroperitoneal leiomyosarcomas. We expect that the use of multi-detector CT will be the choice for the diagnostic work-up of vascular leiomyosarcomas.

Leiomyosarcoma is a malignant tumor arising from the smooth muscle cells. Although it may involve any organ in the body, involvement of the vessel wall is rare. Vascular leiomyosarcomas represent less than 2% of all leiomyosarcomas (1). The inferior vena cava is the most commonly affected vessel, accounting for 60% of all cases involving the vessel wall (2). The large central veins and the long saphenous veins are the next most commonly affected areas (1, 2).

A few sporadic cases of leiomyosarcoma of the ovarian vein have been described in previous reports (2–5). Among the previously reported cases, three cases showed abnormal excretory urographic findings (2, 4, 5), and two cases were confirmed by computerized tomography (CT) (4, 5). However, conventional CT was used only to confirm the presence of the retroperitoneal mass below the kidney. There was no mention that CT was able to preoperatively identify that the origin of the tumor was vascular (4, 5). In the present case, multi-detector CT and ultrasonography identified the retroperitoneal mass with intravascular growth patterns along the anatomical site of the right ovarian vein, and confirmed the diagnosis preoperatively. However, the use of ultrasonography had some limitations. We also discuss the imaging findings of ovarian vein leiomyosarcomas in comparison with other venous or retroperitoneal leiomyosarcomas.

CASE REPORT

A 39-year-old woman visited the hospital and presented with a hard, firm and palpable mass in the right upper abdomen. The medical and family histories were not remarkable. Serum levels of the tumor markers, including CA 19-9, carcinoembryonic antigens and CA 125, as well as laboratory findings, were all normal.

Excretory urography revealed lateral displacement of the lower pole of the right kidney and ureteropelvic junctional obstruction caused by the space-occupying lesion. An abdominal ultrasonogram (Acuson Sequoia 512; Siemens Medical System, Erlangen, Germany) showed the presence of a solid medium-echoic retroperitoneal

Leiomyosarcoma Originating from Ovarian Vein

mass with partial invasion of the inferior vena cava (Figs. 1A–C). An examination with 16-channel multi-detector CT (Mx8000 IDT; Philips Medical System, Eindhoven, the Netherlands) revealed the presence of a lobulated and well-defined right retroperitoneal mass measuring $5.1 \times 5.5 \times 6.9$ cm with extensive cystic degenerations and highly enhanced solid portions on contrast-enhanced scans (Fig. 1D). Coronal images definitely confirmed the vertically elongated arm-like structures contiguous with the mass, extending upwards to the right renal vein with partial protrusion into the inferior vena cava (Fig. 1E). In the downward direction, the mass was connected to the

normal right ovarian vein in the pelvis (Fig. 1F). The mass seemed to be separated from the adjacent right kidney and small bowels. Both renal and iliac angiograms showed the tumor vessels originating from the inferior segmental branch of the right renal artery.

During surgery, the mass was found to be located in the retroperitoneal space inferomedial side of the right kidney. The upper portion of the right ovarian vein was distended with tumor thrombi (Fig. 1G). There was no invasion of the adjacent organs and no enlarged lymph nodes.

Crosscut sections of the tumor showed mainly solid, and partly hemorrhagic and necrotic appearances with a

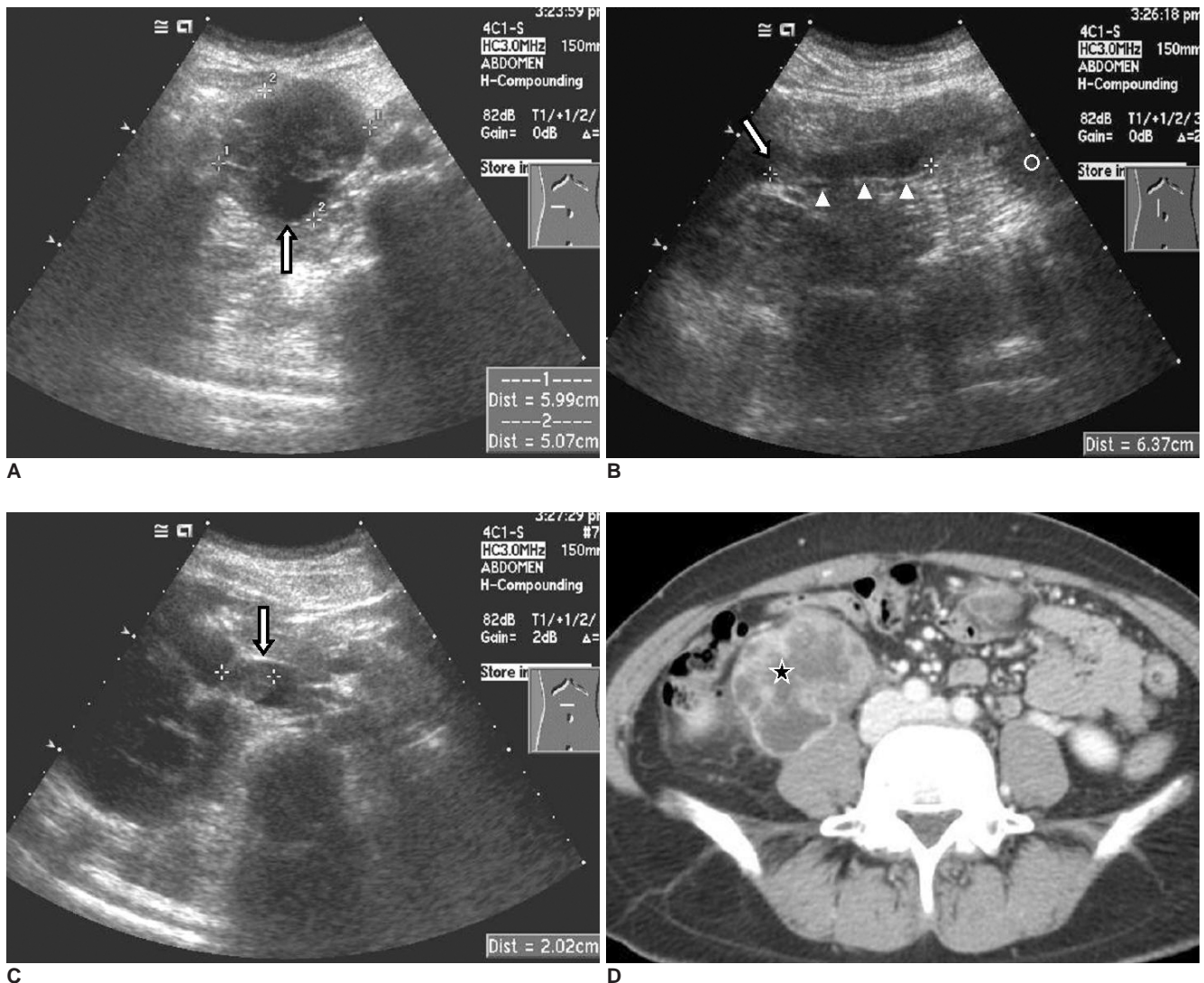


Fig. 1. Radiological and intraoperative findings of ovarian vein leiomyosarcoma in 39-year-old woman.

A. Transverse sonography reveals well-defined, spherical, medium-echoic and solid mass with eccentric cystic portion (arrow) at right paravertebral region.

B, C. Longitudinal and transverse sonography shows vascular structure, filled with solid components (arrowheads) and connected to main mass (circle), of which superior end shows round protrusion (arrows) in lumen of junctional area of inferior vena cava and right renal vein.

D. Just below level of aortic bifurcation, axial contrast-enhanced CT scan shows lobulated and well-defined lobulated retroperitoneal mass with highly enhanced solid components and extensive cystic degenerations (asterisk) at right paravertebral region.

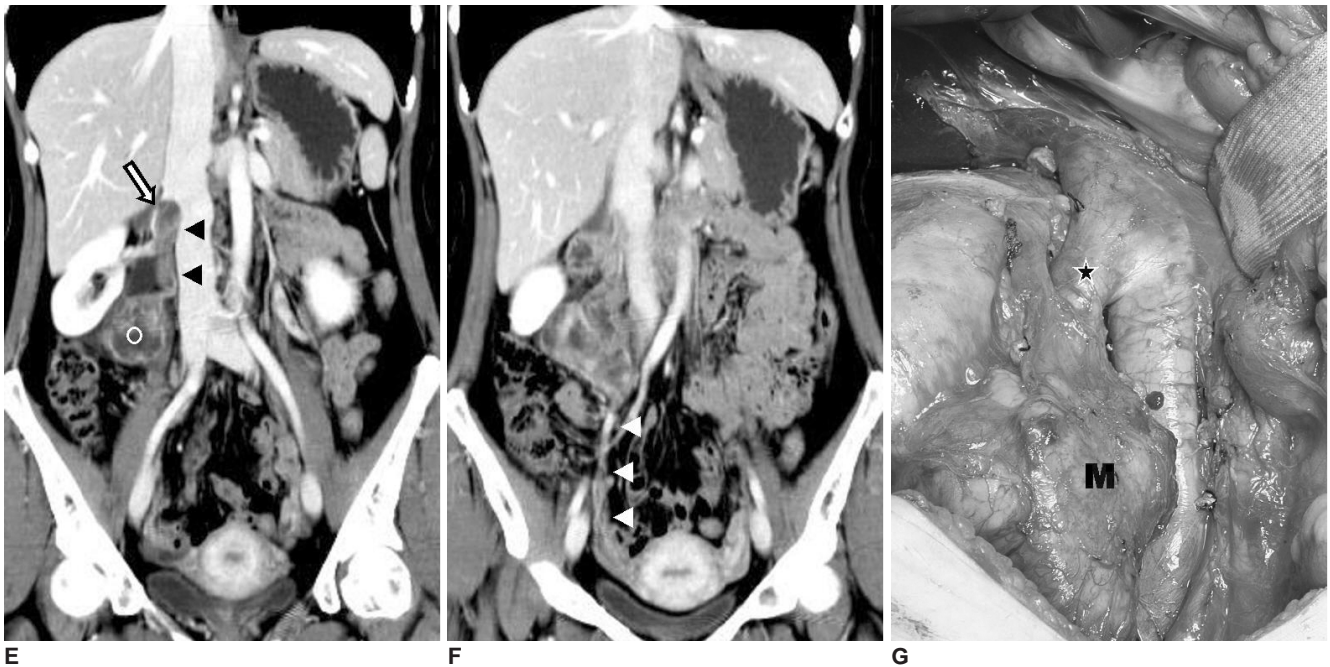


Fig. 1. Radiological and intraoperative findings of ovarian vein leiomyosarcoma in 39-year-old woman.

E, F. Coronal contrast-enhanced CT scans show vertical pedicular solid structures (black arrowheads), connected to upper portion of mass (circle), which protrudes in lumen of junctional area of right renal vein and inferior vena cava (arrow). Inferior portion of mass connects with normal ovarian vein in pelvis (white arrowheads).

G. During surgery, mass (M) is contiguous with right ovarian vein. Note distended right ovarian vein with tumor thrombi (asterisk). En bloc resection of mass together with right kidney, right ureter and retroperitoneal tissue, was performed.

yellow-tinged gray color. Microscopically, the tumor showed a typical pattern of intersecting fascicles of spindle cells with hyperchromatic nuclei and eosinophilic cytoplasm, representing the smooth muscle cells in the media. The tumor cells frequently showed highly pleomorphic nuclei, indicative of dedifferentiation. Immunohistochemically, the tumor cells were strongly positive for both smooth muscle actin and desmin.

The cells showed positive expression of CD34. Expression of CD117 (KIT), usually expressed in gastrointestinal stromal tumors and normally negative in leiomyosarcoma, was negative.

Adjuvant radiotherapy was performed over a six-week period. Follow-up abdominopelvic CTs after two and three months showed the presence of a 1.0 cm low attenuation nodule in the liver, that had newly developed and enlarged in size over the short-term intervals. We assumed the presence of a liver metastasis, but the patient was lost to further planned follow-up.

DISCUSSION

Leiomyosarcomas of the vein arise from the smooth muscle cells of the tunica media of the vessel wall. They grow slowly and bilaterally along the wall of the vessel.

Retroperitoneal leiomyosarcomas exhibit themselves as completely extravascular (62%), completely intravascular (5%) or with both extra- and intraluminal growth patterns (33%) (6). As the leiomyosarcomas of the inferior vena cava grow, they eventually invade adjacent tissues and metastasize distantly; however, they tend to expand along the tissue planes of least resistance. There are no reported cases of tissue invasion of the adrenals, kidneys or bowels for leiomyosarcomas of the inferior vena cava (7). Like other retroperitoneal tumors, these tumors seldom present with symptoms until they progress into a huge mass. When the tumors are discovered at this later stage, there is a poor outlook for long-term survival.

As the cases are rare, previously reported radiological findings of an ovarian vein leiomyosarcoma are few in number. The lesions have been merely described as a heterogeneous retroperitoneal mass with ipsilateral hydronephrosis by conventional CT and excretory urography (2, 4, 5).

The findings of excretory urography, representing the effect of mass, are not specific for the diagnosis of the leiomyosarcomas of vascular origin.

The general findings of gray-scale ultrasonography of an inferior vena cava leiomyosarcoma are solid but often show cystic necrosis with irregular walls (6, 8). In our case,

the sonographic findings were compatible with those of the CT scans, i.e., the pedicular structure was a tumor-invading ovarian vein. However, sonography had some limitations in that it failed to demonstrate the whole features of the tumor and the relationship between the tumor and the normal ovarian vein in the pelvis. These limitations may be due to the overlying bowel, the extent of the mass, or limitations in the depth resolution of the ultrasound modality (6).

The use of CT is superior to the use of sonography to reveal the highly enhancing and necrotic characteristics of the tumor, which is specific for the diagnosis of leiomyosarcoma (7). When CT shows a solid or necrotic extraluminal retroperitoneal mass not originating from a retroperitoneal organ, and possessing a contiguous intravascular enhancing appearance, it is accepted as a pathognomonic finding of vascular leiomyosarcoma (6). Low-attenuation areas representing necrosis, or rarely, a cystic mass due to diffuse necrosis, may be seen (7, 9). In our case, the eccentric cystic area is visible on sonography and CT; however, the extensive central necrosis is only visible on CT.

With great advances in digital imaging and high spatial resolution of multi-detector CT over the last few decades, scrolling through multi-stacked images and conducting multiplanar reconstruction is possible. These methods are useful in demonstrating the relationship between a mass and vessels, as well as detecting the tumor or venous thrombi. Thus, it was not difficult to presume that the mass originated in the right ovarian vein based on anatomical conceptions, as the tumor possessed vertically elongated bi-armed structures, the typical site of the right ovarian vein.

The angiographic findings of vascular leiomyosarcomas are generally accepted as nonspecific for the diagnosis. Angiography may have a role for demonstrating the primary vessels supplying the tumors and determining the degree of vascularity (6, 9).

Metastases will occur eventually in most survival cases of other venous or retroperitoneal leiomyosarcomas (1, 2, 6). Hematological metastasis occurs more commonly than lymphatic metastasis. The frequent sites for metastases are the liver, lung, brain, and peritoneum (1, 2, 6, 8). Local recurrence occurs occasionally in 40% to 77% of cases,

even though a complete excision was made (6). Our case also showed the CT findings of a liver metastasis, although a confirmation was not obtained.

In conclusion, the general imaging findings of our case were coincidental with those of other venous or retroperitoneal leiomyosarcomas. Sonography seemed to be helpful for the diagnosis of ovarian vein leiomyosarcoma, but the use of multi-detector CT was the tool of choice to confirm the diagnosis. Scrolling through multi-stacked images and multiplanar reconstruction of the CT images have great benefits for the preoperative predictions of the location, extent, and growth patterns of the tumor, as well as the relationship of the tumor and vessels. We expect that the primary diagnostic tool for vascular leiomyosarcomas will be the use of multi-detector CT and it may expel the other unnecessary, cost consuming or invasive diagnostic procedures.

References

1. Kevorkian J, Cento CP. Leiomyosarcoma of large arteries and veins. *Surgery* 1973;73:390-400
2. Dzsinih C, Gloviczki P, van Heerden JA, Nagorney DM, Pairolero PC, Johnson CM, et al. Primary venous leiomyosarcoma: a rare but lethal disease. *J Vasc Surg* 1992;15:595-603
3. Honore LH, Robins RE, Taylor RH. Leiomyosarcoma of the right ovarian vein a case report. *Angiology* 1977;28:285-288
4. Kawai K, Horiguchi H, Sekido N, Akaza H, Koiso K. Leiomyosarcoma of the ovarian vein: an unusual cause of severe abdominal and flank pain. *Int J Urol* 1996;3:234-236
5. Iannelli A, Karimjee BS, Fabiani P, Liolos J, Avallone S, Gugenheim J. Leiomyosarcoma of the ovarian vein: report of a case. *Int Surg* 2003;88:6-8
6. Hartman DS, Hayes WS, Choyke PL, Tibbetts GP. Leiomyosarcoma of the retroperitoneum and inferior vena cava: radiologic-pathologic correlation. *Radiographics* 1992;12:1203-1220
7. Young R, Friedman AC, Hartman DS. Computed tomography of leiomyosarcoma of the inferior vena cava. *Radiology* 1982;145:99-103
8. Singh-Panghaal S, Karcnik TJ, Wachsberg RH, Baker SR. Inferior vena caval leiomyosarcoma: diagnosis and biopsy with color Doppler sonography. *J Clin Ultrasound* 1997;25:275-278
9. Blum U, Wildanger G, Windfuhr M, Laubenberger J, Freudenberg N, Munzar T. Preoperative CT and MR imaging of inferior vena cava Leiomyosarcoma. *Eur J Radiol* 1995;20:23-27