

# Occult Interpositional Rotator Cuff - an Extremely Rare Case of Traumatic Rotator Cuff Tear

Cheng-Li Lin, MD<sup>1,2</sup>, Wei-Ren Su, MD<sup>1</sup>, I-Ming Jou, MD<sup>1</sup>, Wei-Hsing Chih, MD<sup>3</sup>

<sup>1</sup>Department of Orthopaedics, National Cheng Kung University Hospital, Tainan, Taiwan; <sup>2</sup>Department of Orthopaedics, Show-Chwan Memorial Hospital, Changhua, Taiwan; <sup>3</sup>Department of Orthopaedics, Chia-Yi Christian Hospital, Chiayi, Taiwan

Traumatic interposition of a rotator cuff tendon in the glenohumeral joint without recognizable glenohumeral dislocation is an unusual complication after shoulder trauma. Here we report the clinical and imaging presentations of a 17-year-old man with trapped rotator cuff tendons in the glenohumeral joint after a bicycle accident. The possible trauma mechanism is also discussed.

**Index terms:** Traumatic rotator cuff tear; Joint interposition; Posttraumatic subluxation; Shoulder dislocation

## INTRODUCTION

Traumatic rotator cuff tendon tears in young patients are unusual and they are commonly associated with high-energy trauma. The entrapment of a rotator cuff tendon in the glenohumeral (GH) joint is even rarer and this malady is prone to be missed. We experienced a case of a pseudo-paralyzed shoulder after trauma. The cause turned out to be interposition of the rotator cuff tendons in the GH joint. We present the imaging of this rare condition with the operative correlation. We also speculate on the possible trauma mechanism from the evidence of the concomitant injuries and the image findings.

## CASE REPORT

A 17-year-old male cyclist had accidentally fallen directly onto his face and right side in a farmland area. He presented to our emergency department with extensive swelling and ecchymosis of the face, right shoulder and elbow. The shoulder and elbow were too painful to move. The shoulder had diffuse swelling and tenderness, and any attempt at passive motion was resisted. The neurological examination, including the sensory status of the deltoid area, was difficult to assess due to the patient's enormous pain. An X-ray of the right shoulder revealed a widened joint space and an upward-migrated humeral head (Fig. 1A). Right olecranon and facial bone fractures were also found. According to the local physical findings and X-ray of the right shoulder, traumatic rotator cuff tendon tear was highly suspected by the consulting orthopedic surgeon. The magnetic resonance images (MRI) confirmed this suspicion. It revealed an interposition of the ruptured rotator cuff tendons, including the supraspinatus tendon and the infraspinatus tendon (Fig. 1B, C). Nevertheless, the patient has no subjective sense of shoulder dislocation during the trauma.

An inverted U-shaped skin incision was made during the operation, which allowed both an anterolateral and a

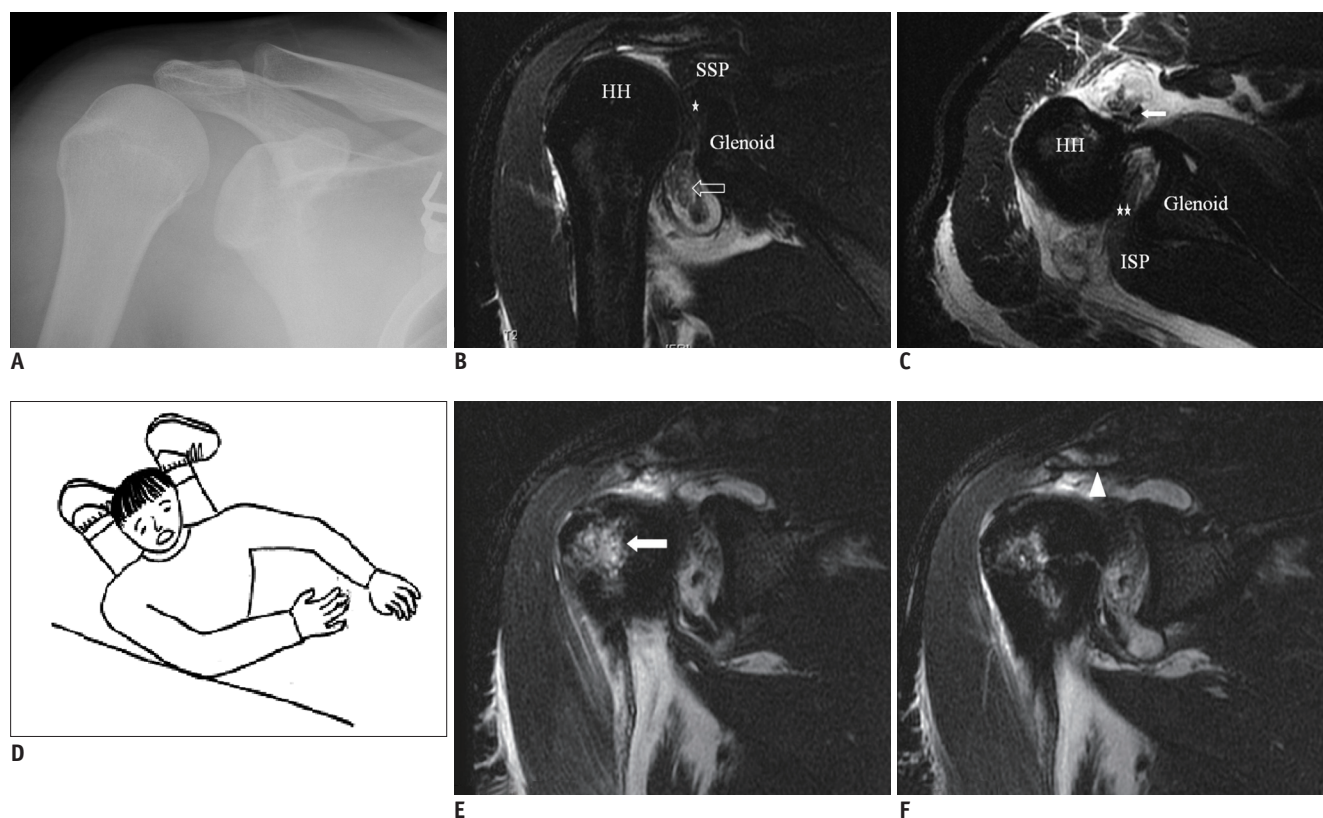
Received March 7, 2011; accepted after revision June 29, 2011.

**Corresponding author:** Wei-Hsing Chih, MD, Department of Orthopaedics, Chia-Yi Christian Hospital, No.539, Jhongsiao Rd. Chia-Yi City, Taiwan 60002.

• Tel: (8865) 276-5041 • Fax: (8866) 276-6189

• E-mail: 01666@cych.org.tw

This is an Open Access article distributed under the terms of the Creative Commons Attribution Non-Commercial License (<http://creativecommons.org/licenses/by-nc/3.0>) which permits unrestricted non-commercial use, distribution, and reproduction in any medium, provided the original work is properly cited.



**Fig. 1. Rotator cuff tendon interposition.**

**A.** Right shoulder X-ray reveals widened joint space and narrow subacromial space. **B, C.** MRI of right shoulder. Coronal, T2-weighted, fat-saturated sequence (TR 2000, TE 100) (**B**) shows supraspinatus defect and it is interposing in glenohumeral joint (asterisk). Parts of torn infraspinatus tendon (open arrow) were interposed into axillary pouch. Axial, T2-weighted, fat-saturated sequence (TR 2000, TE 100) (**C**) shows infraspinatus defect and soft tissues obliterating glenohumeral joint (double asterisk) and dislocated biceps long head tendon (solid arrow). **D.** Drawing demonstrating trauma mechanism. **E, F.** MRI of right shoulder. Coronal, T2-weighted, fat-saturated sequence (TR 2000, TE 100) shows bone edema over anterior part of humeral head (arrow in **E**) and acromion (arrowhead in **F**) after shoulder contusion during injury. HH = humeral head, ISP = infraspinatus tendon, SSP = supraspinatus tendon

posterolateral approach to the GH joint simultaneously. The operative findings included complete tears of the supraspinatus and infraspinatus tendons and these tendons were interposed in the GH joint. Besides, parts of the torn infraspinatus tendon were interposed into the axillary pouch. Avulsion of the transverse ligament of the bicipital groove leading to dislocation of the biceps long head tendon was also noted. However, the biceps long head tendon remained intact. It took effort to relocate the interposed tendons due to their tight incarceration. We then repaired the supraspinatus tendon and infraspinatus tendon. The dislocated biceps tendon was also reduced.

The rehabilitation program included arm sling immobilization for four weeks, followed by assisted passive range of motion (ROM) exercise for four weeks and then active ROM exercise. The patient regained a normal shoulder function, muscle strength and active ROM at eight months postoperatively.

## DISCUSSION

Traumatic shoulder dislocation is a common injury, but irreducible dislocation is a rare complication. The cause can be of bony or soft tissue origin (1-8), and an interposed biceps tendon is thought to be the most common soft tissue block in the GH joint (4). Regarding traumatic rotator cuff interposition, the English medical literature contains only rare cases of this (1-4, 7, 8). Ten patients have been presented and most of them (8 of 10 had sequela of shoulder dislocation, which resulted in persistent subluxation after a closed reduction maneuver (Table 1). Only two other cases of rotator cuff interposition without recognizable GH dislocation have been reported.

To the best of our knowledge, the traumatic mechanism causing the interposition has not been previously described in patients without recognizable GH dislocation. Because of the coexisting fractures and image findings, we inferred

**Table 1. Summary of Rotator Cuff Interposition from Various Authors' Series**

	Age/Gender	Dislocation	Early Detection	Interposed Tendon
Tietjen, 1982 (8)	19	No	10 days	SSP ISP TM
Bridle & Ferris, 1990 (7)	55/Male	Anterior	Yes	SSC
Walch et al., 2001 (4)	49/Male	Anterior	Yes	SSP SSC
	58/Male	Anterior	8 months	SSC Bi
	46/Male	Posterior	4 months	SSP ISP SSC Bi
	29/Female	Posterior	18 months	SSP ISP
	13/Male	Posterior	6 months	SSP ISP SSC
Shyam Kumar et al., 2005 (3)	30/Male	Anterior	Yes	SSC
Rickert & Loew, 2006 (2)	20/Male	No	2 weeks	SSP ISP
Connolly et al., 2008 (1)	87/Male	Anterior	17 days	SSC Bi

**Note.**— AN = axillary nerve, Bi = long head of biceps, ISP = infraspinatus, SN = suprascapular nerve, SSC = subscapularis, SSP = supraspinatus, TM = teres minor

the possible mechanism in this presented case. We can speculate the injury was initiated by violent adduction and internal rotation of the humerus while falling onto the ground with a flexed elbow (Fig. 1D). It resulted in tear of the external rotator tendon, infraspinatus tendon and dislocation of the biceps long head. The following axial loading on the olecranon led to "superior subluxation" of the humeral head, which is evidenced by the MRI of the "kissing lesion" and bony contusions over the anterior humeral head and acromion (Fig. 1E, F). The supraspinatus tendon was avulsed during the forceful superior migration of the humeral head in the sustained adduction position. At the same time, the avulsed rotator cuff tendons were interposed into the GH joint by the bowstring tension. Due to the blockage by the rotator cuff tendons, the humeral head could not be completely spontaneously repositioned by ligamentotaxis.

The early detection of rotator cuff interposition is not easy since the radiological findings are subtle. Thus, the rate of delayed diagnosis was reported to be up to 70% (7 of 10) (Table 1). Widening of the GH joint on the plain radiograph would be the significant clue on the imaging study, though it might be erroneously explained by distension of the shoulder joint due to hemarthrosis. CT with soft tissue windows or MRI would aid in making the proper diagnosis.

In a review of the literature, we also noted that the supraspinatus and infraspinatus tend to tear and interpose concurrently, except for one patient in Walch's series (Table 1). This phenomenon might be explained by the "rotator cable" concept (9, 10). Since these two tendons are connected together by the cable-like structure on

the insertion site of the humerus, they would be avulsed together during trauma, and the tendons are large enough to block the spontaneous reduction of the humeral head.

In conclusion, traumatic interposition of rotator cuff tendons without recognizable glenohumeral dislocation is a rare but challenging injury to properly diagnose and treat. We should have a high degree of suspicion when the shoulder X-ray shows subtle findings of a widened joint space. CT with soft tissue windows or MRI should be performed to confirm the diagnosis. Better results can be expected with early recognition and then timely surgical treatment.

## REFERENCES

- Connolly S, Ritchie D, Sinopidis C, Brownson P, Aniq H. Irreducible anterior dislocation of the shoulder due to soft tissue interposition of subscapularis tendon. *Skeletal Radiol* 2008;37:63-65
- Rickert M, Loew M. Glenohumeral interposition of a torn rotator cuff in a young motorcyclist. *Arch Orthop Trauma Surg* 2006;126:184-187
- Shyam Kumar AJ, Charity R, Periera A, Deshmukh SC. Interposed subscapularis: a rare cause of irreducible shoulder dislocation. *E J Orthop Surg Traumatol* 2005;15:42-44
- Walch G, Boulahia A, Robinson AH, Calderone S. Posttraumatic subluxation of the glenohumeral joint caused by interposition of the rotator cuff. *J Shoulder Elbow Surg* 2001;10:85-91
- Mihata T, Doi M, Abe M. Irreducible acute anterior dislocation of the shoulder caused by interposed fragment of the anterior glenoid rim. *J Orthop Sci* 2000;5:404-406
- Davies MB, Rajasekhar C, Bhamra MS. Irreducible anterior shoulder dislocation: the greater tuberosity Hill-Sachs lesion. *Injury* 2000;31:470-471
- Bridle SH, Ferris BD. Irreducible acute anterior dislocation

- of the shoulder: interposed scapularis. *J Bone Joint Surg Br* 1990;72:1078-1079
8. Tietjen R. Occult glenohumeral interposition of a torn rotator cuff. A case report. *J Bone Joint Surg Am* 1982;64:458-459
  9. Lo IK, Burkhart SS. Current concepts in arthroscopic rotator cuff repair. *Am J Sports Med* 2003;31:308-324
  10. Burkhart SS, Esch JC, Jolson RS. The rotator crescent and rotator cable: an anatomic description of the shoulder's "suspension bridge". *Arthroscopy* 1993;9:611-616