

9

1

가

= Abstract =

A Case of Herpes Zoster in a 9-month-old Infant

Seung On Keun, M.D., Soo Young Lee, M.D., Sun Mi Kim, M.D.
Dae Chul Jeong, M.D., Seung Yun Chung, M.D. and Jin-Han Kang, M.D.

*Department of Pediatrics, College of Medicine,
The Catholic University of Korea, Seoul, Korea*

We experienced a case of herpes zoster in a 9-months aged infant as followings; The patient had no history of chickenpox or varicella vaccination. Also, her mother had no history of varicella infection and no contact history with varicella during pregnancy. The patient had only a history of exposure to chickenpox patient at 7th days after birth, but fortunately chickenpox was not developed. Sequentially, symptoms of cough with fever and tachypnea were developed on admission date(7 days had passed already after development of the initial skin lesion). On physical examination, multiple grouped painless erythematous papulovesicles with small crusts were observed on the right lower back, flank and abdomen along the T11 dermatome. Coarse breathing sound was auscultated, and increased linear infiltrations on both parahilar areas were seen on chest radiography. Liver enzymes were slightly elevated. Tzanck test was negative. The initial titers of anti-VZV IgM and IgG on admission were negative, but the following titers of anti-VZV IgM and IgG were positive. The patient received treatment of acyclovir for 7 days, and healed completely without sequelae. We report this case with brief review of related literatures.

Key Words : Varicella zoster virus, Herpes zoster, Infancy

VZV)가

(sensory ganglia)

VZV

(varicella-zoster virus,

1, 2).

(Fig. 1).

3, 4).

:

12.5 g/dL, 36.3%, 8,600/
 mm^3 (34%, 52%, 12%,
 1%), 470,000/ mm^3 .
 22 mm/hr, C-

3

1, 5, 6).

7

가

9

11

: ○○, 9 ,
 : 7

: 7

가,

,

: 41 3 , 3.2 kg

. 7

7

가 : 28

: 38°C, 35

/ , 122 / ,

가

11

가 가

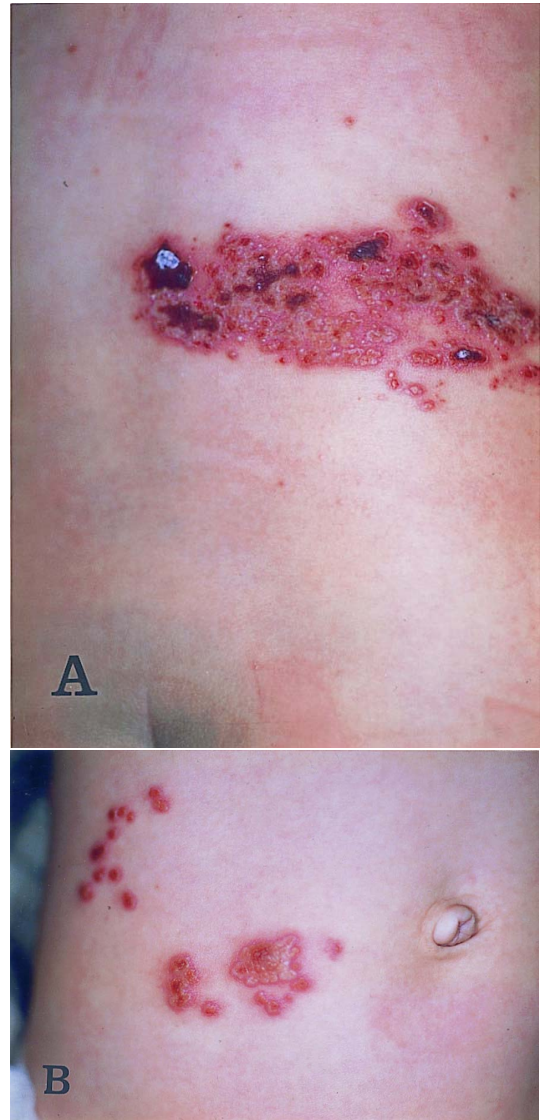

Fig. 1. Crops of papulovesicular eruptions and crusts scattered on right lower back, flank and lower abdominal area, corresponding to T11 dermatome. (A) On right lower back and flank area. (B) On right lower abdominal area.

102 mg/dL, BUN
11.8 mg/dL, Cr 0.4 mg/dL, Na 140 mEq/L, K 4.2
mEq/L, AST/ALT 49/34 U/L, 7.0 g/dL,
4.6 g/dL
CD3 59.27%, CD4 44.95%, CD8
14.98%, CD19 9.58%, CD56 8.23%
7 () Enzyme immunoassay

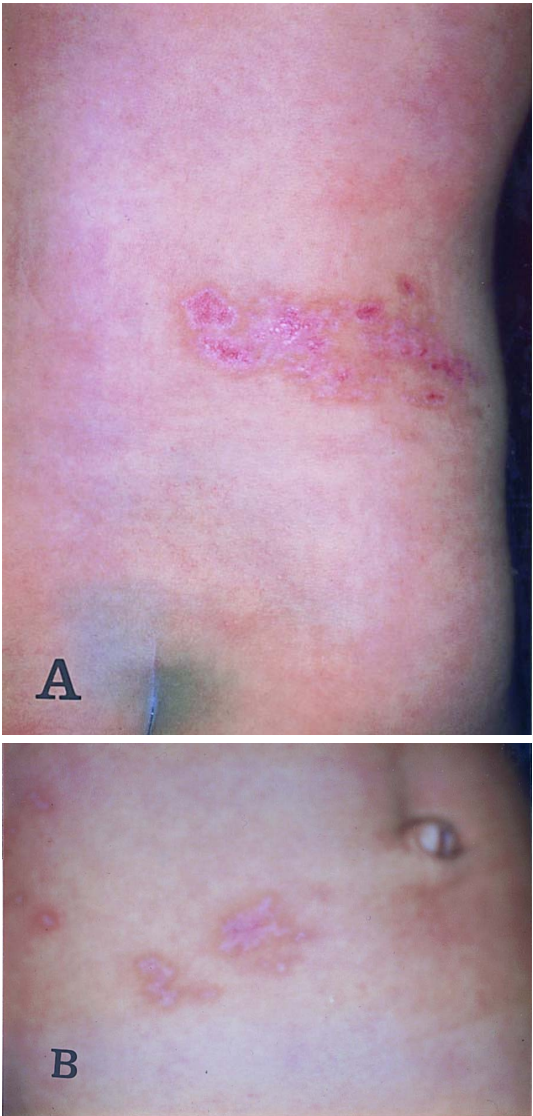


Fig. 2. The skin lesions were almost healed with some remained small pigmentation. (A) On right lower back and flank area. (B) On right lower abdominal area.

(EIA) anti-VZV IgM IgG 0.67
0.98 (; <0.8,
>1.0), 21 anti-VZV IgM
IgG 2.10 4.89
:
4 (10)
가가
Tzanck : 2 (8)
:
acyclovir acyclo-
vir 2
37.8°C 38°C
, 4
AST/ALT가 67/57 U/L 가
,
가가 acyclovir
3
6 (12)
,
가 가
anti-VZV IgM IgG
anti-VZV IgM IgG ,
(Fig. 2A, 2B).
VZV
가 VZV가 가
(reactivation)
가
10% 75
% 45
가 VZV

1, 2) . (natural killer cell), (cytokine mediator)가 , 2 VZV가 , 3, 4) , 가 9, 14) . 가 VZV , 가 7 (neuronal latency) 7 VZV 5, 7~9) . 가 가 zigzag . (cicatrix), , (congenital varicella syndrome), VZV - , 7 (zoster in infancy) 3가 가 7 10) . 가 5) 100 VZV 가 6 12 11 , 16~20 1) 가 VZV 6 20 - 6) 가 2% 가 가 5 가 2 17% , , (post-herpetic neuralgia) 10) . 가 (thoracic nerve) 11) . (dis-seminated cutaneous zoster) 4 VZV 11 20 14, 15) . 가 VZV 가 9~13) . , (virus specific antibodies) , ,

¹⁰⁾ . 11

7

acyclovir ¹⁰⁾ 가

AST/ALT 1~2

¹⁶⁾ 가

acyclovir

acyclovir

¹⁷⁾ acyclovir 가

72 20 mg/kg/ dose

800 mg

72 75% acyclovir 500 mg/m² 10 mg/kg

가, VZV가 8 7 ,

¹⁰⁾ 48

Wright Giemsa Tzanck

4 acyclovir

가 ⁵⁾ (sensitivity)가

3

7~10 ¹⁰⁾ (complement fixation test) ELISA 가 가

VZV

anti-VZV IgM ,

12 anti-VZV

IgG 가 VZV 가

⁹⁾ 7

anti-VZV IgM IgG 가 0.67 0.98 9 11

, 2 2.10 4.89 ,

가

acyclovir

가 B T CD4

44.95%, CD8 14.98% CD4/CD8 가 3

가 ,

가 가

1) , .

- 1 . 1996;34:476-9.
- 2) Winkelmann RK, Perry HO. Herpes zoster in children. *JAMA* 1959;171:876-80.
- 3) Baba K, Yabuuchi H, Takahashi M, Orga PL. Increased incidence of herpes zoster in normal children infected with varicella zoster virus during infancy : community-based fallow-up study. *J Pediatr* 1986;108:372-7.
- 4) David TJ, Williams ML. Herpes zoster in infancy. *Scand J infect Dis* 1979;11:185-6.
- 5) , , . 11
1 . 1999;37:948-50.
- 6) , , , , ,
1 .
1997;40:1169-72.
- 7) Brunell PA, Kotchmar GS. Zoster in infancy : failure to maintain virus latency following intrauterine infection. *J Pediatr* 1981;98:71-3.
- 8) Huang JL, Sun PC, Hung IJ. Herpes zoster in infancy after intrauterine exposure to varicella-zoster virus : report of two cases. *J Formos Med Assoc* 1994;93:75-7.
- 9) Paryani SG, Arvin AM. Intrauterine infection with varicella zoster virus after maternal varicella. *N Engl J Med* 1986;314:1542-6.
- 10) Martin GM, Lawrence RS. Varicella-zoster virus. In : Behrman RE, Kliegman RM, Jenson HB, editors. *Nelson Textbook of pediatrics*. 16th ed. Philadelphia : WB Saunders Co, 2000: 973-7.
- 11) Meyers JD. Congenital varicella in term infants : risk reconsidered. *J Infect Dis* 1974;129: 215-7.
- 12) Saibara T, Maeda T, Onishi S, Yamamoto Y. Depressed immune functions in the early phase of varicella-zoster virus reactivation. *J Med Virol* 1993;39:342-5.
- 13) Kihei T, Shoji K, Kiyomi Y, Tetsuro M. Varicella-zoster virus (VZV) reactivation is related to the low response of VZV-specific immunity after chickenpox in infancy. *J Infect Dis* 1994; 169:650-2.
- 14) Chiang CP, Chiu CH, Huang YC, Lin TY. Two cases of disseminated cutaneous herpes zoster in infants after intrauterine exposure to varicella-zoster virus. *J Pediatr Infect Dis* 1995; 14:395-7.
- 15) Straus SE, Ostrove JM, Inchausp'e G. Varicella-zoster virus infections : biology, natural history, treatment, and prevention. *Ann Intern Med* 1988;108:221-37.
- 16) Wurzel CL, Kahan J, Heitler M, Rubin LG. Prognosis of Herpes Zoster in children. *Am J Dis Child* 1986;140:477-8.
- 17) Rothe MJ, Feder HM, Grant-Kels JM. Oral acyclovir therapy for varicella and zoster infections in pediatric and pregnant patients : a brief review. *Pediatr Dermatol* 1991;8:236-42.