

## Neonatal Meningoencephalitis caused by Herpes Simplex Virus Type 2

Dae Eun Kim, M.D.<sup>\*</sup>, Ramee Pae, M.D.<sup>\*</sup>, E Young Bae, M.D.<sup>\*,†</sup>, Ji Yoon Han, M.D.<sup>\*</sup>,  
Seung Beom Han, M.D.<sup>\*,†</sup>, Dae Chul Jeong, M.D.<sup>\*</sup>, In Goo Lee, M.D.<sup>\*</sup>,  
and Jin Han Kang, M.D., Ph.D.<sup>\*,†</sup>

Department of Pediatrics<sup>\*</sup>, Vaccine Bio Research Institute<sup>†</sup>, College of Medicine,  
The Catholic University of Korea, Seoul, Korea

Despite its rare occurrence, early diagnosis and appropriate treatment for neonatal herpes simplex virus infection are mandatory due to its high morbidity and mortality. In Korea, there has been no epidemiologic data on neonatal herpes simplex virus infection, and even case reports are rare. We observed a 16-day-old neonate who presented with fever and seizures. We diagnosed her with meningoencephalitis caused by herpes simplex virus type 2 based on the polymerase chain reaction test, and treated her with intravenous acyclovir and anticonvulsants. The seroprevalence of herpes simplex virus type 2 sharply increases in women in their 30s, and the average age for childbirth has increased to older than 30 years of age in Korea; we therefore expect that the incidence of neonatal herpes simplex virus type 2 infection will rise in Korea, and more attention should be directed to neonatal herpes simplex virus type 2 infection. We report this newborn patient's case along with a literature review.

**Key Words :** Herpes Simplex Virus Type 2, Meningoencephalitis, Neonate, Republic of Korea

### Introduction

Neonatal herpes simplex virus (HSV) infection occurs at a rate of 8–60 neonates per 100,000 live births in the United States<sup>1)</sup>. In Korea, no epidemiologic data exists on neonatal HSV infection, including neonatal HSV type 2 infection, which comprises about 80% of cases<sup>2–4)</sup>. In addition, case reports on neonatal HSV infection are rare in Korea. As neonatal HSV infection has no specific charac-

teristics that distinguish it from severe bacterial infection<sup>4)</sup>, each case report provides valuable information on the disease and helps improve proper diagnosis and treatment. We report a case of a 16-day-old neonate who presented with fever and seizure. This neonate was diagnosed with HSV type 2 meningoencephalitis through polymerase chain reaction (PCR) in the cerebrospinal fluid (CSF) and was treated with intravenous acyclovir.

### Case Report

A 16-day-old neonate presented with fever and clonic movements of her left arm and leg. She had been febrile since the previous day, but she was neither irritable nor lethargic. The clonic move-

Received : 16 January, 2014, Revised : 7 April, 2014

Accepted : 8 April, 2014

Correspondence : Jin Han Kang, M.D., Ph.D.

Department of Pediatrics, College of Medicine, The Catholic University of Korea, Seoul, Korea

Tel : +82-2-2258-6183, Fax : +82-2-537-4544

E-mail : kjhan@catholic.ac.kr

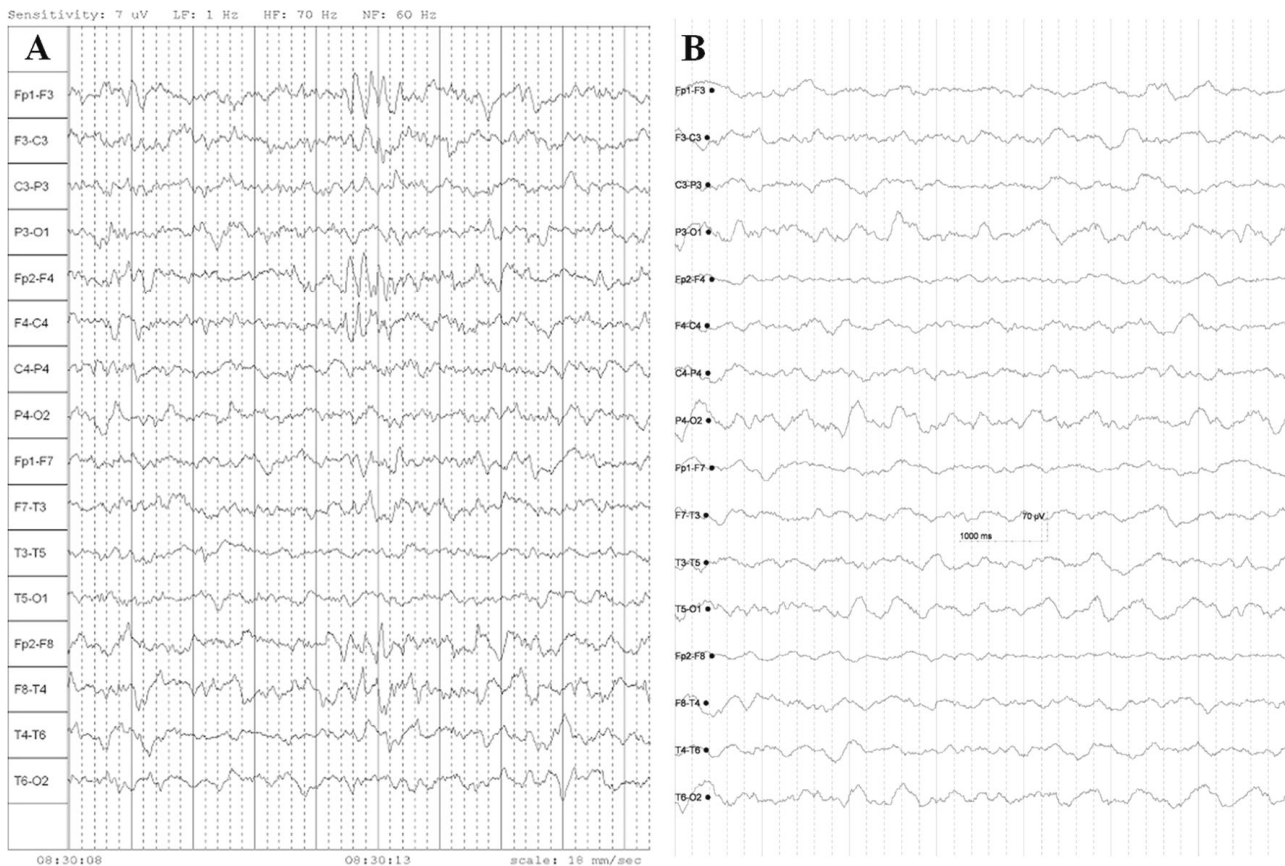
ments lasted for several seconds and had occurred repeatedly since the morning. This baby was delivered vaginally at 40 weeks and one day of gestation age with a body weight of 3.94 kg, and there were no perinatal problems. Her elder sister had not been sick during the perinatal period. There was no history of maternal illness during pregnancy, and the mother had not experienced genital herpes. On admission, the patient's body temperature was 37.6 °C, heart rate was 150 beats/ minute, and her respiratory rate was 25 breaths/ minute. There were no abnormal findings on the head and neck, chest and abdominal examinations. Laboratory tests revealed that the white blood cell (WBC) count was 12,740/ $\mu$ L (neutrophils 41.8%, lymphocytes 43.7%, monocytes 12.1%), hemoglobin was 16.3 g/dL, the platelet count was 398,000/ $\mu$ L, and the C-reactive protein was <0.02 mg/dL. Blood chemistry and electrolyte levels were unremarkable except for an elevation of total bilirubin to 7.6 mg/dL. A lumbar puncture (LP) was performed and revealed pleocytosis, increased protein levels, and decreased glucose level in the CSF (Table 1). We diagnosed her with

meningoencephalitis based on her presenting symptoms and LP results, and initiated treatment with empirical antibiotics of ampicillin/sulbactam and cefotaxime. On hospital day 2, electroencephalography (EEG) was performed and showed intermittent high-amplitude sharp waves on a normal background rhythm of 1–3 Hz in both frontal areas (Fig. 1A). Anticonvulsant therapy was begun with intravenous levetiracetam (20 mg/kg twice a day). Brain magnetic resonance imaging (MRI) showed leptomeningeal enhancement without definite brain parenchymal lesions (Fig. 2A). On hospital day 3, it was reported that blood, urine and CSF bacterial cultures were all negative. CSF PCR for enterovirus and HSV type 1 were also negative. However, CSF PCR for HSV type 2 was positive. The patient was diagnosed with meningoencephalitis caused by HSV type 2, and intravenous acyclovir therapy (20 mg/kg thrice a day) was begun. On hospital day 4, the levetiracetam dose was increased (25 mg/kg twice a day), and intravenous phenobarbital (5 mg/kg twice a day) was added; after this, her seizures disappeared. The serologic study for HSV on hospital day 4 showed

**Table 1.** Results of Serial Cerebrospinal Fluid Examinations

	On admission	One week after acyclovir treatment	Three weeks after acyclovir treatment
White blood cell count (/ $\mu$ L)	52	140	9
Neutrophils (%)	1	2	Not determined
Lymphocytes (%)	87	80	Not determined
Macrophages (%)	11	18	Not determined
Red blood cell count (/ $\mu$ L)	0	0	20
Protein (mg/dL)	133.8	111.5	71.7
Glucose (mg/dL)	33	38	41
Serum glucose (mg/dL)	90	81	86
HSV type 1 PCR	Negative	Negative	Negative
HSV type 2 PCR	Positive	Negative	Negative
Enterovirus PCR	Negative	Not performed	Not performed
Bacterial culture	Negative	Negative	Negative

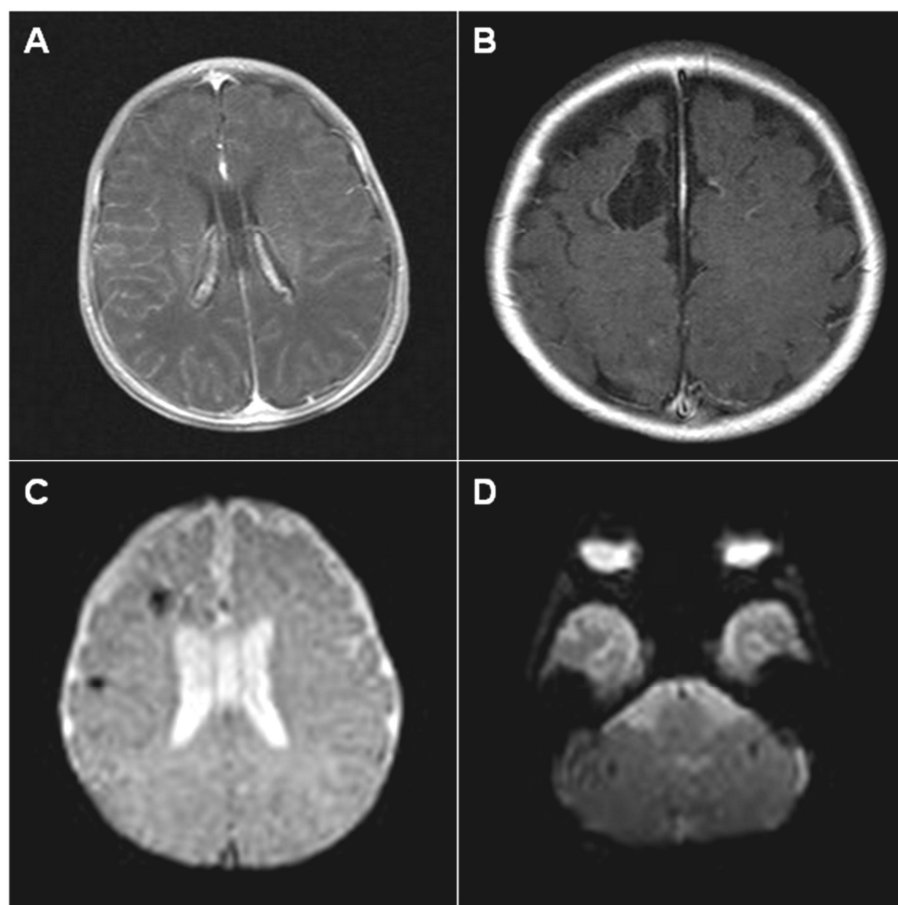
Abbreviations: HSV, herpes simplex virus; PCR, polymerase chain reaction.



**Fig. 1.** (A) The initial electroencephalography shows regular and symmetric background activity of 1-3 Hz, with intermittent sharp high-amplitude waves in both frontal areas. (B) An EEG repeated at three months after diagnosis of meningoencephalitis shows no abnormal findings.

positive anti-HSV IgG and negative anti-HSV IgM. A second LP, performed after seven days of intravenous acyclovir therapy, still revealed pleocytosis, increased protein levels and decreased glucose level, but HSV type 2 PCR was negative (Table 1). On hospital day 11, it was reported that her blood and CSF cultures which were performed before intravenous acyclovir therapy were negative for HSV. The patient completed a 21-day course of intravenous acyclovir therapy without any complications or drug adverse effects, and a third LP was performed on hospital day 24. The third LP showed improved results: decrease in CSF WBC count and protein level and slight increase in glucose level

(Table 1). Visual and auditory evoked potentials were normal. The patient was discharged from hospital on hospital day 27 while continuing oral anticonvulsant therapy (levetiracetam 25 mg/kg and phenobarbital 5 mg/kg twice a day). An EEG repeated at three months after diagnosis showed no abnormal findings (Fig. 1B), and anticonvulsant therapy was finished at 4 months after diagnosis of meningoencephalitis. Brain MRI was also repeated three months after diagnosis, which unfortunately showed focal encephalomalacia in both frontal lobes (Fig. 2B) and multifocal old hemorrhages in the cerebral and cerebellar parenchyma (Fig. 2C and 2D). At seven months of age, her body weight was



**Fig. 2.** (A) Initial brain magnetic resonance imaging on hospital day 2 shows only leptomenigeal enhancement on the axial T1-weighted image. Repeated brain magnetic resonance imaging three months after the diagnosis shows (B) cystic lesions in the cortex and subcortical white matter of both frontal lobes on the axial T1-weighted image and (C) old hemorrhages in the cerebral parenchyma and (D) the cerebellar parenchyma on the axial echo planar image.

9.2 kg (90–95<sup>th</sup> percentile) and her height was 68.2 cm (50–75<sup>th</sup> percentile). Bayley Scales of Infant and Toddler Development III performed at seven months of age revealed that composite scores of cognition, language, motor, social–emotional and adaptive behavior subtests were 100, 91, 79, 100 and 85, respectively. Only motor development was in a borderline range. Eight months have passed since the diagnosis of meningoencephalitis, and the patient has not experienced HSV reactivation.

## Discussion

Most cases of neonatal HSV infection, which is usually transmitted during delivery, are caused by HSV type 2<sup>1)</sup>. This is in contrast to HSV infection in children and adults, which is usually caused by HSV type 1<sup>1)</sup>. Kim et al.<sup>5)</sup> reported that the seroprevalence of HSV type 2 in pregnant Korean women living in Seoul metropolitan area between 2009 and 2010 was 17%. This seroprevalence was similar to

the seroprevalence in European pregnant women between 2004 and 2007<sup>6)</sup> and in American women between 1999 and 2004<sup>7)</sup>. Shin et al.<sup>8)</sup> reported that the seroprevalence of HSV type 2 in Korean women living in the southern area of Korea in 2004 increased from 8% for those in their 20s to 31% for those in their 30s. This indicates that Korean women are likely to experience their primary HSV type 2 infection in their 30s. The transmission rate of HSV from a mother to her newborn is low as 1% in the case of HSV reactivation during pregnancy<sup>1)</sup>. However, the rate increases to 25–50% if the mother is first infected with HSV during pregnancy<sup>1)</sup>. The average age of childbirth of Korean women has increased from 24.8 years in 1985 to 30.5 years in 2012<sup>9)</sup>. Accordingly, we can speculate that neonatal HSV type 2 infection will occur more frequently since the average age of childbirth overlaps with the age when women are most frequently first infected with HSV type 2. Therefore, more frequent attention should be directed to neonatal HSV type 2 infection, even though it has been rarely reported.

Symptoms and signs of neonatal HSV infection usually develop at 8–12 days of life as non-specific manifestations which are difficult to differentiate from severe bacterial infections<sup>3, 4, 10)</sup>. Herpetic skin lesions do not occur in 18–69% of the cases, only 30% of HSV-infected mothers present symptoms and signs suggesting HSV infection at delivery, and 80–89% of the mothers do not complain of genital herpes<sup>2, 4)</sup>. Therefore, supplemental laboratory tests are necessary for a definitive diagnosis of neonatal HSV infection. Our patient also did not show any skin lesions, and the mother had no previous history of genital herpes and did not show any skin and mucosal lesions consistent with HSV infection on

examination performed during the patient's hospitalization. Accordingly, we assumed that the patient was exposed to asymptotically excreted HSV during delivery. PCR is the most sensitive laboratory test, though antibody assays and virus culture may be used<sup>1)</sup>. Due to the probability of a false negative PCR result in the early phase of infection, repeated PCR may be necessary for patients who show a negative initial result but are likely to be infected with HSV<sup>1)</sup>.

Neonatal HSV infection is divided into three categories according to the extent of disease; disseminated infection, CNS infection and SEM (skin, eyes, mouth) infections comprise 9–25%, 30–75% and 19–45% of cases, respectively<sup>4, 11)</sup>. The highest mortality rate, 30%, is observed in disseminated infection; in addition, up to 70% of neonates who survive CNS infection will have sequelae<sup>1)</sup>. Considering the occasional development of repeated CNS symptoms after neonatal CNS infection<sup>1)</sup> and the occurrence of acute retinal necrosis several years after the initial CNS infection<sup>12)</sup>, long-term observation is mandatory for patients who experienced neonatal HSV infection. MRI is more valuable than computed tomography as a brain imaging modality<sup>13)</sup>. Repeated brain imaging may also be necessary, as the initial brain MRI within a week of HSV diagnosis may be unremarkable or may show only diffusion defects<sup>3, 13)</sup>. However, definite conventional T1 or T2 abnormalities may be observed in repeated imaging studies<sup>3, 13)</sup>, as observed in our patient. Although two-thirds of neonates with HSV encephalitis showed abnormal brain imaging findings in temporal lobes, less than one-third of the neonates showed brain lesions limited into temporal lobes and two-thirds of the neonates showed multifocal brain

lesions<sup>13)</sup>. Schleede et al.<sup>3)</sup> reported that brain lesions involving parietal or occipital lobes were more frequent than lesions involving temporal lobes in neonates with CNS HSV infection, and this finding was contrary to the cases of non-neonatal HSV infection.

Treatment of neonatal HSV infection is achieved by intravenous acyclovir. CNS and disseminated infections should be treated for more than 21 days, according to the patient's clinical and laboratory responses<sup>1)</sup>. SEM infections should be treated with intravenous acyclovir for 14 days because it can progress to CNS or disseminated infection<sup>1)</sup>. Some researchers reported that long-term oral acyclovir therapy lasting for six months to two years improved neurodevelopmental outcomes in neonates who experienced disseminated or CNS HSV infection<sup>14, 15)</sup>. In our patient, antiviral therapy was initiated within three days of symptoms and seizures responded well to anticonvulsant therapy. Therefore, oral acyclovir suppression therapy following intravenous therapy was not given.

Unfortunately, indications for performing HSV tests and empirical treatment for HSV infection have not been established yet. Some researchers insist on a universal laboratory test and empirical treatment targeting HSV infection for febrile neonates younger than 21 days<sup>4)</sup>. Others insist on a selective HSV test and empirical therapy for febrile neonates with pleocytosis on CSF examination<sup>16)</sup>. In Korea, where there is the potential for increasing incidence of neonatal HSV type 2 infection, a multicenter or nationwide epidemiologic survey on neonatal HSV infection should be performed to establish appropriate diagnostic and therapeutic strategies.

## 한 글 요 약

### Herpes simplex virus type 2에 의한 신생아 수막뇌염

가톨릭대학교 의과대학 소아과학교실\*,  
가톨릭대학교 의과대학 백신 바이오 연구소†

김대은\* · 배라미\* · 배이영\*,† · 한지윤\* · 한승범\*,†  
정대철\* · 이인규\* · 강진한\*,†

신생아 HSV 감염은 주로 HSV type 2에 의해 발생하는 것으로 알려져 있으나, 국내에서는 신생아 HSV 감염의 역학 자료뿐만 아니라, HSV type 2가 증명된 신생아 수막뇌염 증례 보고조차 없었다. 저자들은 열과 경련을 주소로 내원한 생후 16일 신생아에서 PCR 검사를 통해 HSV type 2에 의한 수막뇌염을 진단하고 acyclovir 및 항경련제 치료를 시행하였다. 환자는 뇌 MRI 검사에서 뇌연화증이 있어 성장과 발달에 대해 추적 관찰 중이다. 우리나라 여성에서 30대에 HSV type 2 초감염이 가장 빈번히 발생하고 최근 평균 초산 연령이 증가하여 30대로 진입함에 따라 향후 HSV type 2에 의한 신생아 감염이 증가될 것으로 예상되어, HSV type 2 감염은 열이 나는 신생아에서 반드시 고려해야 할 것이다.

## References

- 1) Corey L, Wald A. Maternal and neonatal herpes simplex virus infections. *N Engl J Med* 2009;361:1376-85.
- 2) Whitley RJ, Nahmias AJ, Visintine AM, Fleming CL, Alford CA. The natural history of herpes simplex virus infection of mother and newborn. *Pediatrics* 1980;66:489-94.
- 3) Schleede L, Bueter W, Baumgartner-Sigl S, Opladen T, Weigt-Usinger K, Stephan S, et al. Pediatric herpes simplex virus encephalitis: a retrospective multicenter experience. *J Child Neurol* 2013;28:321-31.
- 4) Long SS, Pool TE, Vozzak J, Daskalaki I, Gould JM. Herpes simplex virus infection in young infants during 2 decades of empiric acyclovir therapy. *Pediatr Infect Dis J* 2011;30:556-61.

- 5) Kim ID, Chang HS, Hwang KJ. Herpes simplex virus 2 infection rate and necessity of screening during pregnancy: a clinical and seroepidemiologic study. *Yonsei Med J* 2012;53:401-7.
- 6) Kucera P, Gerber S, Marques-Vidal P, Meylan PR. Seroepidemiology of herpes simplex virus type 1 and 2 in pregnant women in Switzerland: an obstetric clinic based study. *Eur J Obstet Gynecol Reprod Biol* 2012;160:13-7.
- 7) Xu F, Sternberg MR, Kottiri BJ, McQuillan GM, Lee FK, Nahmias AJ, et al. Trends in herpes simplex virus type 1 and type 2 seroprevalence in the United States. *JAMA* 2006;296:964-73.
- 8) Shin HS, Park JJ, Chu C, Song HJ, Cho KS, Lee JS, et al. Herpes simplex virus type 2 seroprevalence in Korea: rapid increase of HSV-2 seroprevalence in the 30s in the southern part. *J Korean Med Sci* 2007;22:957-62.
- 9) Statistics Korea. Korean Statistical Information Service. Available at [http://kosis.kr/statisticsList/statisticsList\\_01List.jsp?vwcd=MT\\_ZTITLE&parentId=A](http://kosis.kr/statisticsList/statisticsList_01List.jsp?vwcd=MT_ZTITLE&parentId=A) [accessed on 1 November 2013].
- 10) Corey L, Whitley RJ, Stone EF, Mohan K. Difference between herpes simplex virus type 1 and type 2 neonatal encephalitis in neurological outcome. *Lancet* 1988;331:1-4.
- 11) Whitley R, Arvin A, Prober C, Corey L, Burchett S, Plotkin S, et al. Predictors of morbidity and mortality in neonates with herpes simplex virus infections. The National Institute of Allergy and Infectious Diseases Collaborative Antiviral Study Group. *N Engl J Med* 1991;324:450-4.
- 12) Landry ML, Mullangi P, Nee P, Klein BR. Herpes simplex virus type 2 acute retinal necrosis 9 years after neonatal herpes. *J Pediatr* 2005;146:836-8.
- 13) Vossough A, Zimmerman RA, Bilaniuk LT, Schwartz EM. Imaging findings of neonatal herpes simplex virus type 2 encephalitis. *Neuroradiology* 2008;50:355-66.
- 14) Tiffany KF, Benjamin DK Jr, Palasanthiran P, O'Donnell K, Gutman LT. Improved neurodevelopmental outcomes following long-term high-dose oral acyclovir therapy in infants with central nervous system and disseminated herpes simplex disease. *J Perinatol* 2005;25:156-61.
- 15) Kimberlin DW, Whitley RJ, Wan W, Powell DA, Storch G, Ahmed A, et al. Oral acyclovir suppression and neurodevelopment after neonatal herpes. *N Engl J Med* 2011;365:1284-92.
- 16) Caviness AC, Demmler GJ, Swint JM, Cantor SB. Cost-effectiveness analysis of herpes simplex virus testing and treatment strategies in febrile neonates. *Arch Pediatr Adolesc Med* 2008;162:665-74.