

# Clinical Manifestations of Norovirus Infection in Korean Pediatric Cancer Patients

Hyunshin Choi, M.D., Young Bae Choi, M.D., Ji-Young Hwang, Ph.D.

Doo-Sung Cheon, Ph.D.\*, Hye Sook Jeong, Ph.D.\*, Yon Ho Choe, M.D.

Keon Hee Yoo, M.D., Ki Woong Sung, M.D., Hong Hoe Koo, M.D., and Yae-Jean Kim, M.D.

Department of Pediatrics, Sungkyunkwan University School of Medicine, Samsung Medical Center Seoul, Korea

Division of Enteric Viruses, Center for Infectious Diseases, Korea National Institute of Health Korea Centers for Disease Control and Prevention, Osong, Korea\*

**Purpose :** Norovirus infection, a common cause of community-acquired gastroenteritis, can also lead to severe illness in immunocompromised patients. We investigated clinical manifestations of norovirus infection in pediatric cancer patients.

**Methods :** Stool specimens were collected from pediatric patients with gastrointestinal symptoms between November 2008 and September 2009 at Samsung Medical Center, Seoul, Korea. Norovirus infection was identified by reverse-transcription polymerase chain reaction (RT-PCR). A retrospective chart review was performed in pediatric cancer patients who were diagnosed with norovirus infection.

**Results :** Ten patients were diagnosed with norovirus infection by RT-PCR in stool samples. The median age was 0.83 years (range 0.25–5.5 years) and the male to female ratio was 1.5:1 (6 males and 4 females). Underlying diseases were hematologic malignancies (4/10, 40%), neuroblastoma (4/10, 40%), and brain tumors (2/10, 20%). Three patients were infected before hematopoietic cell transplantation (HCT) and four patients after HCT. All patients had diarrhea (10/10, 100%), with a median frequency of diarrhea of 8.5 times/day (range 4–22 times/day). Median virus shedding duration was 72.5 days (range 19–299 days). Four patients with pneumatosis intestinalis were conservatively treated with bowel rest and total parenteral nutrition. One patient with severe diarrhea and bloody stool had concomitant chronic gut graft-versus-host disease (GVHD). Norovirus infection-related mortality was not observed.

**Conclusion :** Norovirus infection can cause significant clinical manifestations with prolonged viral shedding in immunocompromised patients. Norovirus should be considered in pediatric cancer patients with severe gastrointestinal symptoms. (Korean J Pediatr Infect Dis 2011;18:40–47)

**Key Words :** Human calicivirus, Norovirus, Immunocompromised host, Children

## Introduction

Norovirus, a common cause of community-acquired gastroenteritis<sup>1)</sup>, can cause clinical symptoms

even with a low infective dose (<100 virus particles). Prolonged asymptomatic shedding has been reported in certain infected patients. The viruses are also known to be highly resistant to inactivation by freezing, heating to 60°C, exposure to chlorine, and treatment with ether, ethanol, or detergent-based cleaners<sup>2, 3)</sup>. Diarrhea and vomiting are commonly accompanied by fever and abdominal pain in norovirus infection. In immunocompetent individuals, symptoms last for about 3 to 4 days and infection

Received : 19 October 2010, Revised : 23 October 2010

Accepted : 24 October 2010

Correspondence : Yae-Jean Kim, M.D.

Department of Pediatrics, Sungkyunkwan University School of Medicine, Samsung Medical Center, Korea

Tel : +82-2-3410-0987, Fax : +82-2-3410-0043

E-mail : yaejeankim@skku.edu

is usually self-limited<sup>1, 4, 5)</sup>. Excretion lasts 5 to 7 days after onset of symptoms and asymptomatic shedding of virus in feces may continue for up to 3 weeks<sup>6)</sup>. In contrast, immunocompromised patients often suffer from prolonged symptoms and severe illnesses. Roddie et al. reported that norovirus infection could cause prolonged morbidity in adults after allogeneic hematopoietic stem cell transplantation (HCT)<sup>7)</sup>. Pediatric cancer patients must be closely monitored for prolonged viral shedding to protect them from severe norovirus-related complications<sup>2)</sup>.

Although the impact of norovirus infection in immunocompromised patients has started to receive more attention, little has been described in Korean immunocompromised children. Here, we summarized the clinical manifestations of norovirus infection in ten immunocompromised children.

## Materials and Methods

### 1. Clinical samples and data collection

Stool specimens from pediatric cancer patients who presented with gastrointestinal symptoms such as vomiting, diarrhea, fever, poor oral intake and/or abdominal pain between November 2008 and September 2009 at Samsung Medical Center, Seoul, Korea were examined for the presence of norovirus. Within a median four days after symptom onset, norovirus infection was confirmed by PCR at the Korea Centers for Disease Control and Prevention (KCDC), Seoul, Korea. In addition, RT-PCR for rotavirus, sapovirus, adenovirus, and astrovirus was performed at the KCDC for all patients. Stool culture, rotavirus antigen test, enterovirus PCR, and enzyme-linked fluorescent immunoassay (ELISA)

for detection of *Clostridium difficile* toxins A and B were also performed. Clinical data were collected by retrospective chart review. Follow-up PCR tests for norovirus were continued until the patients cleared the virus. When the patients became asymptomatic during recovery period, RT-PCR tests only for norovirus, rotavirus, sapovirus, adenovirus, and astrovirus were performed at the KCDC. When the patient had waxing and waning symptoms, all the tests same as initial tests were performed.

### 2. Extraction and identification of viral genome

The viral genome was extracted from stool suspensions with the QIAamp viral kit (Qiagen, Valencia, CA) according to the manufacturer's instructions. Infection with noroviruses was confirmed by PCR assay as previously described<sup>8)</sup>.

Briefly, norovirus reverse-transcription polymerase chain reaction (RT-PCR) was performed in the followings. The primary RT-PCR mix contained 12.5  $\mu$ L of 2 $\times$  RT-PCR Master mix (Bioneer, Korea), 10 pmol of the type-specific sense primer (5'-GGG AGG GCG ATC GCA ATC T-3'), 10 pmol of the antisense primer (5'-CCR CCI GCA TRI CCR TTR TAC AT-3'), and 2.5  $\mu$ L of virus extracts in a final aqueous volume of 25  $\mu$ L. Using a thermocycler (GeneAmp PCR system 2700, Perkin-Elmer, USA), cDNA was amplified at the primary RT-PCR step that was consisted of reverse transcription at 48°C for 40 min and followed by denaturation (94°C for 3 min), 35 cycles of amplification (94°C for 30 s, 54°C for 30 s, and 72°C for 45 s), and a final incubation (72°C for 7 min).

The secondary seminested PCR reaction contained of 12.5  $\mu$ L of 10 $\times$  PCR reaction buffer, 2.5 mM of dNTP, 1 U of Taq polymerase (Bioneer, Korea),

and 20 pmol of the second antisense primer (5'-GGG AGG GCG ATC GCA ATC T-3') was added with 2  $\mu$ L of the primary RT-PCR and then amplified by denaturation (94°C for 3 min), 25 cycles of amplification (94°C for 30 s, 56°C for 30 s, and 72°C for 45 s), and a final extension (72°C for 7 min).

The final amplification products were electrophoresed in 1% LE agarose (Gibco, USA). Bands were visualized by staining with ethidium bromide and then inspected under UV light.

## Results

### 1. Patient characteristics

One hundred thirty-six stool samples from 69 pediatric patients were collected and tested for norovirus infection by PCR. Norovirus was detected in 55 samples of 14 patients (14/69, 20.3%). Among these patients, ten were immunocompromised (Table 1) with underlying hematologic diseases (4/10, 40%), neuroblastoma (4/10, 40%), and brain tumors (2/10, 20%). At the time of initial norovirus

isolation, all of the patients had no other proven gut pathogens except norovirus. The median age was 0.83 years (range 0.25–5.5 years) and the male to female ratio was 1.5:1 (6 males and 4 females). Three patients received autologous HCT (3/7, 43%) and four received allogeneic HCT (4/7, 57%). Four patients received HCT twice (autologous HCT in three patients and allogeneic HCT in one patient). Four patients were infected after HCT and three before HCT. Among the four allogeneic HCT recipients, one patient had severe chronic gut graft-versus-host disease (GVHD).

### 2. Clinical presentation, management and outcome

Clinical manifestations of the included patients are summarized in Table 2. Three patients developed symptoms during hospitalization and seven patients developed symptoms in the community. All patients had diarrhea (10/10, 100%), with a median frequency of 8.5 times/day (range 4–22 times/day). In our study, diarrhea was the chief complaint and patients had prolonged duration of the symptom for a median of 14 days (range 6–30 days). All patients

**Table 1.** Summary of Clinical Characteristics of Patients with Norovirus Infection

Patient ID	Underlying disease*	Age/sex	HCT <sup>†</sup>	Gut GVHD <sup>‡</sup>	Use of immunosuppressive agent at diagnosis
1	WAS	4.0/M	Allo	Yes	Yes (steroid, mycophenolate, tacrolimus)
2	Relapsed ALL	5.5/M	Allo	No	No
3	PNET	1.3/F	Auto (2 times)	No	No
4	Neuroblastoma	0.7/M	–	No	No
5	JMML	0.4/M	Allo	No	No
6	Relapsed AML	1.8/M	Allo (2 times)	No	No
7	PNET	0.5/M	Auto (2 times)	No	No
8	Neuroblastoma	0.8/F	–	No	No
9	Neuroblastoma	0.5/M	–	No	No
10	Neuroblastoma	1.8/F	Auto (2 times)	No	No

\*Underlying diseases: ALL (acute lymphoid leukemia), AML (acute myeloid leukemia), JMML (juvenile myelomonocytic leukemia), PNET (primitive neuroectodermal tumor), WAS (Wiskott-Aldrich syndrome)

<sup>†</sup>HCT (hematopoietic cell transplantation)

<sup>‡</sup>GVHD (graft-versus-host disease)

had watery diarrhea and two patients also had bloody diarrhea. Vomiting (4/10, 40%) was also present, mainly during the early phase of illness. Most patients did not have significant weight loss during the acute illness except one patient who lost 10% of body weight. Only 2 patients (20%) experienced fever over 38°C by axillary temperature. Six patients (60%) had neutropenia with an absolute neutrophil count below  $0.5 \times 10^3/\mu\text{L}$  at the time of virus isolation (Table 2). Median virus shedding duration was 72.5 days (range 19–299 days). The shedding duration of each patient relative to their transplant date is shown in Fig. 1. All ten patients needed hospitalization and nutrition support. The median duration from symptom development to recovery during initial infection was 14 days (range 6–30 days). Nine patients (90%) received empirical antibiotic therapy. Four patients (patient 1, 4, 7, and 9) developed pneumatosis intestinalis, with or mural gas shown by abdominal X-ray. Three had pneumatosis intestinalis as their initial presentation and one patient had it in the third month during his

viral shedding period. All four required bowel rest and total parenteral nutrition. Mortality from all causes was 40% (4/10), and included death from venocclusive disease and massive hemorrhage (patient 5), pneumonia and acute respiratory distress syndrome (ARDS) (patient 6), and disease progression (patients 3 and 8). The four patients with pneumatosis intestinalis survived, and norovirus infection-associated death was not observed.

Among the patients with pneumatosis intestinalis, patient 1 had the most convoluted clinical course, with the longest duration of virus shedding (299 days). This patient received an unrelated peripheral blood stem cell transplantation for Wiskott–Aldrich syndrome. He developed severe gut and skin GVHD, for which he received rituximab (anti-CD20 monoclonal antibody) before day 100 post-transplantation and infliximab (anti-TNF- $\alpha$  monoclonal antibody) between days 100 and 200 post-transplantation. He then presented with additional gastrointestinal symptoms on day 225 post-transplant (in November 2008) while he was on oral prednisone,

**Table 2.** Clinical Manifestations with Norovirus Infection in Immunocompromised Children

Patient ID	Diarrhea/Vomiting	Max. Diarrhea frequency (times/day)	From initial symptom to recovery (days)	Viral shedding (days)	Body temperature* (°C)	ANC <sup>†</sup> ( $\times 10^3/\mu\text{L}$ )	Tube feeding	Pneumatosis intestinalis	Overall Survival
1	Yes/No	7	30 <sup>‡</sup>	299	36.9	2.46	No	Yes	Yes
2	Yes/No	11	10	126	37.0	0.15	No	No	Yes
3	Yes/No	4	9	89	37.3	3.30	Yes	No	No
4	Yes/No	10	15	199	37.3	0	No	Yes	Yes
5	Yes/Yes	5	8	21	38.0	0.01	No	No	No
6	Yes/Yes	14	26	56	39.6	0	No	No	No
7	Yes/Yes	22	21	100	37.1	0.04	Yes	Yes	Yes
8	Yes/Yes	5	6	35	37.7	0	No	No	No
9	Yes/No	14	13	19	37.5	1.84	No	Yes	Yes
10	Yes/No	7	21	46	37.3	1.16	Yes	No	Yes
Median	–	8.5	14	72.5	37.3	0.10	–	–	–

\*Maximum body temperature during diarrheal illness

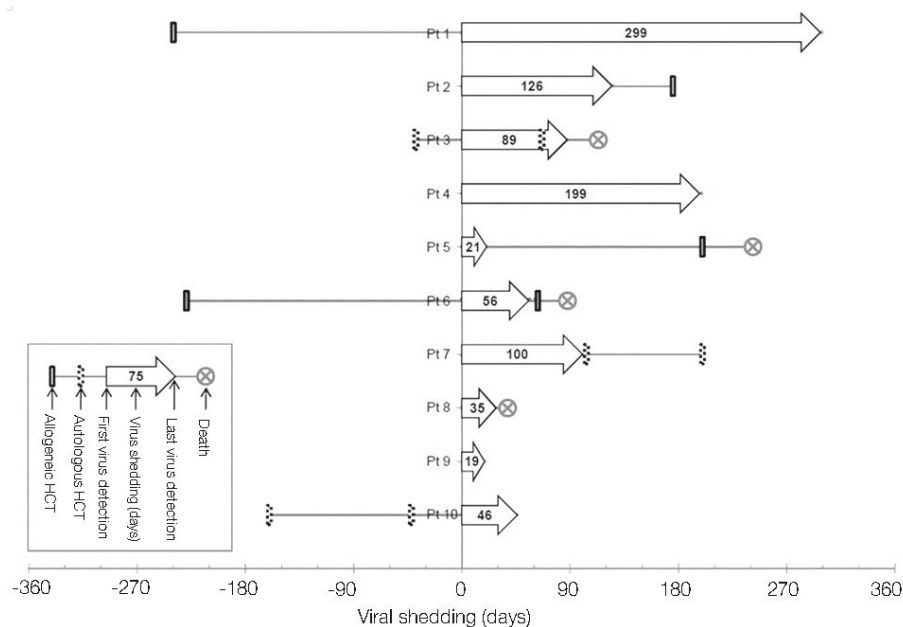
<sup>†</sup>ANC (absolute neutrophil count) at the first day of positive norovirus detection

<sup>‡</sup>The duration of patient 1 represents the initial gastrointestinal symptom episode

mycophenolate, and tacrolimus. His worsening symptoms were attributed to GVHD aggravation and immunosuppression was increased. He further developed pneumatosis intestinalis and a PCR test for norovirus was sent out to the KCDC on post-transplant day 240. Because of the time delay in receiving results from the KCDC, the patient started infliximab on day 247, since all the other available tests were negative, CMV enterocolitis was not present, and the patient's condition was deteriorating. The report came back positive for norovirus infection on day 255 and the patient went home on day 265 with symptom improvement. He continued to have waxing and waning diarrheal episodes and received 4 additional colonoscopies on post-transplant day 340, 433, 453, and 560. Of note, from day 454, colonoscopy started to show pathology findings

compatible with ulcerative colitis (UC). Mesalazine was started in addition to other immunosuppressants and the patient's condition improved. The patient eventually became norovirus negative on post-transplant day 539.

Patients 2, 5, 6, and 7 had norovirus infection and shed virus for 126, 21, 56 and 100 days before HCT, respectively. After norovirus was cleared, they each received HCT. Patient 3 received his second autologous HCT during the virus shedding period. Although he did not appear to have significant norovirus infection-related complications during the immediate post-transplant period, he died of disease progression during the period after second transplant period (Fig. 1). Virus shedding duration and the time from infection to HCT and mortality are summarized in Fig. 1.



**Fig. 1.** Viral shedding duration of each patient. Each patient's first virus detection day is aligned on y axis. Numbers on x axis represents the pre and post days from viral shedding day 0 (first virus detection day). The each arrow bar shows the virus shedding duration from the first to the last virus detection day. The time points of allogeneic hematopoietic cell transplantation (HCT) and autologous HCT are marked with the boxes with solid lines and with dotted lines, respectively.

## Discussion

Noroviruses are one of the most common causes of both outbreaks and sporadic cases of acute gastroenteritis<sup>4, 9, 10</sup>. Because immunocompromised patients are vulnerable to pathogens circulating in the community, norovirus infection can impact their clinical course. This study summarized the clinical manifestations of norovirus in infected immunocompromised Korean children.

In Korea, norovirus-associated infections constitute up to 12–15% of acute viral gastroenteritis, with a seasonality peaking between December and March<sup>11, 12</sup>. Norovirus infection can also cause severe disease with significant morbidity in immunocompromised patients. Pediatric cancer patients are at risk of delayed clinical recovery and may require subsequent in-patient treatment<sup>13</sup>. Since most cancer patients experience mucositis, diarrhea, and vomiting<sup>14</sup> due to their cancer therapy, it is challenging to diagnose norovirus infection based on clinical presentation. In addition, it is difficult to determine the exact role of norovirus in such situations. Nonetheless, it is important for clinicians to consider norovirus infection as a possible pathogen, in addition to cancer-related toxicity or other types of infections. When this infection occurs in allogeneic transplant recipients, it can be particularly difficult to judge clinical condition and make treatment plans due to concerns over GVHD<sup>15</sup>.

Norovirus infection manifested itself in a variety of ways in the allogeneic HCT recipients we evaluated. The clinical course of patient 1 was of particular interest, since he had a very convoluted and prolonged course of norovirus infection that was

complicated by gut GVHD and later, UC. In truth, the isolation of norovirus from patient 1 caused us to test for norovirus infection in other patients going forward. The true beginning of this patient's norovirus infection remains unclear, because he was not tested during previous diarrheal episodes. However, because norovirus usually circulates during the winter months, it is highly likely that patient 1 acquired the infection somewhere around this time (the first detection occurred in November). During the initial infection period, gut symptom improvement was observed temporarily after infliximab treatment, making it unclear how much of a role norovirus infection played in the clinical course of patient 1 during this period. After norovirus was identified, efforts to reduce immune suppression were made, but the patient continued to have recurrent aggravating symptoms. Even though the patient still shed norovirus in the stool, he was treated with continuing immunosuppression in addition to UC treatment, which led to symptom improvement. This case poses many unanswered questions, and it is particularly difficult to delineate the proportional contributions of norovirus infection, pathology-confirmed GVHD, and pathology-confirmed UC. The patient's complicated clinical course might have been partly due to norovirus infection, but GVHD and UC could have also been responsible for this patient's severe gut symptoms. Whether norovirus was the aggravating factor or the confounding factor for GVHD and UC is unclear.

The observation that four patients developed pneumatosis intestinalis in our study was also interesting. Three of these patients were younger than one year old. Based on our experience with these patients, we now always test for norovirus infection in

infants, particularly those who develop pneumatosis intestinalis. More data from other investigators is needed to confirm our observations of norovirus infection-associated pneumatosis intestinalis, as it may represent another important serious complication in these high risk patients.

Patients in our study also showed prolonged viral shedding, with a median value of 72.5 days (range, 19–299 days), which was in agreement with previous reports<sup>2,7)</sup>. All of our patients in this study had symptomatic initial infection and most of them had prolonged asymptomatic viral shedding during recovery period. Because the clinical course of immunocompromised patients changes during their cancer treatment, norovirus infection needs careful monitoring and assessment in this setting.

This study was limited in scope, since it was a retrospective study of only ten pediatric patients, including four allogeneic HCT. This study did not include a control group such as adult immunocompromised patients or immunocompetent children to compare the clinical manifestations of norovirus infection. Since we only tested symptomatic patients, it is not possible to describe whether there were asymptomatic infection cases. In addition, we did not analyze any association between viral load in the stool and symptom severity. This study does not contain genotype and sequence data in conjunction with hospitalization time-line and rooms used by patients to determine whether they were epidemiologically linked for a possible nosocomial infection in our pediatric cancer ward. We plan to explore some of these data further in the future study.

This study is the first report on norovirus infection in pediatric HCT recipients and associated implications for managing pediatric cancer patients with

severe intestinal symptoms in Korea. Awareness is a key first step in diagnosing norovirus infection, and pediatricians who monitor these high risk patients should be familiar with its presentation and occurrence. Norovirus infection may have a significant impact on the clinical conditions of immunocompromised pediatric cancer patients, and should be considered along with chemotherapy-related complications or other pathogens in the event of gastrointestinal symptoms.

## 한 글 요약

### 한국 소아 암환자에서 노로바이러스 감염증의 임상 양상

성균관대학교 의과대학 삼성서울병원 소아청소년과  
질병관리본부 간염폴리오바이러스과\*

최현신 · 최영배 · 황지영 · 천두성\* · 정혜숙\* · 최연호  
유건희 · 성기웅 · 구홍희 · 김예진

**목 적 :** 노로바이러스는 바이러스성 설사의 흔한 원인이며, 면역 저하 환자에서도 심각한 감염증을 유발하는 것으로 알려져 있어, 소아 암환자에서 노로바이러스 감염의 임상 양상을 알아보고자 하였다.

**방 법 :** 2008년 11월부터 2009년 9월까지 삼성 서울 병원에 입원한 환자 중 대변에서 노로바이러스 PCR 양성을 보였던 소아 암환자를 대상으로 하였고, 이들의 의무기록을 후향적으로 분석하였다

**결 과 :** 연구에 포함된 환자는 총 10명이었으며, 이들 연령의 중앙값은 0.83세, 남녀의 비율은 1.5대 1이었다. 기저질환은 혈액암 4명, 신경모세포종 4명, 뇌종양 2명이었고, 감염 진단 당시 조혈모세포이식 수여자 4명이었다. 모든 환자에서 설사 증상을 보였으며, 설사 횟수의 중앙값은 8.5회/일, 바이러스 배출 기간의 중앙값은 72.5일이었다. 장기중 소견을 보인 4명의 환자는 금식 및 총정맥 영양을 투여 받았으며, 노로바이러스 관련 사망은

관찰되지 않았다.

**결 론 :** 노로바이러스 감염은 소아 암환자에서 다양한 임상 증상을 유발 할 수 있으며, 이들 면역저하 환자에서 바이러스 배출 기간이 매우 길어, 설사가 있는 암환자에서 고려해야 할 바이러스 감염이다.

## References

- 1) Koopmans M, Duizer E. Foodborne viruses: an emerging problem. *Int J Food Microbiol* 2004;90:23-41.
- 2) Simon A, Schildgen O, Maria Eis-Hübinger A, Hasan C, Bode U, Buderus S, et al. Norovirus outbreak in a pediatric oncology unit. *Scand J Gastroenterol* 2006;41: 693-9.
- 3) Rockx B, De Wit M, Vennema H, Vinjé J, De Bruin E, Van Duynhoven Y, et al. Natural history of human calicivirus infection: a prospective cohort study. *Clin Infect Dis* 2002;35:246-53.
- 4) Moreno-Espinosa S, Farkas T, Jiang X. Human caliciviruses and pediatric gastroenteritis. *Semin Pediatr Infect Dis* 2004;15:237-45.
- 5) Kaplan JE, Feldman R, Campbell DS, Lookabaugh C, Gary GW. The frequency of a Norwalk-like pattern of illness in outbreaks of acute gastroenteritis. *Am J Public Health* 1982;72:1329-32.
- 6) Pediatrics CoIDotAAo. Red Book, 2009.
- 7) Roddie C, Paul JP, Benjamin R, Gallimore CI, Xerry J, Gray JJ, et al. Allogeneic hematopoietic stem cell transplantation and norovirus gastroenteritis: a previously unrecognized cause of morbidity. *Clin Infect Dis* 2009; 49:1061-8.
- 8) Kim SH, Cheon DS, Kim JH, Lee DH, Jheong WH, Heo YJ, et al. Outbreaks of gastroenteritis that occurred during school excursions in Korea were associated with several waterborne strains of norovirus. *J Clin Microbiol* 2005; 43:4836-9.
- 9) Siebenga JJ, Vennema H, Zheng DP, Vinjé J, Lee BE, Pang XL, et al. Norovirus illness is a global problem: emergence and spread of norovirus GII.4 variants, 2001-2007. *J Infect Dis* 2009;200:802-12.
- 10) Boga JA, Melón S, Nicieza I, De Diego I, Villar M, Parra F, et al. Etiology of sporadic cases of pediatric acute gastroenteritis in Asturias, Spain, and genotyping and characterization of norovirus strains involved. *J Clin Microbiol* 2004;42:2668-74.
- 11) Laboratory Surveillance of Viral Acute Gastroenteritis, 2005-2008. Division of enteric viruses, Korea Centers for Disease Control and Prevention 2010.
- 12) Yoon JS, Lee SG, Hong SK, Lee SA, Jheong WH, Oh SS, et al. Molecular epidemiology of norovirus infections in children with acute gastroenteritis in South Korea in November 2005 through November 2006. *J Clin Microbiol* 2008;46:1474-7.
- 13) Ludwig A, Adams O, Laws HJ, Schroten H, Tenenbaum T. Quantitative detection of norovirus excretion in pediatric patients with cancer and prolonged gastroenteritis and shedding of norovirus. *J Med Virol* 2008;80:1461-7.
- 14) Barker CC, Anderson RA, Sauve RS, Butzner JD. GI complications in pediatric patients post-BMT. *Bone Marrow Transplant* 2005;36:51-8.
- 15) Koo HL, DuPont HL. Noroviruses as a potential cause of protracted and lethal disease in immunocompromised patients. *Clin Infect Dis* 2009;49:1069-71.