

Comparison of the three-dimensional structures of mandibular condyles between adults with and without facial asymmetry: A retrospective study

Min-Hee Oh^a
Sung-Ja Kang^a
Jin-Hyoung Cho^{a,b}

^aDepartment of Orthodontics, School of Dentistry, Chonnam National University, Gwangju, Korea

^b4D Research Institute, Chonnam National University, Gwangju, Korea

Objective: This retrospective study compared the three-dimensional (3D) structure of mandibular condyles between adults with and without facial asymmetry, and whether it influences menton deviation. **Methods:** Sixty adult patients were classified into symmetry and asymmetry groups based on the menton deviation on postero-anterior radiographs. The right/left differences of 3D measurements were compared between the two groups, and measurements were compared separately on the right and left sides. The correlations between menton deviation and the right/left differences were analyzed. **Results:** The mediolateral dimension, neck length, condylar angles to the anteroposterior reference (PO) and midsagittal reference planes, and neck and head volumes showed significantly larger right/left differences in the asymmetry group compared to the symmetry group. Separate comparisons of the right and left sides between the two groups showed that the neck was significantly shorter and neck and head volumes were significantly smaller on the left side, which was deviated side in the asymmetry group. Pearson's correlation analysis showed significant positive correlations of menton deviation with right/left differences in neck length, condylar angle to the PO plane, and neck and head volumes in the asymmetry group. **Conclusions:** In individuals with facial asymmetry, menton deviation is associated with the right/left differences caused by a smaller condyle on the deviated side, particularly in neck length and neck and head volumes.

[Korean J Orthod 2018;48(2):73-80]

Key words: Facial asymmetry, Mandibular condyle, Three-dimensional structures, Menton deviation

Received April 20, 2017; Revised August 10, 2017; Accepted September 1, 2017.

Corresponding author: Jin-Hyoung Cho.

Professor, Department of Orthodontics, School of Dentistry, Dental 4D Research Institute, Chonnam National University, 33 Yongbong-ro, Buk-gu, Gwangju 61186, Korea.

Tel +82-62-530-5818 **e-mail** jhcho@jnu.ac.kr

The authors report no commercial, proprietary, or financial interest in the products or companies described in this article.

© 2018 The Korean Association of Orthodontists.

This is an Open Access article distributed under the terms of the Creative Commons Attribution Non-Commercial License (<http://creativecommons.org/licenses/by-nc/4.0>) which permits unrestricted non-commercial use, distribution, and reproduction in any medium, provided the original work is properly cited.

INTRODUCTION

With the increased interest in facial esthetics, facial asymmetry is one of the most common complaints of orthodontic patients, and thus, it is necessary to understand the underlying causes and aspects of facial asymmetry.

Facial asymmetry was known to be influenced more by the mandible than the maxilla^{1,2} and menton deviation has been reported to be the primary contributing factor in perceiving facial asymmetry.^{3,4} A previous study showed that mandibular asymmetry is influenced by a variety of factors including the condylar growth center, which directly or indirectly regulates the size of the condyle, and the length of the condylar neck.⁵ Moreover, persistently high condylar blood supply,⁶ condylar hyperplasia,⁷ fracture of the mandibular condyle,⁸ and internal derangement of the temporomandibular joint (TMJ)⁹ on one side influence facial asymmetry. However, these studies either used two-dimensional (2D) radiographic images^{5,7-9} or were *in vitro*.⁶ Evaluation of the TMJ using 2D radiographic images has a number of limitations such as distortion, elongation, and superimposition of the TMJ onto other anatomic structures.

The advances in three-dimensional (3D) technology such as computed tomography (CT) have overcome the limitations of 2D radiographic images.^{10,11} CT scan data can be used to assess linear and angular measurements after separating a necessary part such as the maxilla or mandible.¹²⁻¹⁴ Moreover, evaluation of the TMJ using CT has been reported to show higher accuracy than that using 2D radiographic images.^{15,16} For these reasons, CT data were used to evaluate the morphology of the normal TMJ,¹⁷⁻¹⁹ the correlations between pathologic changes of the TMJ and facial asymmetry,^{20,21} and TMJ morphology in facial asymmetry.²²⁻²⁴ However, these studies used 2D rather than 3D measurements.

Few studies have reported comparisons of mandibular condyles between adults with and without facial asymmetry. Fraga et al.²³ compared the anteroposterior position of the condyle in the mandibular fossa between individuals with normal occlusion and patients with Class I, Class II division 1, and Class III malocclusions. They reported that the greatest condylar decentralization was observed in the Class II group, whereas the least condylar decentralization was found in the normal occlusion group. Kim et al.²⁵ investigated the condyle-fossa relationship in skeletal Class III malocclusion patients with and without asymmetry and found statistically significant bilateral differences in the axial condylar angles in the group with asymmetry, whereas there were no significant differences in the symmetry group. Kim et al.²⁶ evaluated the volume and position of

TMJ structures in patients with mandibular asymmetry and showed that the volume of the condyle on the smaller condyle side was significantly smaller in the asymmetry group than in the control group. However, these studies evaluated the mandibular condyle in facial asymmetry using only 2D measurements of the TMJ space^{23,25} and axial condylar angles.²⁵ Although Kim et al.²⁶ performed a 3D evaluation of TMJ volume, they compared volumes between smaller and larger condyle sides, not between the deviated and non-deviated sides.

The purpose of the present study was to compare the 3D structure of mandibular condyles between adults with and without facial asymmetry and determine whether it influences menton deviation. The hypothesis was that the differences of condylar structure between deviated and non-deviated sides in facial asymmetry affect menton deviation.

MATERIALS AND METHODS

Study subjects

Institutional review board approval was granted by the committee of Chonnam National University Dental Hospital (No. CNUDH-2017-005). The present retrospective study included 60 adults, 30 (15 females and 15 males; mean age, 23.2 ± 3.8 years; 15 skeletal Class I and 15 skeletal Class III) in the asymmetry group and 30 (17 females and 13 males; mean age, 24.6 ± 3.2 years; 15 skeletal Class I and 15 skeletal Class III) in the symmetry group. The inclusion criteria were as follows: age, > 20 years; no orthodontic treatment; no orthognathic surgery; no prosthetic treatment for more than a single crown; no pathologic TMJ changes; no systematic arthritis; no facial trauma; no craniofacial anomaly; and frontal and lateral cephalograms and CT acquired for orthodontic diagnosis before treatment. Patients with skeletal Class II malocclusion, which is commonly caused by abnormalities of the mandible,²⁷ were excluded.

Subjects were divided into two groups, symmetry and asymmetry, based on the amount of menton deviation,^{3,4} which is the angle between the line drawn from the anterior nasal spine (ANS) to the menton and the vertical reference line drawn from the crista galli to the ANS, on postero-anterior (PA) radiographs acquired before treatment. A menton deviation on PA radiographs exceeding 2° toward the left was considered to indicate asymmetry; menton deviation not exceeding 2° toward the right or left was considered to indicate symmetry.²⁸ The asymmetry group consisted of subjects with menton deviation toward only the left side. Thus, the right side was the non-deviated side, and the left side was the deviated side in the asymmetry group.

Table 1. Three-dimensional landmarks used in this study

Landmark	Abbreviation	Description
Crista galli	Cg	The most superior point of the crista galli of the ethmoid bone
Opisthion	Op	The most posterior point on the posterior margin of the foramen magnum
Porion	Po	The highest point on the roof of the external auditory meatus
Orbitale	Or	The deepest point on the infraorbital margin
Condylion superius	Cd _{sup}	The most superior point of the condyle head
Condylion medialis	Cd _{med}	The most medial point of the condyle head
Condylion lateralis	Cd _{lat}	The most lateral point of the condyle head
Condylion antierius	Cd _{ant}	The most anterior point of the condyle head
Condylion posterius	Cd _{post}	The most posterior point of the condyle head
Sigmoid notch	S	The most inferior point of sigmoid notch

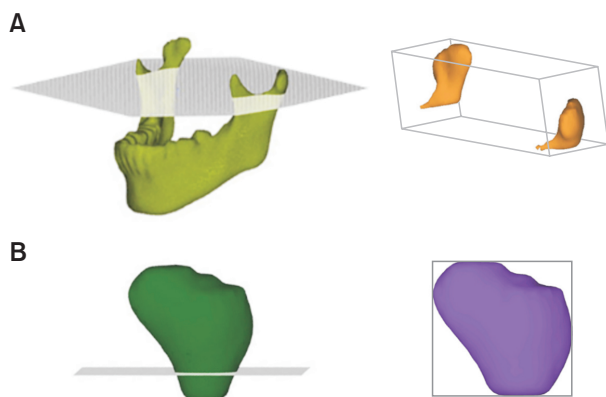


Figure 1. Formation of three-dimensional images. The neck (A) and head (B) selection of demand (SOD) files were separated from the mandible SOD file which was separated from the whole volume rendering image by removing overlapping areas using the sculpt functions of program (V-works; CyberMed Inc., Seoul, Korea).

Image acquisition and processing

CT scans were obtained with a CT scanner (Light Speed QX/i; GE Medical Systems, Milwaukee, WI, USA) under the following conditions: 2.5-mm slice thickness, 0.8-second scan time, 120 kV, 200 mA, slice pitch: 3, scanning matrix: 512×512 pixels, field of view: 180 mm, gantry angle: 0° . All patients were placed in the supine position with the Frankfort horizontal plane (FH plane) perpendicular to the ground, and the midline of the maxillary dental arch was adjusted to match the axis of the X-ray beam.

The Digital Imaging and Communication in Medicine data were reconstructed into 3D images using V-works software version 4.0 (CyberMed Inc., Seoul, Korea). Definitions of the landmarks are illustrated in Table 1. The 3D reference planes were constructed as reported in a previous study.²⁹ The FH plane passed through

the right and left porions and the right orbitale. The midsagittal reference plane (MSR plane) was the plane perpendicular to the FH plane passing through crista galli and opisthion. The anteroposterior reference plane (PO plane) was the plane perpendicular to the FH plane passing through right and left porions.

In order to ensure the precise identification of landmarks, the mandible was separated from the whole volume rendering image by removing overlapping areas using the sculpt functions of the V-works program. The separated mandible image was exported into a selection of demand (SOD) file. Moreover, for the accurate comparison of the volumetric measurements, the neck SOD file, which included the condylar process for the upper sigmoid notch, and the head SOD file, which included the upper part for the most contracted part of condylar neck, were separated from the mandible SOD file based on the FH plane (Figure 1).

Measurements

The mediolateral dimension was measured from the most medial point (Cd_{med}) to the most lateral point (Cd_{lat}) of the condylar head, and the anteroposterior dimension was defined as the distance between the most anterior (Cd_{ant}) and posterior (Cd_{post}) points, which were points on the perpendicular line at the midpoint of the line drawn from Cd_{med} to Cd_{lat}. The neck length was measured from the most superior point (Cd_{sup}) of the condylar head to the sigmoid notch (S) of the mandible. The mediolateral condylar position was defined as the distance from Cd_{med} to the MSR plane. The condylar angles were measured in degrees between the condylar axis, which was the line drawn through Cd_{med} and Cd_{lat}, and the FH plane, PO plane, or MSR plane, respectively. The volumes of neck and head were calculated automatically with the V-works program after demarcation of the area in 3D data (Figure 2).

All measurements were performed by a single ope-

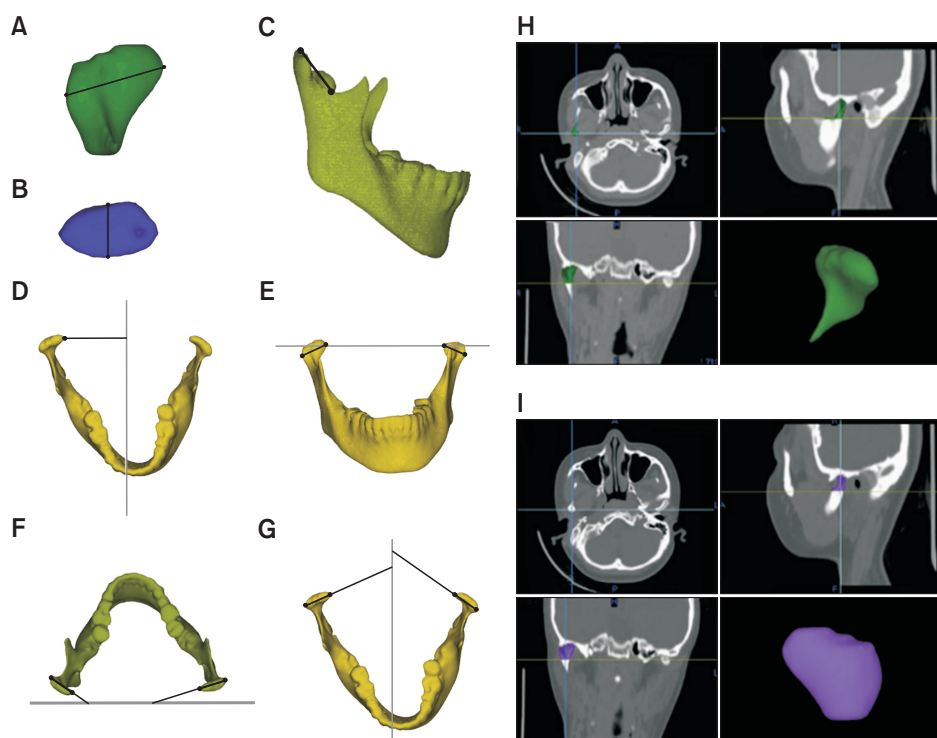


Figure 2. Three-dimensional measurements used in the present study. A, Mediolateral dimension of the condyle; B, anteroposterior dimension of the condyle; C, neck length; D, mediolateral condylar position; E, condylar angle to the Frankfort horizontal plane; F, condylar angle to the anteroposterior reference plane; G, condylar angle to the midsagittal reference plane; H and I, neck and head volumes (volumes are shown in the right top of each multiplanar reconstruction window).

Table 2. Description of the groups used in this study

Demographic characteristic	Symmetry (n = 30)	Asymmetry (n = 30)	p-value
Sex			
Female (%)	56.7	50.0	
Male (%)	43.3	50.0	
Age (yr)	24.6 ± 3.2	23.2 ± 3.8	0.059
Amount of menton deviation (°)	0.3 ± 1.3	5.7 ± 2.5	0.000*
ANB (°)	-0.4 ± 3.4	-0.5 ± 3.3	0.894
SN-MP (°)	33.0 ± 7.2	34.6 ± 6.3	0.337

Values are presented as percent only or mean ± standard deviation.

*Statistically significant.

rator. Twenty images were randomly selected and measurements were performed twice with a two-week interval to evaluate intra-observer reliability.

Statistical analysis

Statistical analyses were performed using IBM SPSS Statistics version 23.0 (IBM Co., Armonk, NY, USA). The reliability was assessed using the intraclass correlation coefficient (ICC); ICCs ranged from 0.982 to 0.999 for all variables, indicating excellent intra-observer reliability. The females and males were combined in each group because there were no statistical differences between

them in either group. An independent *t*-test was used to compare the differences between the symmetry and asymmetry groups and the separate right-side and left-side measurements between the two groups. In order to identify the causes of menton deviation, the correlations between menton deviation and the right/left differences were analyzed using Pearson's correlation analysis.

RESULTS

The demographic characteristics of the subjects in each group, including sex, age, amount of menton deviation, ANB which is the angle between the line drawn from nasion to A point and the line drawn from nasion to B point, on lateral cephalograms, and SN-MP which is the angle between the line drawn from sella to nasion and the line drawn from menton to gonion, on lateral cephalograms are presented in Table 2; only menton deviation showed significant differences ($p < 0.001$) between the symmetry and asymmetry groups.

Comparison of the right/left differences of 3D measurements between the symmetry and asymmetry groups

The right/left differences in mediolateral dimension and neck length differed significantly between the symmetry and asymmetry groups ($p < 0.01$). Comparisons of condylar position also showed significant right/left differences in the condylar angle to the PO plane

and the condylar angle to the MSR plane between the two groups ($p < 0.05$). In the comparisons of volumetric differences, the neck and head volumes showed significant right/left differences between the two groups ($p < 0.001$ and $p < 0.01$, respectively). The mediolateral dimension, neck length, condylar angles to the PO and MSR planes, and neck and head volumes showed significantly larger right/left differences in the asymmetry group (Table 3).

Comparison of the 3D measurements of condyles between the two groups on the right and left sides separately

The 3D structures of the condyles on the right side,

which was the non-deviated side in the asymmetry group, did not show significant differences between the symmetry and asymmetry groups. On the left side, which was the deviated side in the asymmetry group, the asymmetry group showed significantly smaller neck length and neck and head volumes than the symmetry group ($p < 0.05$; Table 4).

Correlations between the menton deviation and the right/left differences of 3D measurements in the asymmetry group

In the asymmetry group, menton deviation did not show a significant correlation with the right/left differences in mediolateral dimension or condylar angle

Table 3. Comparison of right/left differences in 3D measurements between symmetry and asymmetry groups

Measurement	Symmetry (n = 30)	Asymmetry (n = 30)	p-value
Mediolateral dimension (mm)	0.93 ± 0.75	1.90 ± 1.25	0.001*
Anteroposterior dimension (mm)	0.75 ± 0.66	0.86 ± 0.77	0.556
Neck length (mm)	1.13 ± 0.95	2.71 ± 2.46	0.002*
Mediolateral condylar position (mm)	1.60 ± 1.26	1.84 ± 1.19	0.462
Condylar angle to FH (°)	6.35 ± 15.44	5.94 ± 5.84	0.893
Condylar angle to PO (°)	3.73 ± 2.46	5.92 ± 4.11	0.015*
Condylar angle to MSR (°)	4.25 ± 2.95	8.39 ± 10.88	0.049*
Neck volume (mm ³)	203.73 ± 160.57	456.80 ± 319.36	0.000*
Head volume (mm ³)	216.87 ± 178.74	419.50 ± 284.63	0.002*

Values are presented as mean ± standard deviation.

FH, Frankfort horizontal plane; PO, anteroposterior reference plane; MSR, midsagittal reference plane.

*Statistically significant.

Table 4. Comparison of measurements between symmetry and asymmetry groups on the right and left sides

Measurement	Right (n = 30)			Left (n = 30)		
	Symmetry	Asymmetry	p-value	Symmetry	Asymmetry	p-value
Mediolateral dimension (mm)	21.82 ± 2.40	20.96 ± 2.78	0.205	21.57 ± 2.53	20.25 ± 3.12	0.078
Anteroposterior dimension (mm)	8.51 ± 1.47	8.49 ± 1.23	0.934	8.81 ± 1.38	8.11 ± 1.68	0.083
Neck length (mm)	27.40 ± 4.09	27.90 ± 3.43	0.608	27.70 ± 3.96	25.47 ± 3.96	0.033*
Mediolateral condylar position (mm)	42.88 ± 2.98	43.53 ± 2.72	0.381	42.65 ± 2.73	42.80 ± 2.66	0.826
Condylar angle to FH (°)	8.94 ± 6.11	12.31 ± 7.05	0.053	10.76 ± 17.17	10.22 ± 5.70	0.873
Condylar angle to PO (°)	13.05 ± 5.31	12.76 ± 5.41	0.832	12.12 ± 6.34	13.35 ± 6.45	0.460
Condylar angle to MSR (°)	73.63 ± 5.30	68.92 ± 12.19	0.057	74.87 ± 5.56	72.20 ± 5.80	0.074
Neck volume (mm ³)	2,797.98 ± 801.20	2,659.33 ± 770.71	0.497	2,815.95 ± 833.63	2,317.33 ± 769.30	0.019*
Head volume (mm ³)	2,359.99 ± 647.03	2,227.38 ± 708.02	0.452	2,332.88 ± 659.85	1,888.39 ± 658.68	0.011*

Values are presented as mean ± standard deviation.

Right, the right side in symmetry group and the non-deviated side in asymmetry group; Left, the left side in symmetry group and the deviated side in asymmetry group; FH, Frankfort horizontal plane; PO, anteroposterior reference plane; MSR, midsagittal reference plane.

*Statistically significant.

Table 5. Correlations between menton deviation and the right/left differences in each three-dimensional measurement in the asymmetry group (n = 30)

Measurement	r	p-value
Mediolateral dimension (mm)	0.187	0.323
Anteroposterior dimension (mm)	0.248	0.187
Neck length (mm)	0.688	0.000*
Mediolateral condylar position (mm)	-0.178	0.346
Condylar angle to FH (°)	0.272	0.145
Condylar angle to PO (°)	0.378	0.039*
Condylar angle to MSR (°)	-0.175	0.354
Neck volume (mm ³)	0.598	0.000*
Head volume (mm ³)	0.567	0.001*

FH, Frankfort horizontal plane; PO, anteroposterior reference plane; MSR, midsagittal reference plane.

*Statistically significant.

to the MSR plane ($p > 0.05$), but showed a significant positive correlation with the right/left differences in neck length ($r = 0.688$, $p < 0.001$), condylar angle to the PO plane ($r = 0.378$, $p < 0.05$), the neck volume ($r = 0.598$, $p < 0.001$), and head volume ($r = 0.567$, $p < 0.01$; Table 5).

DISCUSSION

Each individual perceives the degree of facial asymmetry differently, and these perceptions can be affected by many factors. For instance, greater facial asymmetry is perceived when amount of menton deviation increases.⁴ Lee et al.³ evaluated the relationship between the PA cephalometric measurements and visual facial asymmetry and reported that menton deviation was the most affected landmark in perceptions of facial asymmetry. Ferguson²⁸ assessed facial asymmetry using PA cephalograms and frontal photographs and found that facial asymmetry was perceived when the menton deviation from the midsagittal line was 2° or more. Menton deviation has been known to be an important indicator of facial asymmetry,^{3,4} and it influences both orthodontists' and patients' perceptions of facial asymmetry.³ Thus, it is necessary to understand the underlying causes of menton deviation in order to diagnose facial asymmetry and establish treatment plans.

Mandibular asymmetry is mediated by the condylar growth center,⁵ and is influenced by genetic and environmental factors. Moreover, mandibular asymmetry is a major cause of facial asymmetry.^{1,2} A number of studies have evaluated mandibular condyles in facial asymmetry,²²⁻²⁵ but they evaluated only the condyle-fossa relationship, not any 3D condylar structures.

Although Kim et al.²⁶ evaluated 3D condyle volumes, they compared volumes between smaller and larger condyle sides, not between deviated and non-deviated sides. Thus, the present study compared condyle morphology, position, and 3D volume between symmetry and asymmetry groups separately on the deviated and non-deviated sides.

When menton deviation, which is the primary contributing factor to perceive facial asymmetry,³ was more than 2°, facial asymmetry was in fact perceived in a previous report.²⁸ In the present study, subjects were divided into two groups, the asymmetry group with menton deviation more than 2° and the symmetry group with menton deviation less than 2°. The menton deviation in the asymmetry group ($5.7^\circ \pm 2.5^\circ$) differed significantly from that in the symmetry group ($0.3^\circ \pm 1.3^\circ$). However, the ANB and SN-MP angles, which indicate anteroposterior and vertical growth of the mandible, did not show statistically significant differences between the two groups. In terms of the subjects' demographic characteristics, horizontal and vertical growth factors in skeletal structures did not show significant differences between the two groups, whereas only menton deviation showed a statistically significant difference (Table 2). Moreover, considering the changes in the mandibular condyles with age, only adult patients were included, and patients with TMJ arthritis, pathologic TMJ changes, craniofacial anomaly, or facial trauma were excluded. Patients with skeletal Class II malocclusion were also excluded due to the possibility of mandibular growth disorder.²⁷

The mediolateral dimension, neck length, condylar angle to the PO plane, condylar angle to the MSR plane, neck volume, and head volume showed significantly larger right/left differences in the asymmetry group compared to the symmetry group (Table 3). However, comparison of the measurements between the two groups separately on the right and left sides did not show significant differences on the right side, the non-deviated side in the asymmetry group, whereas neck length, neck volume, and head volume showed significant differences on the left side, the deviated side in the asymmetry group (Table 4). These results indicate that in the asymmetry group, the right/left differences in neck length, neck volume, and head volume were caused by the condyles on the deviated side, whereas the right/left differences in mediolateral dimension, condylar angle to the PO plane, and condylar angle to the MSR plane were influenced by the condyles on both the deviated and non-deviated sides.

In addition, the neck was significantly shorter and the neck and head volumes were significantly smaller on the left side, i.e. the deviated side, in the asymmetry group (Table 4). Kim et al.²⁶ also reported that the condyle

volumes on the smaller condyle side were significantly smaller in their asymmetry group. These results indicate that the right/left differences in neck length, neck volume, and head volume in the asymmetry group were caused by smaller condyles on the deviated side.

The correlation analysis of menton deviation with the right/left differences in neck length, condylar angle to the PO plane, neck volume, and head volume in the asymmetry group showed significant positive correlations, indicating greater menton deviation with greater right/left differences in these measurements (Table 5). Thus, the right/left differences in neck length, condylar angle to the PO plane, and neck and head volumes need to be considered when evaluating menton deviation in facial asymmetry.

The present retrospective study has several limitations, including the use of the CT data taken in supine position. In supine position, the condyles might be placed more posteriorly which could affect condylar angles. Moreover, menton deviation, one of the contributing factors to facial asymmetry, is influenced by not only mandibular condyles but also mandibular fossa or body. Thus, future studies are needed that identify more correlations between facial asymmetry and mandibular body shape or the condyle-fossa relationship. In addition, the mandibular condyle and menton deviation can be affected by functional adaptation and the neuromuscular system. Although several studies found correlations between mandibular asymmetry and muscles and bone density,³⁰ trabecular bone patterns,³¹ and occlusal force,³² they did not evaluate 3D structures of the mandible and TMJ. Thus, studies about the effects of soft tissue and function in TMJ are also needed.

Despite these limitations, this study found that the right/left differences of 3D measurements differed between individuals with and without facial asymmetry. Moreover, menton deviation was associated with the right/left differences caused by a smaller condyle on the deviated side, in particular differences in neck length, and neck and head volumes, in individuals with facial asymmetry. These results could help predict aspects of facial asymmetry in adolescents, as well as help understand the aspects of asymmetry in adults with facial asymmetry.

CONCLUSION

In facial asymmetry, menton deviation is associated with the right/left differences caused by a smaller condyle on the deviated side, particularly in neck length, and neck and head volumes.

REFERENCES

1. Vig PS, Hewitt AB. Asymmetry of the human facial skeleton. *Angle Orthod* 1975;45:125-9.
2. Severt TR, Proffit WR. The prevalence of facial asymmetry in the dentofacial deformities population at the University of North Carolina. *Int J Adult Orthodon Orthognath Surg* 1997;12:171-6.
3. Lee GH, Cho HK, Hwang HS, Kim JC. Studies of relationship between P-A cephalometric measurements and vidual facial asymmetry. *Korean J Phys Anthropol* 1998;11:41-8.
4. Ahn JS, Hwang HS. Relationship between perception of facial asymmetry and posteroanterior cephalometric measurements. *Korean J Orthod* 2001;31:489-98.
5. Erickson GE, Waite DE. Mandibular asymmetry. *J Am Dent Assoc* 1974;89:1369-73.
6. Oberg T, Fajers CM, Lysell G, Friberg U. Unilateral hyperplasia of the mandibular condylar process. A histological, microradiographic, and autoradiographic examination of one case. *Acta Odontol Scand* 1962;20:485-504.
7. Bruce RA, Hayward JR. Condylar hyperplasia and mandibular asymmetry: a review. *J Oral Surg* 1968;26:281-90.
8. Proffit WR, Vig KW, Turvey TA. Early fracture of the mandibular condyles: frequently an unsuspected cause of growth disturbances. *Am J Orthod* 1980;78:1-24.
9. Trpkova B, Major P, Nebbe B, Prasad N. Craniofacial asymmetry and temporomandibular joint internal derangement in female adolescents: a posteroanterior cephalometric study. *Angle Orthod* 2000;70:81-8.
10. Kim KA, Lee JW, Park JH, Kim BH, Ahn HW, Kim SJ. Targeted presurgical decompensation in patients with yaw-dependent facial asymmetry. *Korean J Orthod* 2017;47:195-206.
11. Lee SY, Choi DS, Jang I, Song GS, Cha BK. The genial tubercle: A prospective novel landmark for the diagnosis of mandibular asymmetry. *Korean J Orthod* 2017;47:50-8.
12. Moaddab MB, Dumas AL, Chavoor AG, Neff PA, Homayoun N. Temporomandibular joint: computed tomographic three-dimensional reconstruction. *Am J Orthod* 1985;88:342-52.
13. Ono I, Ohura T, Narumi E, Kawashima K, Matsuno I, Nakamura S, et al. Three-dimensional analysis of craniofacial bones using three-dimensional computer tomography. *J Craniomaxillofac Surg* 1992;20:49-60.
14. Hwang HS. Maxillofacial 3-D image analysis for the diagnosis of facial asymmetry. *J Korean Dent Assoc* 2004;42:76-83.

15. Fava C, Preti G. Lateral transcranial radiography of temporomandibular joints. Part II: image formation studied with computerized tomography. *J Prosthet Dent* 1988;59:218-27.
16. Hilgers ML, Scarfe WC, Scheetz JP, Farman AG. Accuracy of linear temporomandibular joint measurements with cone beam computed tomography and digital cephalometric radiography. *Am J Orthod Dentofacial Orthop* 2005;128:803-11.
17. Pullinger A, Hollender L. Variation in condyle-fossa relationships according to different methods of evaluation in tomograms. *Oral Surg Oral Med Oral Pathol* 1986;62:719-27.
18. Christiansen EL, Chan TT, Thompson JR, Hasso AN, Hinshaw DB Jr, Kopp S. Computed tomography of the normal temporomandibular joint. *Scand J Dent Res* 1987;95:499-509.
19. Tsuruta A, Yamada K, Hanada K, Hosogai A, Kohno S, Koyama J, et al. The relationship between morphological changes of the condyle and condylar position in the glenoid fossa. *J Orofac Pain* 2004;18:148-55.
20. Kobayashi F, Matsushita T, Hayashi T, Ito J. A morphological study on the temporomandibular joint using X-ray computed tomography: relation to anterior disk displacement. *Dent Radiol* 1996;36:73-80.
21. Yamada K, Saito I, Hanada K, Hayashi T. Observation of three cases of temporomandibular joint osteoarthritis and mandibular morphology during adolescence using helical CT. *J Oral Rehabil* 2004;31:298-305.
22. Krisjane Z, Urtane I, Krumina G, Zepa K. Three-dimensional evaluation of TMJ parameters in Class II and Class III patients. *Stomatologija* 2009;11:32-6.
23. Fraga MR, Rodrigues AF, Ribeiro LC, Campos MJ, Vitral RW. Anteroposterior condylar position: a comparative study between subjects with normal occlusion and patients with Class I, Class II Division 1, and Class III malocclusions. *Med Sci Monit* 2013;19:903-7.
24. Minich CM, Araújo EA, Behrents RG, Buschang PH, Tanaka OM, Kim KB. Evaluation of skeletal and dental asymmetries in Angle Class II subdivision malocclusions with cone-beam computed tomography. *Am J Orthod Dentofacial Orthop* 2013;144:57-66.
25. Kim HO, Lee W, Kook YA, Kim Y. Comparison of the condyle-fossa relationship between skeletal class III malocclusion patients with and without asymmetry: a retrospective three-dimensional cone-beam computed tomography study. *Korean J Orthod* 2013;43:209-17.
26. Kim JY, Kim BJ, Park KH, Huh JK. Comparison of volume and position of the temporomandibular joint structures in patients with mandibular asymmetry. *Oral Surg Oral Med Oral Pathol Oral Radiol* 2016;122:772-80.
27. Ngan PW, Byczek E, Scheick J. Longitudinal evaluation of growth changes in Class II division 1 subjects. *Semin Orthod* 1997;3:222-31.
28. Ferguson JW. Cephalometric interpretation and assessment of facial asymmetry secondary to congenital torticollis. The significance of cranial base reference lines. *Int J Oral Maxillofac Surg* 1993;22:7-10.
29. Cho JH, Lee KM, Park HJ, Hwang HS. 3-D CT image study of effect of glenoid fossa on menton deviation. *J Korean Assoc Maxillofac Plast Reconstr Surg* 2011;33:337-45.
30. Maki K, Miller AJ, Okano T, Hatcher D, Yamaguchi T, Kobayashi H, et al. Cortical bone mineral density in asymmetrical mandibles: a three-dimensional quantitative computed tomography study. *Eur J Orthod* 2001;23:217-32.
31. Nakano H, Watahiki J, Kubota M, Maki K, Shibasaki Y, Hatcher D, et al. Micro X-ray computed tomography analysis for the evaluation of asymmetrical condylar growth in the rat. *Orthod Craniofac Res* 2003;6 Suppl 1:168-72; discussion 179-82.
32. Kurusu A, Horiuchi M, Soma K. Relationship between occlusal force and mandibular condyle morphology. Evaluated by limited cone-beam computed tomography. *Angle Orthod* 2009;79:1063-9.