

Immediate changes in the mandibular dentition after maxillary molar distalization using headgear

Sung-Ja Kang
Hyun-Hee Kim
Hyeon-Shik Hwang
Kyung-Min Lee

Department of Orthodontics, School
of Dentistry, Chonnam National
University, Gwangju, Korea

The purpose of this study was to investigate immediate changes in the mandibular dentition after maxillary molar distalization using headgear in non-growing patients. Sixteen patients (mean age, 18.9 ± 2.0 years) with Class II molar relationship and crowding were included in the present study. To correct the molar relationship, headgear was used for maxillary molar distalization. Cone-beam computed tomography-generated half-cephalograms (CG Ceph) and dental casts were used to evaluate dental changes for each subject before and immediately after molar distalization using headgear. The mean duration that subjects wore the headgear was 6.3 months. CG Ceph showed that the first maxillary molars were distalized 4.2 ± 1.6 mm with $9.7^\circ \pm 6.1^\circ$ of distal angulation. The intercanine, interpremolar, and intermolar widths of the mandible increased after maxillary molar distalization. The present study's results suggest that maxillary molar distalization using headgear induces a spontaneous response in the untreated mandibular dentition of non-growing patients.
[Korean J Orthod 2017;47(2):142-147]

Key words: Molar distalization, Mandibular dentition, Cone-beam computed tomography-generated half cephalograms

Received May 11, 2016; Revised July 17, 2016; Accepted August 8, 2016.

Corresponding author: Kyung-Min Lee.

Associate Professor, Department of Orthodontics, School of Dentistry, Chonnam National University, 33 Yongbong-ro, Buk-gu, Gwangju 61186, Korea

Tel +82-62-530-5864 **e-mail** ortholkm@chonnam.ac.kr

*This work was supported by a grant (CRI 14018-1) of Chonnam National University Hospital Biomedical Research Institute.

The authors report no commercial, proprietary, or financial interest in the products or companies described in this article.

© 2017 The Korean Association of Orthodontists.

This is an Open Access article distributed under the terms of the Creative Commons Attribution Non-Commercial License (<http://creativecommons.org/licenses/by-nc/4.0>) which permits unrestricted non-commercial use, distribution, and reproduction in any medium, provided the original work is properly cited.

INTRODUCTION

Maxillary molar distalization with skeletal anchorage is an efficient and noncompliance-dependent treatment modality for patients with a Class II molar relationship.¹⁻³ However, orthodontists are occasionally in challenging situation dealing with skeletal anchorage devices. Root damage caused by miniscrews is considered a reason for failure when the screws are placed in interdental areas.^{4,5} Some patients have reported discomfort during the placement and removal of midpalatal miniscrew implants or onplants; thus, they require extensive local anesthesia and often postsurgical analgesia.^{6,7}

In cases of screw loosening or failure, the use of headgear is a potential alternative approach to implants. Cervical headgear is a commonly used appliance for treating growing patients with Class II correction.⁸⁻¹⁰ Although cervical headgear is used to modify sagittal growth, headgear traction can also be used to move the maxillary molars distally. During non-extraction treatment, the space required to relieve maxillary crowding or to correct the molar relationship can be achieved through distalization of the maxillary molars, whereas mandibular crowding is relieved by labial flaring of the incisors upon spontaneous alignment.^{11,12} Interproximal reduction of the mandibular incisors can improve alignment and leveling; however, this is limited to no more than a quarter to a half of a millimeter of enamel thickness.¹³ Proclination of the mandibular incisors after treatment in patients with Class II non-extraction may be challenging for clinicians.

In the present study, we found the immediate change of untreated mandibular dentition after the use of headgear for maxillary molar distalization. Based on this finding, the authors proposal was to investigate the immediate changes in the mandibular dentition after the use of headgear.

MATERIALS AND METHODS

This study was approved by the institutional review board of the Chonnam National University Dental Hospital, and informed consent was obtained from all subjects (CNUDH-2015-005). Subjects included 16 post-pubertal, female patients with a mean age of 18.9 ± 2.0 years who were treated by one of the authors as part of routine clinical orthodontic care from 2007 through 2014 (Table 1). All patients had a bilateral or unilateral Angle Class II molar relationship at the beginning of treatment. Exclusion criteria were as follows: (1) growing patients, (2) missing tooth or prosthetic restoration, and (3) orthodontic treatment plan that included premolar extraction.

Before starting orthodontic treatment, the patients

were unwilling to undergo the standard surgical procedure, which involved the placement of miniscrews. Therefore, after being given an alternative treatment option that required the use of headgear, they agreed to wear the headgear for 6 to 9 months to achieve molar distalization. Patients were treated using a two-step treatment protocol, i.e., maxillary molar distalization was followed by fixed appliance treatment with 0.018-inch slot brackets. The fixed appliance treatment for alignment and leveling started after sufficient molar distalization had been achieved. To prevent unwanted tooth movement, especially flaring of the maxillary incisors, the teeth were moved to the spaces created through molar distalization.

Subjects were instructed to wear the cervical headgear for 12 to 14 hours per day, mainly at night. The inner bow of the headgear was expanded 2 mm wider than the distance between the first two maxillary molar tubes, and it was positioned parallel to the occlusal plane. The inner bow was engaged 3 mm labial to the incisors to avoid contact with these teeth. To achieve maxillary molar distalization, a traction force of 14 to 16 oz (400 to 450 g) per side was applied through the headgear.¹⁴ The amount of traction force was

Table 1. Patients' demographic characteristics

Characteristic	Data
Sex, female (n)	16 (100%)
Extraction of upper second molar (n)	10 (62.5%)
No extraction of upper second molar (n)	6 (37.5%)
Age (yr)	18.9 ± 2.0
Length of headgear wearing (mo)	6.3 ± 1.2
Cephalometric measurements (°)	
SNA	79.4 ± 4.8
SNB	75.4 ± 4.7
ANB	4.0 ± 1.8
SN/GoGn	34.3 ± 4.1
FMA	28.3 ± 3.3
FMIA	58.4 ± 4.0
IMPA	92.4 ± 5.3
U1 to SN	101.4 ± 9.5

Values are presented as number or mean \pm standard deviation.

SNA, Sella-nasion-A point angle; SNB, sella-nasion-B point angle; ANB, A point-nasion-B point angle; SN/GoGn, mandibular plane angle to the anterior cranial base; FMA, mandibular plane angle to the Frankfort plane; FMIA, lower incisor angle to the Frankfort plane; IMPA, lower incisor angle to the mandibular plane; U1 to SN, upper incisor angle to the anterior cranial base.

adjusted during appointments scheduled every 4 weeks. Molar distalization was performed until a super Class I relationship was achieved.

Cone-beam computed tomography (CBCT) scans and dental casts were obtained from the patients before (T0) and immediately after (T1) maxillary molar distalization. CBCT scans were obtained using an Alphard Vega system (Asahi Roentgen Ind. Co., Ltd., Kyoto, Japan). CBCT scans were obtained with a reference ear plug (REP) and head posture aligner (HPA) to ensure standardized volume data.¹⁵ CBCT scan data were exported to InVivo 5 software (version 5.2; Anatomage, San Jose, CA, USA). The head image was reoriented to the standard position using two ball markers and a wire indicator.¹⁶

To ensure that the head position was identical in the images taken at T0 and T1, the CBCT volume data were superimposed 3-dimensionally on the anterior cranial base using InVivo software. Next, CBCT-generated half-cephalograms (CG Ceph) were generated from volume data from the right side of the CBCT scan at T0 and T1. Using the *import orientation* function of the program, we oriented two volume images in the same position. The original coordinates (0, 0, 0) were set at the center point of the line passing through the two ball markers of the REP. Cephalograms before and after molar distalization were precisely placed in the same orientation in the coordinate system. On the CG Ceph, a horizontal reference line (X line) was established parallel to the HPA. The vertical reference line (Y line) was perpendicular to the X line passing through point A

(Figure 1A).

To evaluate treatment changes after molar distalization, we obtained the following cephalometric measurements with landmarks and reference planes: the distance (mm) between the Y line to the first maxillary molar mesial cusp tip, angle (°) between the X line and the long axis of the first maxillary molar, and mandibular incisor inclination (IMPA) (Figure 1A). Maxillary molar movement was evaluated relative to an xy coordinate system set at point A.¹⁷ Dental casts at T0 and T1 were scanned using a TRIOS® scanner (3Shape, Copenhagen, Denmark). Then the casts were evaluated using a software program (OrthoAnalyzer™, 3Shape). To assess changes in the mandibular dentition between T0 and T1, we obtained the following measurements: the intercanine width (ICW), interpremolar width (IPW), and intermolar width (IMW) of the mandibular dentition. In addition, the IMW of the maxilla was evaluated (Figure 1B). Definitions of these measurements are presented in Table 2.

The sample size of this study was not calculated a priori; however, the *post hoc* power analysis according to the G*power program (version 3.1.9.2; Heinrich-Heine-University, Düsseldorf, Germany) showed more than 93% power for all the measurements.¹⁸

To assess the method errors, we repeated the measurements at an interval of 2 weeks. The method errors were calculated using the Dahlberg formula.¹⁹ Measurement errors ranged from 0.1 to 0.4 mm for the linear measurements and from 0.2° to 0.7° for the angular

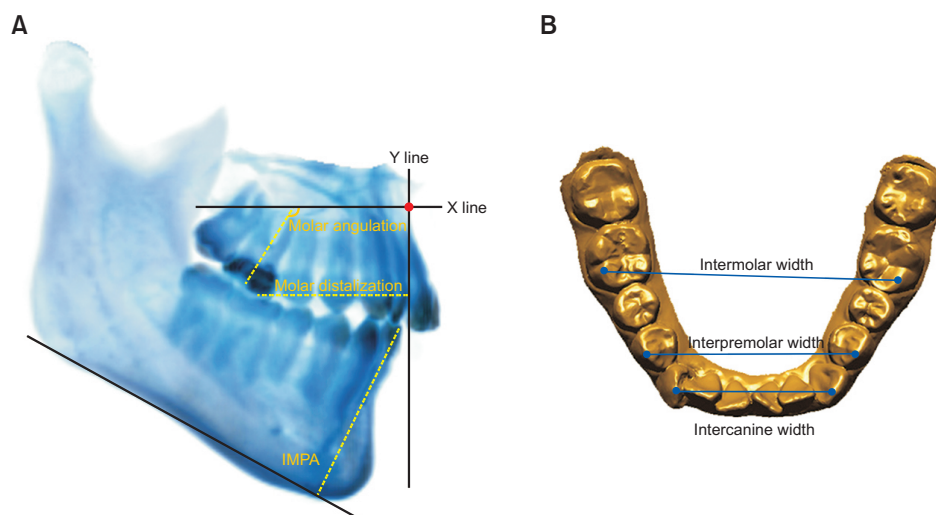


Figure 1. Measurements used in this study. **A**, Cone-beam computed tomography-generated half-cephalogram (CG Ceph) measurements for maxillary molar distalization, maxillary molar angulation, and mandibular incisor inclination (IMPA). On the CG Ceph, a horizontal reference line (X line) was established parallel to the head posture aligner after 3-dimensional superimposition of the two volume data sets. The vertical reference line (Y line) was perpendicular to the horizontal reference line (X line), which passed through A point. **B**, Model measurements for assessing the mandibular dental changes.

Table 2. Definitions of the measurements used in this study

Measurement	Definition
Model measurements	
Inter canine width	Distance between right and left canine tip
Inter premolar width	Distance between right and left first premolar buccal cusp tip
Inter molar width	Distance between right and left first molar mesiobuccal cusp tip
Cephalometric measurements	
Mx molar distalization	Distance of mesial cusp tip of maxillary molar to vertical reference plane
Mx molar angulation	Angle between tooth axis of maxillary molar and horizontal reference plane
Mx molar extrusion	Distance of mesial cusp tip of maxillary molar to horizontal reference plane
Mn incisor inclination (IMPA)	Angle between tooth axis of mandibular incisor and mandibular plane

Table 3. Immediate changes in the mandibular dentition after maxillary molar distalization

Variable	T0	T1	Change	Significance (p-value)
Mandibular model measurements				
Inter canine width (mm)	26.1 ± 2.3	26.7 ± 2.2	0.6 ± 0.2	0.000 [†]
Inter premolar width (mm)	35.3 ± 2.2	36.6 ± 2.6	1.1 ± 1.1	0.007 [†]
Inter molar width (mm)	41.1 ± 2.0	42.0 ± 2.1	0.9 ± 0.5	0.000 [†]
Cephalometric measurements				
Mx molar distalization (mm)	22.4 ± 4.4	26.5 ± 4.9	4.2 ± 1.6	0.000 [†]
Mx molar angulation (°)	74.6 ± 10.4	65.0 ± 12.9	9.7 ± 6.1	0.000 [†]
Mx molar extrusion (mm)	77.8 ± 3.3	78.5 ± 3.4	0.7 ± 1.3	0.087
Mn incisor inclination (IMPA) (°)	92.4 ± 5.3	89.6 ± 6.0	-2.8 ± 3.4	0.017*

Values are presented as mean ± standard deviation.

T0, Before treatment; T1, after maxillary molar distalization; Mx, maxilla; Mn, mandible; IMPA, lower incisor angle to the mandibular plane.

* $p < 0.05$, [†] $p < 0.01$.

measurements. The Shapiro-Wilk test showed a normal data distribution. According to the data normality, the paired *t*-test was used to evaluate treatment changes. Statistical analysis was performed using SPSS software (version 20; IBM Corp., Armonk, NY, USA).

RESULTS

The maxillary molars of each patient were distalized after a mean period of 6.3 ± 1.2 months (range, 5.0 to 8.5 months), and they moved over a mean distance of 4.2 ± 1.6 mm (range, 2.0 to 7.0 mm). The IMW of the maxilla significantly increased 1.3 mm after using headgear ($p = 0.017$). Table 3 shows changes in the mandibular dentition at T0 and T1 using headgear. The ICW, IPW, and IMW of the mandibular dentition significantly increased, whereas the IMPA decreased (Table 3).

DISCUSSION

In the present study, significant changes in the mandibular dentition occurred spontaneously in response to the traction force applied by the headgear. After maxillary molar distalization, the arch widths of the mandible increased. Kirjavainen et al.²⁰ evaluated the effects of treatment using cervical headgear in children in the mixed dentition stage who had Class II malocclusion. During the 2-year treatment period, widening of the maxilla was followed by spontaneous widening of the mandible.²⁰ In our study, the mean treatment period was 6.3 months, and subjects' mean age was 18.9 years. Therefore, widening of the ICW and IMW of the mandible could not be attributed to age-related growth.

A possible reason for the immediate changes in the mandibular dentition may be explained by the equilibrium theory.²¹ Alterations in the oral environment related to distalization and extrusion of the maxillary

molar may be contributing factors. As the position of the tongue changed, the pressure from the tongue may have led to changes in the mandibular dentition owing to the altered equilibrium. In a study that evaluated the treatment effects of rapid palatal expansion (RPE), the authors observed spontaneous mandibular posterior widening.²² This finding indicates that occlusion during banded RPE enables the maxillary posterior teeth to drag the mandibular arch buccally as expansion occurs.²² In our study, the maxillary arch width increased by expanding the inner bow and performing distalization. Posterior occlusion is almost established in young adults; thus, the mandible may follow maxillary posterior occlusion through occlusal intercuspation. The widening of the mandibular arch widths might be explained by this reason. Mandibular widening after headgear may contribute to relieving mandibular incisor crowding. Regarding immediate changes in the mandibular dentition after maxillary molar distalization, non-extraction treatment with headgear and the two-step protocol may be another option for young adult, female patients who are concerned about the disadvantages or discomfort of skeletal anchorage devices.

CONCLUSION

1. Maxillary molar distalization induced a spontaneous response in the untreated mandibular dentition in non-growing patients.
2. The ICW, IPW, and IMW of the mandible increased after maxillary molar distalization.

REFERENCES

1. Bae SM, Park HS, Kyung HM, Kwon OW, Sung JH. Clinical application of micro-implant anchorage. *J Clin Orthod* 2002;36:298-302.
2. Nishimura M, Sannohe M, Nagasaka H, Igarashi K, Sugawara J. Nonextraction treatment with temporary skeletal anchorage devices to correct a Class II Division 2 malocclusion with excessive gingival display. *Am J Orthod Dentofacial Orthop* 2014;145:85-94.
3. Kook YA, Bayome M, Trang VT, Kim HJ, Park JH, Kim KB, et al. Treatment effects of a modified palatal anchorage plate for distalization evaluated with cone-beam computed tomography. *Am J Orthod Dentofacial Orthop* 2014;146:47-54.
4. Kuroda S, Yamada K, Deguchi T, Hashimoto T, Kyung HM, Takano-Yamamoto T. Root proximity is a major factor for screw failure in orthodontic anchorage. *Am J Orthod Dentofacial Orthop* 2007;131(4 Suppl):S68-73.
5. Miyazawa K, Kawaguchi M, Tabuchi M, Goto S. Accurate pre-surgical determination for self-drilling miniscrew implant placement using surgical guides and cone-beam computed tomography. *Eur J Orthod* 2010;32:735-40.
6. Feldmann I, List T, Feldmann H, Bondemark L. Pain intensity and discomfort following surgical placement of orthodontic anchoring units and premolar extraction: a randomized controlled trial. *Angle Orthod* 2007;77:578-85.
7. Garfinkle JS, Cunningham LL Jr, Beeman CS, Kluemper GT, Hicks EP, Kim MO. Evaluation of orthodontic mini-implant anchorage in premolar extraction therapy in adolescents. *Am J Orthod Dentofacial Orthop* 2008;133:642-53.
8. Cangialosi TJ, Meistrell ME Jr, Leung MA, Ko JY. A cephalometric appraisal of edgewise Class II nonextraction treatment with extraoral force. *Am J Orthod Dentofacial Orthop* 1988;93:315-24.
9. Mossaz CF, Byloff FK, Kiliaridis S. Cervical headgear vs pendulum appliance for the treatment of moderate skeletal Class II malocclusion. *Am J Orthod Dentofacial Orthop* 2007;132:616-23.
10. Freitas MR, Lima DV, Freitas KM, Janson G, Henriques JF. Cephalometric evaluation of Class II malocclusion treatment with cervical headgear and mandibular fixed appliances. *Eur J Orthod* 2008;30:477-82.
11. Sfondrini MF, Cacciafesta V, Sfondrini G. Upper molar distalization: a critical analysis. *Orthod Craniofac Res* 2002;5:114-26.
12. Proffit WP, Fields HW, Sarver DM. Orthodontic treatment planning: from problem list to specific plan. In: Proffit WP, Fields HW, Sarver DM, eds. *Contemporary orthodontics*. 5th ed. St. Louis: Elsevier-Mosby; 2013. p. 220-77.
13. Proffit WP. Retention. In: Proffit WP, Fields HW, Sarver DM, eds. *Contemporary orthodontics*. 5th ed. St. Louis: Elsevier-Mosby; 2013. p. 606-22.
14. Fields HW, Proffit WP. Treatment of skeletal problems in children and preadolescents. In: Proffit WP, Fields HW, Sarver DM, eds. *Contemporary orthodontics*. 5th ed. St. Louis: Elsevier-Mosby; 2013. p. 472-528.
15. Hwang HS, Lee KM, Uhm GS, Cho JH, McNamara JA Jr. Use of Reference Ear Plug to improve accuracy of lateral cephalograms generated from cone-beam computed tomography scans. *Korean J Orthod* 2013;43:54-61.
16. Lee KM, Lee WJ, Cho JH, Hwang HS. Three-dimensional prediction of the nose for facial reconstruction using cone-beam computed tomography. *Forensic Sci Int* 2014;236:194.e1-5.
17. Cha BK, Ngan PW. Skeletal anchorage for orthopedic correction of growing class III patients. *Semin*

- Orthod 2011;17:124-37.
18. Faul F, Erdfelder E, Lang AG, Buchner A. G*Power 3: a flexible statistical power analysis program for the social, behavioral, and biomedical sciences. *Behav Res Methods* 2007;39:175-91.
19. Dahlberg G. Statistical methods for medical and biological students. London: George Allen & Unwin Ltd; 1940. p. 122-32.
20. Kirjavainen M, Kirjavainen T, Haavikko K. Changes in dental arch dimensions by use of an orthopedic cervical headgear in Class II correction. *Am J Orthod Dentofacial Orthop* 1997;111:59-66.
21. Proffit WP. The etiology of orthodontic problems. In: Proffit WP, Fields HW, Sarver DM, eds. *Contemporary orthodontics*. 5th ed. St. Louis: Elsevier-Mosby; 2013. p. 114-49.
22. Miller CL, Araújo EA, Behrents RG, Oliver DG, Tanaka OM. Mandibular arch dimensions following bonded and banded rapid maxillary expansion. *J WFO* 2014;3:119-23.