

A Case of Retinal Detachment in Colobomatous Macrophthalmos With Microcornea Syndrome

Hyun Kyung Seung, MD¹, Ha Kyoung Kim, MD², Woo Ho Nam, MD²

¹Hanil General Hospital, Seoul, Korea

²Department of Ophthalmology, Kangnam Sacred Heart Hospital, Hallym University College of Medicine, Seoul, Korea

We report a rare case of retinal detachment in colobomatous macrophthalmos with microcornea syndrome. A 25-year-old female who had suffered from poor vision in her left eye since early childhood and high myopia in her right eye (-11 D) visited our clinic because of a sudden deterioration of vision. Examination of the anterior segment showed microcornea with coloboma of the inferior pupil margin in the left iris. Fundus examination of the left eye revealed an inferior choroidal coloboma extending from the optic disc and macula. The patient also had total bullous retinal detachment. Pars plana vitrectomy with silicone oil tamponade was performed, and the retina was reattached. In the very rare condition of colobomatous macrophthalmos with microcornea, retinal detachment may develop. Pars plana vitrectomy with additional silicone oil tamponade may be performed to treat this condition.

Korean J Ophthalmol 2009;23:312-314 © 2009 by the Korean Ophthalmological Society.

Key Words: Colobomatous macrophthalmia, Microcornea, Retinal detachment

Colobomatous macrophthalmia with microcornea syndrome is a very rare eye malformation characterized by microcornea, uveal coloboma, axial enlargement of the globe, and myopia.¹ Other associated findings are mild cornea plana, iridocorneal angle abnormalities with increased intraocular pressure, and relatively shallow anterior chamber depth.²

Coloboma of the choroid is a congenital defect caused by faulty closure of the embryonic fissure, reported to occur in 0.14% of the general population. Forty percent of affected individuals may develop retinal detachment sometime during their life.³

We describe a case of colobomatous macrophthalmia with microcornea syndrome who developed retinal detachment. To our knowledge, this is the first documented case of retinal detachment associated with colobomatous macrophthalmia and microcornea syndrome that was treated with pars plana vitrectomy and silicone oil tamponade.

Case Report

A 25-year-old woman with poor vision in her left eye since early childhood and high myopia in her right eye (refractive error; -11 D) presented with a history of sudden deterioration of vision in her left eye for two days. Her medical and family histories were unremarkable.

Full ocular examination was performed. The best cor-

rective visual acuity of her right eye was 20/20 with correction of -11 D, while that of her left eye was hand motion with correction of -19.75 D. Intraocular pressure was 15 mmHg in the right eye and 17 mmHg in the left eye. Slit lamp examination showed clear corneas in both eyes, with diameters of 13.5 mm in the right eye and 10 mm in the left eye. The left eye also had a coloboma of the iris, which manifested as a small notch in the inferonasal pupillary margin (Fig. 1) and shallow chamber depth. Keratometry and A-scan ultrasonography were performed. Upon A-scan ultrasonography, axial length was 28.16 mm in the right eye and 29.65 mm in the left eye. Anterior chamber depth was 3.75 mm in the right eye and 2.34 mm in the left eye. Upon keratometry, correction was 43.38 D in the right eye and 40.0 D in the left eye. Fundus examination of the right eye showed a myopic tigroid fundus with tilted disc and peripapillary atrophy. Fundus examination of the left eye showed an inferior choroidal coloboma for about six disc areas, extending to the optic disc, macula and above the temporal arcade. Total bullous detachment of the retina was also observed, including detachment of the macula and the other areas of the retina. Findings suspicious for retinal break were visible in the inferotemporal margin of the choroidal coloboma (Fig. 2).

The patient subsequently underwent repair of the retinal detachment. Standard three-port of the pars plana vitrectomy was initially performed with sclerotomy sites 2.5 mm posterior to the limbus. By using the operating microscope, fluid-air exchange was performed with a tapered needle placed over the ectatic abnormality of the colobomatous zone. A retinal break was noted due to the subretinal viscous fluid passing through the break. The retina was gradually

Received: August 14, 2008 Accepted: October 23, 2009

Reprint requests to Ha Kyoung Kim, MD, Department of Ophthalmology, Kangnam Sacred Heart Hospital, Hallym University College of Medicine, #948-1 Daerim 1-dong, Yeongdeungpo-gu, Seoul 150-950, Korea. Tel: 82-2-829-5193, Fax: 82-2-848-4638, E-mail: ophkim@hallym.or.kr

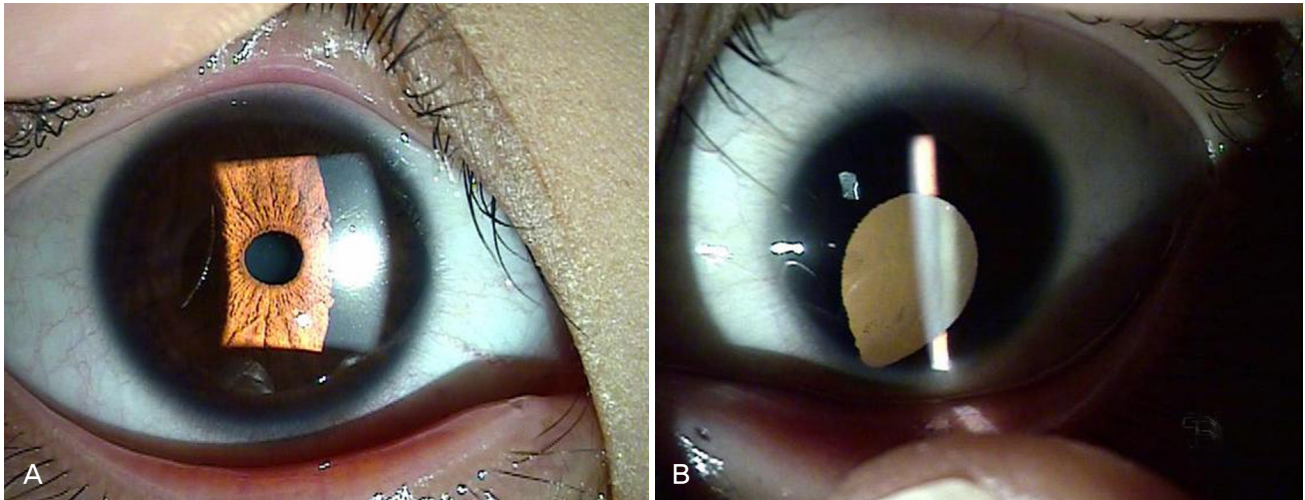


Fig. 1. Slit-lamp examination. (A) Right eye with normal cornea and iris. (B) Left eye with microcornea (10 mm), shallow anterior chamber, and iris coloboma in the inferonasal pupillary margin.

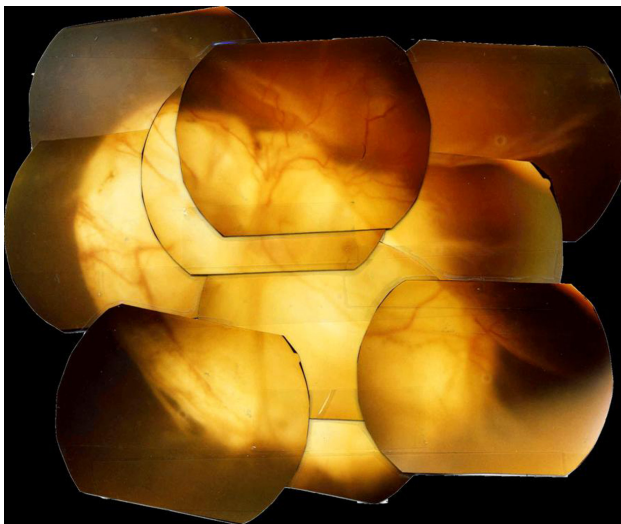


Fig. 2. Fundus photography of the left eye shows inferior choroidal coloboma extending to the optic disc and macula, as well as bullous retinal detachment.

flattened by evacuating subretinal fluid through the retinal break. An endolaser was applied over the flattened retina around the colobomatous area by diode laser. To achieve internal tamponade, 5,000-centistoke silicone oil was then injected into the vitreous cavity. The patient was encouraged to maintain a face-down position for two weeks.

At a six-month follow-up period, the patient had visual acuity of hand motion, and the retina remained attached.

Discussion

Colobomata of the uvea are frequently associated with microphthalmos and/or microcornea. But without measuring axial length, determining whether eyes with microcornea are truly microphthalmic is difficult. Hornby et al.⁴ reported that

only half of the eyes with the diagnosis of coloboma and microcornea are truly microphthalmic. The term colobomatous macrophthalmia with microcornea syndrome was proposed to describe the phenotype characterized by microcornea (greatest diameter ≤ 10 mm), uveal coloboma (involving the iris, choroid, retina, and/or optic nerve head), axial enlargement of the globe, and myopia.¹ Microcornea often accompanies anterior microphthalmos, with crowding of the anterior segment structures. In this case, anterior chamber depth was 3.75 mm in the right eye and 2.34 mm in the left eye. Thus, the sclerotomy site were selected 2.5 mm posterior to the limbus and proved to be safe in the preservation of the lens without performing pars plana lensectomy during the whole procedure.

Retinal detachment can occur in eyes with choroidal coloboma because of a retinal break-out beside the colobomatous area at the margin of the coloboma or over the coloboma. Retinal detachments and coloboma of the fundus could have the same etiology or could be coincidental occurrences. Several techniques have been described to treat these detachments. Patnaik and Kalsi reported success in a case in which they buckled the entire coloboma.⁵ However, external buckling is difficult and is only rarely successful because of the difficulty in identifying the breaks in the intercalary membrane, the impossibility of creating chorioretinal adhesion around the breaks due to the absence of the choroid and the retinal pigmentary epithelium, and the posterior location of these breaks.

Pars plana vitrectomy has enabled the identification of the breaks in the intercalary membrane with more certainty and higher success rates.⁶ Given that, in most cases, direct closure of the break may not be possible and that the efficacy of retinal reattachment of choroidal coloboma is low, retinopexy around the coloboma margin by diode laser and internal tamponade are necessary to allow the treated area to develop adhesion.

Gas,⁷ silicone oil,⁶ and perfluoroperhydrophenanthrene⁸ have been used as internal tamponading agents. Silicone oil is considered to be the best agent that can tamponade the entire colobomatous border for a long enough time. Posterior vitreous detachment was absent in 59.5% of retinal detachments related to coloboma of the choroids,⁹ and it was considered important to separate the posterior vitreous from the retina to reduce the possibility of post-operative vitreous traction leading to recurrent detachment. Complete vitrectomy with a method to create chorioretinal adhesion around the coloboma and silicone oil tamponading provides an effective treatment for this complicated type of retinal detachment, with good long-term anatomical and visual outcomes.⁹

To our knowledge, retinal detachment in patients with colobomatous macrophthalmia with microcornea syndrome and its treatment with pars plana vitrectomy has not been documented.

References

1. Bateman JB, Maumenee IH. Colobomatous macrophthalmia with microcornea. *Ophthalmic Paediatr Genet* 1984;4:59-66.
2. Toker E, Elcioglu N, Ozcan E, et al. Colobomatous macrophthalmia with microcornea syndrome: report of a new pedigree. *Am J Med Genet A* 2003;121A:25-30.
3. Jesberg DO, Schepens CL. Retinal detachment associated with coloboma of the choroid. *Arch Ophthalmol* 1961;65:163-73.
4. Hornby SJ, Adolph S, Gilbert CE, et al. Visual acuity in children with coloboma: clinical features and a new phenotypic classification. *Ophthalmology* 2000;107:511-20.
5. Michels RG, Wilkinson CP, Rice TA. *Retinal Detachment*. St Louis: Mosby, 1990;724-8.
6. Gopal L, Kini MM, Badrinath SS, Sharma T. Management of retinal detachment with choroidal coloboma. *Ophthalmology* 1991;98:1622-7.
7. Jalali S, Das T. Selection of surgical technique for retinal detachment with coloboma of the choroid. *Indian J Ophthalmol* 1994;42:27-30.
8. Lee KJ, Peyman GA, Paris CL, et al. Management of retinal detachment associated with choroidal coloboma using perfluoroperhydrophenanthrene (Vitreon). *Ophthalmic Surg* 1992;23:553-4.
9. Pal N, Azard RV, Sharma YR. Long-term anatomical and visual outcome of vitreous surgery for retinal detachment with choroidal coloboma. *Indian J Ophthalmol* 2006;54:85-8.