

Photodynamic Therapy With Verteporfin for Choroidal Neovascularization in Patients with Angioid Streaks

Jun Mok Lee, MD, Woo Ho Nam, MD, Ha Kyoung Kim, MD

Department of Ophthalmology, Kangnam Sacred Heart Hospital, College of Medicine, Hallym University, Seoul, Korea

Purpose: To evaluate the functional and anatomic outcomes of photodynamic therapy (PDT) for choroidal neovascularization (CNV) in patients with angioid streaks.

Methods: The authors retrospectively evaluated 6 consecutive patients (6 eyes) with CNV secondary to angioid streaks. All patients were treated with standard PDT with verteporfin protocol. Standardized protocol refraction, visual acuity testing, ophthalmologic examination, color photographs, fluorescein angiograms and indocyanin angiograms were used to evaluate the results of PDT with verteporfin. Main outcome measures were visual acuity and CNV size.

Results: Their mean age was 61.3 ± 5.50 years (range, 53-68 years). Follow-up time ranged from 12 to 38 months with mean of 20.5 ± 10.91 months. The mean visual acuity at baseline was 20/100 (range 20/25-20/500), and the mean visual acuity at the last examination was 20/320 (range 20/125-counting finger). The mean greatest linear dimension (GLD) at baseline was 2400 ± 766.81 μm , and the mean GLD at the last examination was 3483 ± 444.59 μm .

Conclusions: PDT for CNV associated with angioid streaks seemed to slow down but not prevent the progression of the disease and associated visual loss.

Korean Journal of Ophthalmology 21(3):142-145, 2007

Key Words: Angioid streak, Photodynamic therapy, Subfoveal choroidal neovascularization

Angioid streaks represent dehiscences in Bruch's membrane and are associated with various systemic diseases such as pseudoxanthoma elasticum, Ehler-Danlos syndrome, Paget disease, and various blood dyscrasias.¹ Choroidal neovascularization (CNV) is the major cause of vision loss associated with angioid streaks. Although data on the natural history of CNV associated with angioid streaks is poor, historical surveys report that CNV occurs in 70% to 86% of patients during follow-up, with most eyes progressing to legal blindness.^{2,3} Although conventional laser photocoagulation for juxtafoveal and extrafoveal choroidal neovascularization secondary to angioid streaks may mitigate the rate of visual loss, treatment modalities for subfoveal neovascularization remain limited.⁴⁻⁶ Recently, photodynamic therapy (PDT) with verteporfin has been introduced as a treatment for

reducing visual loss in patients with CNV due to age-related macular degeneration, pathologic myopia.^{7,8} Unlike conventional laser photocoagulation, PDT can close CNV with minimal or no detectable damage to the surrounding tissues. Therefore, it allows the clinician to treat subfoveal CNV without immediately adversely affecting central visual function. The purpose of this study was to determine the functional and anatomic results of PDT in patients with subfoveal CNV related to angioid streaks.

Materials and Methods

A retrospective analysis of 6 eyes of 6 patients diagnosed with subfoveal choroidal neovascularization associated with angioid streaks and treated by the authors from October 2003 through december 2006 was conducted. The diagnosis of angioid streaks was based on the typical clinical and angiographic appearance of bilateral broad, irregular, reddish brown or gray lines that radiate from the area around the optic nerve head. Patients with fundus abnormalities associated with other ocular diseases that can cause CNV, such as age-related drusen, were not included in the study. All patients underwent color photography, fluorescein and indocyanine green angiography, and complete ocular examinations with determination of best-corrected visual

Received: January 12, 2007 Accepted: June 25, 2007

Reprint requests to Ha Kyoung Kim, MD. Department of Ophthalmology, Kangnam Sacred Heart Hospital, College of Medicine, Hallym University. 948-1 Daerim-dong, Youngdeungpo-gu, Seoul, 150-950, Korea. Tel: 82-2-829-5193, Fax: 82-2-848-4638, E-mail: hkkimeye@unitel.co.kr

* This study was presented as a poster at the Korean Ophthalmological Society 96th Autumn Meeting, November 2006, Ilsan, Korea

acuity both before treatment and at all subsequent follow-up visits. Main outcome measures were visual acuity and CNV size. Visual acuity was measured using an Early Treatment of Diabetic Retinopathy Study chart and was approximated to the nearest Snellen equivalent. The greatest linear dimension (GLD) was measured including all lesion components. Photodynamic therapy was administered using the same procedure as in the Treatment of Age-related Macular Degeneration with Photodynamic Therapy (TAP) and Verteporfin in Photodynamic Therapy (VIP) studies.^{7,8} Verteporfin (Visudyne; Novartis Ophthalmic AG, Hettlinger Switzerland) is reconstituted with sterile water and diluted with 5% dextrose to achieve a drug dose of 6 mg/m² body surface area (BSA) and a total infusion volume of 30 ml. The solution is infused intravenously at a rate of 3 ml/min over 10 minutes. Laser (Coherent, Palo Alto, California, USA) application is carried out at 15 minutes after the start of the infusion. The spot size is determined by measuring the greatest linear dimension of the entire lesion and an additional 1000 µm is added to this value. The time to deliver 50 J/cm² laser dose is 83 seconds. The patients were instructed to avoid direct sunlight or bright indoor light for 48 h after treatment. Retreatments were considered when active leakage was observed at 3 month intervals.

Results

Three patients were men and three patients were women. Their mean age was 61.3±5.50 years (range, 53-68 years.) In four cases the right eye was affected and in two cases, the left eye. Follow-up time ranged from 12 to 38 months with mean of 20.5±10.91 months. Four patients were treated twice and two patients were treated once (Table 1). The mean visual acuity at baseline was 20/100 (range 20/25-20/500), and the mean visual acuity at the last examination was 20/320 (range 20/125-counting finger). Visual acuity of counting fingers was assigned a value of 20/2000. The mean GLD at baseline was 2400±766.81 µm, and the mean GLD at the last examination was 3483±444.59 µm. The mean line change was -4.0 lines (ETDRS charts). One patient improved visual acuity. No unexpected ocular or systemic adverse events were noted in either patient group.

Discussion

The natural prognosis of CNV in angioid streaks has been reported to be unfavorable insofar as most eyes become legally blind by 1 years.¹⁻³ Different therapeutic approaches have been used in the attempt to treat this vision-threatening disease. Laser photocoagulation has not yielded good results.^{4,6} This treatment was indicated in non-subfoveal lesions, but frequently the centre of the fovea was finally affected due to relapse of the initial lesion or enlargement of the laser scar.

PDT with verteporfin can reduce vision loss in the more common type of CNV, such as age-related macular degeneration and pathologic myopia.^{7,8} Thus, PDT with verteporfin has been tested in the treatment of CNV secondary to angioid streaks. The first published case reports and series of PDT in patients with angioid streaks seemed to be particularly promising. Sickenberg et al.⁹ documented no visual loss in a 52-year-old male patient with 3-month follow-up. Karacorlu et al.¹⁰ described eight cases with subfoveal CNV and a mean follow-up of 8 months. The results were quite good, with stabilization or improvement of visual acuity in all cases. In contrast to these reports, recently published series report somewhat less encouraging results of PDT for CNV associated with angioid streaks.¹²⁻¹⁶ Shaikh et al.¹² described an increased in lesion size in seven out of nine CNV treated with multiple sessions. In the largest series published to date, Menchini et al.¹¹ combined the results of 48 eyes out of six centers in Italy. With a minimum follow-up of 12 months, they found a decrease in visual acuity in 32% of patients with subfoveal lesions and in 50% in patients with extra- or juxtafoveal CNV. Overall, 18% had a visual acuity <20/200 at the final examination, and a 62% the lesion size determined by GLD measurements increased comparing baseline to final examination. Browning et al.¹³ described that PDT might limit the visual loss in the majority of patients through the first 12 months of follow-up.

In our study, treated CNV initially displayed a stabilization of visual acuity (defined as visual loss<3 lines) following PDT. Stabilization of visual acuity was achieved in four patients through the 12 months of follow-up. Visual improvement was obtained in one patient. The mean line

Table 1. Patient characteristics and course of therapy after PDT in 6 patients with CNV associated with angioid streaks

Case	Age	Sex	Eye	F/U	Baseline VA	Final VA	1 years VA	Baseline GLD*	Final GLD*	No. of PDT
1	66	M	OD	12 Mon	20/100	20/125	20/125	3200	3700	2
2	58	F	OD	12 Mon	20/500	20/200	20/200	2500	2900	2
3	63	F	OD	14 Mon	20/25	20/100	20/125	1600	3000	1
4	53	F	OS	30 Mon	20/125	C. F [†]	20/160	3400	4000	2
5	60	M	OS	17 Mon	20/125	20/800	20/500	2000	3500	1
6	68	F	OD	38 Mon	20/100	C. F [†]	C. F [†]	1700	3800	2

GLD* : greatest linear dimension.

C. F[†]: counting finger.

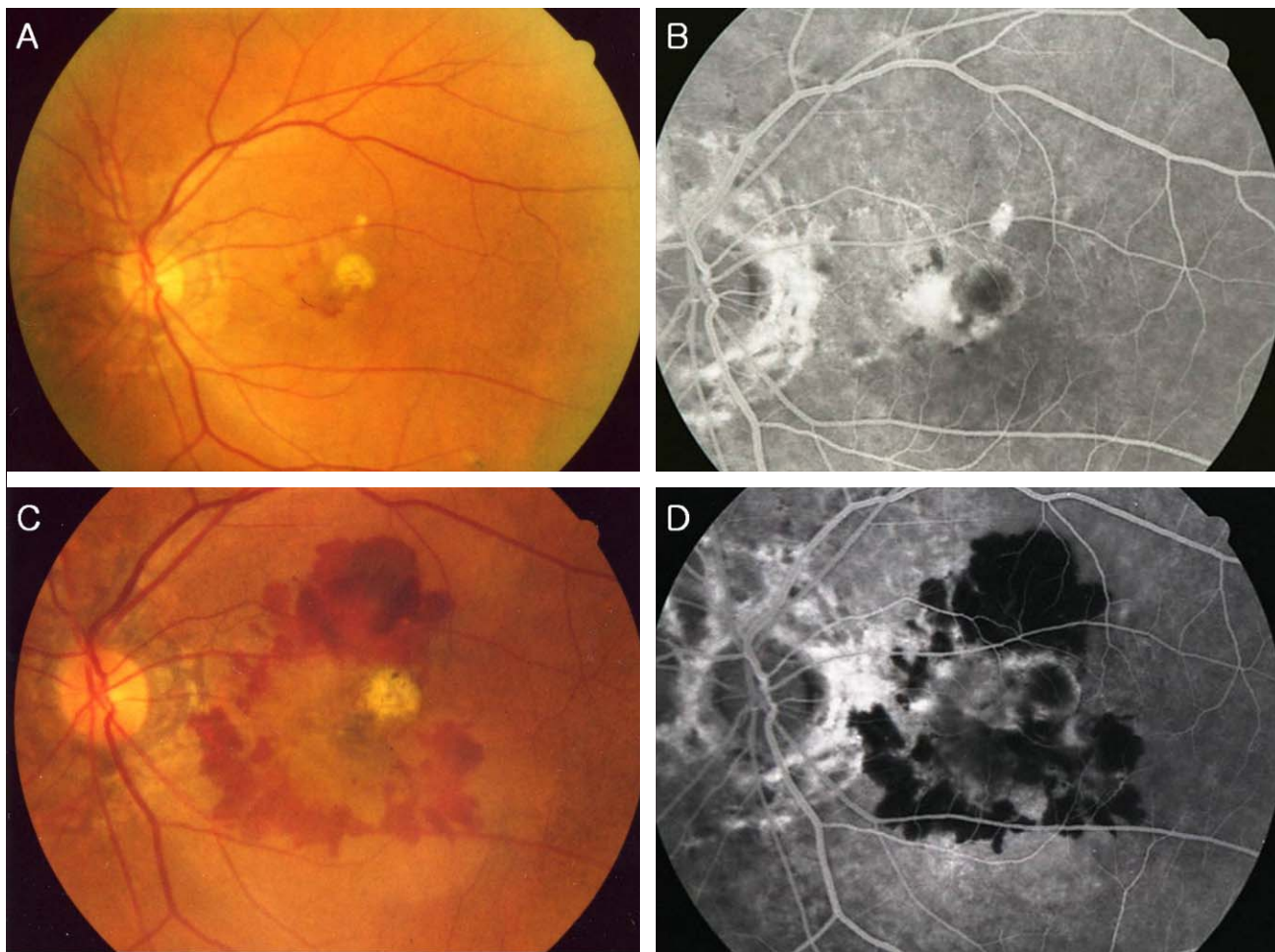


Fig. 1. Case 5 : Pretreatment fundus photography (A) and fluorescein angiogram (B) reveals subfoveal choroidal neovascular membrane associated with hemorrhage. Posttreatment fundus photography (C) and fluorescein angiogram (D) at 9 months reveal marked enlargement, increased leakage, and disciform conversion of the neovascular complex

change was -4.1 lines (ETDRS charts). Changes in GLD had a tendency to enlarge despite receiving PDT (Figure 1). The mean GLD at baseline was $2400 \pm 766.81 \mu\text{m}$, and the mean GLD at the last examination was $3483 \pm 444.59 \mu\text{m}$. In our experience PDT with verteporfin does not seem to be a good treatment to stabilize visual acuity and lesion size in CNV secondary to angioid streaks. However, compared to the aggressive natural course and to the limited treatment options, PDT may at least in part help to stabilize macular function over a limited period of time. We think that PDT should be considered in selected cases until better therapeutic modalities become available. In the future, modifications of the PDT treatment may have the potential to further improve the visual outcome in this population. As the combination of PDT with intravitreal triamcinolone acetonide showed promising results in a group of patients that did initially not show a good response to PDT treatment,¹⁷ and combinations of PDT with anti-angiogenic substances are currently investigated in clinical studies.¹⁸ We think that these combinations merit further investigation and might possibly enhance the results

of the PDT treatment of patients with CNV and angioid streaks.

References

1. Mansour AM, Shields JA, Annesley WH Jr, et al. Macular degeneration in angioid streaks. *Ophthalmologica* 1988;197: 36-41.
2. Clarkson JG, Altman RD. Angioid streaks. *Surv Ophthalmol* 1982;26:235-46.
3. Singerman LJ, Hatem G. Laser treatment of choroidal neovascular membranes in angioid streaks. *Retina* 1981;1:75-83.
4. Lim JI, Bressler NM, Marsh MJ, Bressler SB. Laser treatment of choroidal neovascularization in patients with angioid streaks. *Am J Ophthalmol* 1993;116:414-23.
5. Pece A, Avanza P, Galli L, Brancato R. Laser photocoagulation of choroidal neovascularization in angioid streaks. *Retina* 1997;17:12-6.
6. Gelissen O, Hendrikse F, Deutman AF. A long-term follow-up study of laser coagulation of neovascular membranes in angioid streaks. *Am J Ophthalmol* 1988;105:299-303.
7. Treatment of Age-Related Macular Degeneration with

- Photodynamic Therapy (TAP) Study Group. Photodynamic therapy of subfoveal choroidal neovascularization in age-related macular degeneration with verteporfin: one-year results of 2 randomized clinical trials-TAP report. *Arch Ophthalmol* 1999;117:1329-45.
8. Verteporfin in Photodynamic Therapy Study Group. Photodynamic therapy of subfoveal choroidal neovascularization in pathologic myopia with verteporfin: 1-year results of a randomized clinical trial-VIP report no. 1. *Ophthalmology* 2001;108:841-52.
 9. Sickenberg M, Schmidt-Erfurth U, Miller JW, et al. A preliminary study of photodynamic therapy using verteporfin for choroidal neovascularization in pathologic myopia, ocular histoplasmosis syndrome, angioid streaks, and idiopathic causes. *Arch Ophthalmol* 2000;118:327-36.
 10. Karacorlu M, Karacorlu S, Ozdemir H et al. Photodynamic therapy with verteporfin for choroidal neovascularization in patients with angioid streaks. *Am J Ophthalmol* 2002;134:360-6.
 11. Menchini U, Virgili G, Introini U et al. Outcome of choroidal neovascularization in angioid streaks after photodynamic therapy. *Retina* 2004;24:763-71.
 12. Shaikh S, Ruby AJ, Williams GA. Photodynamic therapy using verteporfin for choroidal neovascularization in angioid streaks. *Am J Ophthalmol* 2003;135:1-6.
 13. Browning AC, Chung AK, Ghanchi F et al. Verteporfin photodynamic therapy of choroidal neovascularization in angioid streaks. *Ophthalmology* 2005;112:1227-31.
 14. Heimann H, Gelissen F, Wachtlin J, et al. Photodynamic therapy with verteporfin for choroidal neovascularization associated with angioid streaks. *Graefes Arch Clin Exp Ophthalmol* 2005;243:1115-23.
 15. Arias L, Pujol O, Rubio M et al. Long-term results of photodynamic therapy for the treatment of choroidal neovascularization secondary to angioid streaks. *Graefes Arch Clin Exp Ophthalmol* 2006;244:753-7.
 16. Jurkles B, Bornfeld N, Schilling H. Photodynamic therapy using verteporfin for choroidal neovascularization associated with angioid streaks-long-term effects. *Ophthalmic Res* 2006;38:209-17.
 17. Spaide RF, Sorenson J, Maranan L. Combined photodynamic therapy with verteporfin and intravitreal triamcinolone acetonide for choroidal neovascularization. *Ophthalmology* 2003;110:1517-25.
 18. Eyetech Study Group. Anti-vascular endothelial growth factor therapy for subfoveal choroidal neovascularization secondary to age-related macular degeneration: phase II study results. *Ophthalmology* 2003;110:979-86.