

Surgical Outcomes of Canalicular Trephination Combined with Endoscopic Dacryocystorhinostomy in Patients with Distal or Common Canalicular Obstruction

Yoon Jin Kong¹, Hye Sun Choi², Jae Woo Jang², Sung Joo Kim², Sun Young Jang¹

¹Department of Ophthalmology, Soonchunhyang University Bucheon Hospital, Soonchunhyang University College of Medicine, Bucheon, Korea

²Department of Ophthalmology, Kim's Eye Hospital, Konyang University College of Medicine, Seoul, Korea

Purpose: This study investigated the surgical outcomes of canalicular trephination combined with endoscopic dacryocystorhinostomy (DCR) in patients with a distal or common canalicular obstruction. It also identified the factors affecting surgical success rates associated with this technique.

Methods: We retrospectively reviewed the medical records of 57 patients (59 eyes) in whom a canalicular obstruction was encountered during endoscopic DCR. All patients were treated with endoscopic DCR, followed by canalicular trephination and silicone tube placement. The surgical outcome was categorized as a functional success according to the patient's subjective assessment of symptoms, including epiphora, and as an anatomical success according to a postoperative nasolacrimal duct irrigation test. Surgical success rates were compared based on age, sex, location of the obstruction, number of silicone tubes, and experience of the surgeon.

Results: Functional success was achieved in 55 of 59 eyes (93%) at one month, 50 eyes (84%) at three months, and 46 eyes (78%) at six months. Anatomical success was achieved in 58 of 59 eyes (98%) at one month, 52 eyes (88%) at three months, and 50 eyes (84%) at six months. There was a statistically significant difference in surgical outcome according to the experience of the surgeon. The anatomical success rate at the six-month follow-up exam was 95.4% in the >5 years of experience group, and 53.3% in the <5 years of experience group ($p = 0.008$, Pearson chi-square test).

Conclusions: The success rate of canalicular trephination combined with endoscopic DCR in patients with a distal or common canalicular obstruction decreased gradually during the six-month follow-up period. In particular, patients undergoing procedures with experienced surgeons tended to show excellent surgical outcomes at the six-month follow-up exam.

Key Words: Dacryocystorhinostomy, Lacrimal apparatus disease, Trephining

Received: February 27, 2015 Accepted: June 10, 2015

Corresponding Author: Sun Young Jang, MD. Department of Ophthalmology, Soonchunhyang University Bucheon Hospital, #170 Jomaru-ro, Wonmi-gu, Bucheon 14584, Korea. Tel: 82-32-621-6718, Fax: 82-32-621-5018, E-mail: ysyat01@naver.com

Canalicular obstructions may be one of the most difficult lacrimal conditions to treat [1]. Because the treatment of this condition depends on the severity of the obstruction, several preoperative examinations, including lacrimal probing and dacryocystogram (DCG), are typically performed in patients presenting with epiphora. Despite such

© 2015 The Korean Ophthalmological Society

This is an Open Access article distributed under the terms of the Creative Commons Attribution Non-Commercial License (<http://creativecommons.org/licenses/by-nc/3.0/>) which permits unrestricted non-commercial use, distribution, and reproduction in any medium, provided the original work is properly cited.

preoperative examinations, distal or common canalicular obstructions are often encountered during endoscopic dacryocystorhinostomy (DCR), which makes surgery much more difficult. Furthermore, the stability of the canaliculus is considered to be clinically important because a canalicular obstruction or stenosis is a risk factor for surgical failure following DCR [2,3]. Lacrimal probing and a DCG can help identify a proximal canalicular obstruction; however, they are limited in their ability to confirm the presence of distal or common canalicular obstructions.

Distal and common canalicular obstructions can be treated with canaliculoplasty with lacrimal trephination [4], internal membranectomy [5], or laser-assisted DCR [6]. Although it is well documented that a canalicular obstruction is a risk factor for failed DCR surgery [2,3], the outcomes of canaliculoplasties performed to treat distal or common canalicular obstructions remain largely uninvestigated.

Thus, in this study, we investigated the surgical outcomes of canalicular trephination combined with endoscopic DCR in patients with distal or common canalicular obstructions and sought to identify the factors affecting surgical success rates.

Materials and Methods

We retrospectively reviewed the medical records of 57 patients (59 eyes) who were diagnosed with a distal or common canalicular obstruction while undergoing endoscopic DCR for the treatment of a primary nasolacrimal duct obstruction between February 2001 and December 2011. In all subjects, preoperative lacrimal irrigation was 'not passing,' allowing us to rule out functional nasolacrimal duct obstruction. On DCG, a distal or common canalicular obstruction was suspected in 28 eyes (47.4%). Among them, preoperative probing was performed in 20 eyes (33.8%). A soft stop was observed in eight eyes (13.5%), and a hard stop was observed in 12 eyes (20.3%). Despite performing preoperative DCG and probing, distal or common canalicular obstruction can still be encountered intraoperatively. Thus, the diagnosis of distal or common canalicular obstruction was confirmed intraoperatively, and canalicular trephination and silicone tube placement were combined with endoscopic DCR.

Conventional endoscopic DCR was performed under

general anesthesia in all patients. We briefly introduced a 20 or 23 transilluminator (Straight Endoilluminator; Alcon, Hünenberg, Switzerland) through the upper or lower canaliculus in order to identify the location of the lacrimal sac in the nasal cavity. A 30°, 4-mm rigid endoscope was used. Nasal mucosal incisions were made with an Ellmann tip above the insertion of the middle turbinate on the lateral nasal wall where the transilluminator was introduced. When the lacrimal bone was exposed after removal of the nasal mucosa, a bony opening was made using appropriate curettes and a diamond DCR bur (15°; Medtronic Xomed, Jacksonville, FL, USA). A Bowman's probe was introduced through the canaliculus, and then tenting the lacrimal sac, the lacrimal sac was opened with a sickle knife. Next, the Bowman's probe was entered into the upper and lower canaliculi, and we checked whether the common canalicular opening was intact. A distal or common canalicular obstruction was diagnosed if the probe tip could not be observed in the nasal cavity and resistance was felt. The level of obstruction was determined based on intraoperative probing. It was measured in millimeters from the puncta to the end of the probe where the obstruction was felt. According to Hwang et al. [7], a proximal canalicular obstruction was defined as resistance felt within 8 mm of the punctum, while a distal canalicular obstruction was defined as an obstruction located ≥ 9 mm from the punctum. In the present study, a distal canalicular obstruction was categorized as an upper, lower, or bicanalicular obstruction. A common canalicular obstruction was defined as an obstruction ≥ 10 mm from the upper and lower puncta.

We used a lacrimal trephine (Visitec Co., Sarasota, FL, USA) to overcome distal or common canalicular obstructions (Fig. 1). A canalicular trephine was inserted into the punctum with the stylet in place and advanced within the canaliculus to the obstruction site. When the obstruction

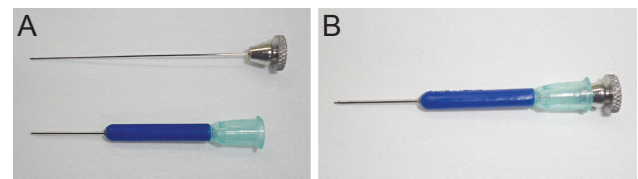


Fig. 1. Lacrimal trephine. (A) The trephine consisted of a 21-gauge stainless steel hypodermic tube affixed to a plastic luer hub. (B) There is rounded, blunt-tipped stylet that serves to protect the cutting edge during surgery.

was encountered, the stylet was removed, and the trephine was rotated in a boring manner until the tip emerged into the lacrimal sac. Extreme care was taken to avoid the formation of a false passage and to minimize trauma to the patent canaliculus. A Bowman's probe was reentered into the canaliculus, and a lack of resistance was confirmed. If resistance remained, the trephine was reinserted, and boring was repeated. After confirming that the canaliculus was unobstructed, one or two silicone tubes were passed through the canaliculi, directed out of the nasal cavity, and tied three times intranasally.

Postoperative care included oral antibiotics for one week, topical antibiotics and topical steroid eye drops for one month, and nasal steroids for one month. All patients had postoperative follow-up evaluations for up to six months after the operation. During the follow-up period, endoscopic examinations of the nasal cavity were performed to remove crusts, granulation tissue, and adhesions and to check the patency of the rhinostomy site using lacrimal irrigation. The silicone tubes were removed at least three months after the operation.

Functional success was judged by the patient's subjective resolution of epiphora, while anatomical success was determined by lacrimal irrigation. Functional success was defined when the patients denied having symptoms of epiphora. The procedure was defined as an anatomical success when the irrigation passed completely through the rhinostomy site into the nose and when regurgitation did not occur. Postoperative evaluations included asking subjects about symptoms of epiphora, lacrimal irrigation, and endoscopic evaluation of the surgical site at one week, one month, three months, and six months after the operation.

We determined the location of the canalicular obstruction and the number of silicone tubes used by reviewing medical records. Four oculoplastic surgeons participated in this study; their experience in nasolacrimal surgery was as follows: 10, 6, 4, and 1 years. The surgeons were placed into two groups based on whether they had greater or less than five years of experience. The surgical success rates were compared according to age, sex, location of the obstruction, number of silicone tubes, and experience of the surgeon.

Statistical analyses were conducted using SPSS ver. 18.0 (SPSS Inc., Chicago, IL, USA). Pearson chi-square test was used to compare the success rates, and *p*-values less than 0.05 were considered statistically significant.

Results

In total, 59 eyes of 57 patients (47 females and 10 males) were included. The mean age of the patients was 54.3 years (range, 20 to 74 years). The mean follow-up period was 7.8 months (range, 6 to 25 months). The mean duration of silicone tube insertion was 4.8 months (range, 3 to 7.5 months). Two patients (two eyes) previously had dacryocystitis, and two patients (two eyes) had previous endoscopic silicone tube placement.

Functional success, according to the patients' subjective resolution of epiphora, was achieved in 55 of 59 eyes (93.2%) at the one-month follow-up exam, in 50 eyes (84.7%) at the three-month follow-up exam, and in 46 eyes (77.9%) at the six-month follow-up exam. Anatomical success according to lacrimal irrigation was achieved in 58 of 59 eyes (98.3%) at the one-month follow-up exam, in 52 eyes (88.1%) at the three-month follow-up exam, and in 50 eyes (84.7%) at the six-month follow-up exam (Fig. 2).

To identify the factors that affected the success rates of this technique, we compared the anatomical success rates based on sex, age, location of the canalicular obstruction, number of silicone tubes used, and the experience of the surgeon (Table 1). There was no statistically significant difference in anatomical success rates according to sex. The subjects were divided into two groups, above and below 50 years old; however, there was no statistically significant difference in the anatomical success rate by age.

When classifying the location of canalicular obstructions, we observed lower canalicular obstructions in 28 eyes (47.4%), common canalicular obstructions in 14 eyes (23.7%), upper canalicular obstructions in nine eyes (15.2%), and bicanalicular obstructions in eight eyes

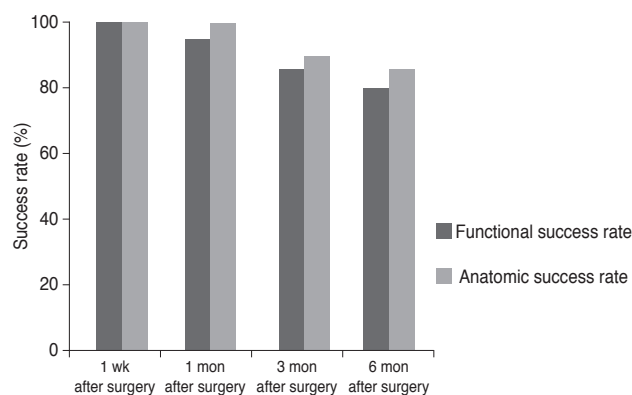


Fig. 2. Success rate according to follow-up period.

Table 1. Anatomical success rates according to the location of the obstruction, number of silicone tubes, and experience of the surgeon

	1 wk after surgery	1 mon after surgery	3 mon after surgery	6 mon after surgery
Sex				
Male (n = 10)	10 / 10 (100)	9 / 10 (90)	9 / 10 (90)	9 / 10 (90)
Female (n = 47)	47 / 47 (100)	47 / 47 (100)	43 / 47 (91.4)	41 / 47 (87.2)
<i>p</i> -value	-	0.603*	0.957*	0.870*
Age				
≥50 (n = 43)	43 / 43 (100)	43 / 43 (100)	40 / 43 (93)	38 / 43 (88.3)
<50 (n = 14)	14 / 14 (100)	13 / 14 (92.8)	12 / 14 (85.7)	12 / 14 (85.7)
<i>p</i> -value	-	0.719*	0.704*	0.912*
Location of the obstruction				
Common canaliculus (n = 14)	14 / 14 (100)	14 / 14 (100)	12 / 14 (85.7)	12 / 14 (85.7)
Upper canaliculus (n = 9)	9 / 9 (100)	9 / 9 (100)	6 / 9 (66.7)	6 / 9 (66.7)
Lower canaliculus (n = 28)	28 / 28 (100)	27 / 28 (96.4)	26 / 28 (92.8)	26 / 28 (92.8)
Bicanalicular (n = 8)	8 / 8 (100)	8 / 8 (100)	8 / 8 (100)	6 / 8 (75)
<i>p</i> -value	-	0.996*	0.268*	0.427*
No. of silicone tubes				
Single tube (n = 25)	25 / 25 (100)	25 / 25 (100)	22 / 25 (88.0)	21 / 25 (84)
Double tubes (n = 34)	34 / 34 (100)	33 / 34 (97.1)	30 / 34 (88.2)	29 / 34 (85.2)
<i>p</i> -value	-	0.387*	0.978*	0.955*
Experience of the surgeon (yr)				
>5 (n = 44)	44 / 44 (100)	43 / 44 (97.7)	43 / 44 (97.7)	42 / 44 (95.4)
<5 (n = 15)	15 / 15 (100)	15 / 15 (100)	9 / 15 (60)	8 / 15 (53.3)
<i>p</i> -value	-	0.556*	0.023*	0.008*

Values are presented as number (%).

*Pearson chi-square test.

(13.5%). The anatomical success rate at the six-month follow-up exam was 92.8% for lower canalicular obstructions, 85.7% for common canalicular obstructions, 66.7% for upper canalicular obstructions, and 75% for bicanalicular obstructions. However, there was no statistically significant difference between these groups ($p = 0.427$, Pearson chi-square test).

During the procedure, surgeons used single or double silicone tubes depending on their medical judgment. Double silicone tubes were placed in 34 eyes (57.6%), and a single silicone tube was placed in 25 eyes (42.4%). Anatomical success at the six-month follow-up exam was achieved in 84% of cases in the single tube group and in 85.2% of cases in the double tube group. However, no statistically significant difference was observed ($p = 0.955$, Pearson chi-square test).

Surgeons who had more than five years of experience performed the operations in 44 eyes (74.6%) and surgeons with less than five years of experience performed the operations in 15 eyes (25.4%). Comparing the two groups, anatomical success at the six-month follow-up exam was achieved in 95.4% of cases in the >5 years of experience group, and in 53.3% of cases in the <5 years of experience group. This difference was determined to be statistically significant ($p = 0.008$, Pearson chi-square test). The main cause of surgical failure was canalicular obstruction in both groups.

Among the nine eyes presenting with surgical failure at the six-month follow-up exam, a membranous obstruction was found in two eyes, and canalicular obstruction was found in the remaining seven. Only two patients underwent additional lacrimal surgery (i.e., canalicular trephina-

tion with silicone tube placement due to a recurring canalicular obstruction). DCR was repeated due to membranous obstruction of the internal ostium. When analyzing the cause of surgical failure based on the experience of the surgeon, we found that one eye in the >5 years of experience group presented with a membranous obstruction, and one eye presented with a canalicular obstruction. In the <5 years of experience group, one patient presented with a membranous obstruction, and six presented with a canalicular obstruction.

Postoperative complications were easily controlled. Granulation tissue developed around the rhinostomy site three to four weeks after surgery in 33 eyes (55.9%), but this was easily removed by suction tips or forceps during the follow-up exam. Inflammation of the surgical site occurred in five eyes (8.4%) but resolved after treatment with systemic and topical antibiotics and anti-inflammatory therapy. Synechia between the lateral nasal wall and the middle turbinate occurred in two eyes (3.3%), but they were treated using the appropriate instruments as soon as they were found. No cases of orbital tissue damage, cerebrospinal fluid leak, sump syndrome, or uncontrolled bleeding occurred.

Discussion

In the present study, we investigated the surgical outcomes of canalicular trephination in patients diagnosed with distal or common canalicular obstructions during endoscopic DCR. The functional success rate was 78%, and the anatomical success rate was 84% at the six-month follow-up exam. The anatomical success rate in this study gradually decreased from 98% to 84% during the six-month follow-up period. As there are a limited number of published reports dealing with the surgical outcomes of canaliculoplasty and because the surgical techniques used differ among published reports, it is difficult to make a direct comparison between the surgical results of the current study and previous reports. Nemet et al. [1] performed endoscopic DCR and trephination with mitomycin C administration in five eyes and reported a success rate of 80%. Boboridis et al. [5] reported an 85% functional anastomosis after external DCR combined with membranectomy was used to treat distal canalicular obstruction. Furthermore, Baek et al. [4] reported that complete success was

achieved in 80.6% of patients who underwent endoscopic DCR followed by canalicular trephination and silicone stenting. Based on these results, we believe that the surgical outcome of DCR combined with canalicular trephination is associated with a success rate of approximately 80%. This is a higher success rate than the surgical results of trephination alone without DCR. Khoubian et al. [8] showed a 49% complete success rate in patients who underwent only canalicular trephination followed by silicone stent intubation for the treatment of canalicular obstruction.

In this study, we selected patients who were intraoperatively diagnosed with a canalicular obstruction. Routine preoperative assessments with syringing and probing of both canaliculi may fail to identify a lacrimal obstruction. While assessing the efficacy of preoperative evaluations in the identification of distal canalicular obstructions, Boboridis et al. [5] showed that the pathology of a canalicular obstruction was accurately identified preoperatively in only 57% of patients. If a complete obstruction occurs proximal to the lacrimal sac, a conjunctivodacryocystorhinostomy with Jones tube placement can be planned preoperatively [9,10]; however, distal or common canalicular obstructions tend to be identified intraoperatively, rather than preoperatively. Thus, we often encounter such canalicular problems unexpectedly during surgery. If a distal or common canalicular obstruction is encountered during surgery, the surgeon has to immediately decide what technique to use in managing the obstruction. In reporting the effectiveness of bicanalicular double silicone intubation for treating a distal or common canalicular obstruction, Hwang et al. [7] showed multiple methods used for canaliculoplasty. In their large case series, membranectomy was used in 88 of 129 eyes; trephination was used in 19 eyes, and simple probing was used in 15 eyes to manage the canalicular obstruction. A canalicular obstruction is an anatomical factor that can lead to failure of a DCR surgery [2,3]. However, the outcomes of canaliculoplasty performed to treat distal or common canalicular obstructions remain the least investigated.

In this study, we compared surgical outcomes based on various factors, including the location of the obstruction, the number of silicone tubes used, and the experience of the surgeon. We found a statistically significant difference in surgical outcomes by comparing the experience of the surgeon. We did not find significant differences according

to the number of silicone tubes placed or the location of the obstruction. Boboridis et al. [5] showed that the success rate of trephination did not correlate with the experience of the surgeon, which is in contrast to our results. When assessing the cause of surgical failure based on the experience of the surgeon, we found that canalicular obstruction was the most common cause of anatomical failure in the <5 years of experience group. The postoperative canalicular obstruction likely resulted from ductal wall damage that might have occurred during trephination. To minimize postoperative reobstruction and pseudo-tract formation, the proximal and normal portions of the canaliculus must be sufficiently dilated before trephination. Additionally, the trephine must be gently advanced following the presumed normal anatomical path into the lacrimal sac, and the internal opening of the common canaliculus must be simultaneously observed from the nasal cavity via the endoscope. Postoperative canalicular obstructions occurred mostly in the <5 years of experience group, which could signify the surgeon's lack of skill and control in performing trephination. Therefore, careful handling during trephination is a significant factor that affects success rates.

Several previous reports have suggested that the success rate of trephination may correlate with the location of obstruction; however, in the present study there was no statistically significant relationship between the success rate and location of the obstruction. Khoubian et al. [8] performed canalicular trephination and silicone stent intubation for canalicular obstructions and achieved a high success rate in distal lower canalicular obstructions; however, the authors did not perform a statistical analysis. Nathoo et al. [11] evaluated the efficacy of trephination for primary canalicular obstructions and determined that it was difficult to draw any conclusions regarding the success of trephination in relation to the location of the obstruction. Despite not reaching a *p*-value of statistical significance, the anatomical success rate in the present study was the highest for distal lower canalicular obstructions (92.8%) and lowest for upper canalicular obstructions (66.7%).

Several previous reports have suggested that double intubation is better than single intubation in DCR with canaliculoplasty. Hwang et al. [7] performed bicanalicular double and single silicone tube placement during external DCR and canaliculoplasty carried out by probing, trephination, or membranectomy for distal or common canaliculus obstructions. A better anatomical success rate was re-

ported in the double silicone tube intubation group. You et al. [12] reported a 76.9% success rate for endoscopic DCR with two sets of silicone tube placement after a probing or trephination canaliculoplasty. However, in their study, the authors did not compare the surgical outcomes between the single and double silicone intubation groups. Kim and Kim [13] compared surgical outcomes between two groups of patients who underwent endoscopic DCR with lacrimal trephinated canaliculoplasty; however, there was no statistically significant difference between the groups. Paik et al. [14] compared surgical outcomes between double silicone stents and single silicone stents in endoscopic DCR with lacrimal trephinated canaliculoplasty and showed that the double stent group had a higher success rate. In the present study, there was no statistically significant difference in surgical outcomes between the single and double tube intubation groups. It is difficult to explain why different results were obtained in our study; however, there is some disagreement regarding the correlation between surgical outcome and the number of silicone tubes used. For example, Chong et al. [15] compared patients who did and did not receive intubation during endonasal endoscopic mechanical DCR for primary acquired nasolacrimal duct obstructions and reported that no difference was found. This is in spite of the fact that most oculoplastic surgeons perform silicone intubation because they believe it prevents recurrence and increases the success rate of endoscopic DCR.

The limitations of this study include its retrospective nature and lack of appropriate controls. However, this study did yield information on varying success rates (based on such factors as the location of the canalicular obstruction, number of silicone tubes, and experience of the surgeon) of canalicular trephination when a surgeon encounters a preoperatively undiagnosed canalicular obstruction.

In conclusion, our study indicates that the success rate of canalicular trephination combined with endoscopic DCR in patients with a distal or common canalicular obstruction decreased gradually during the 6-month follow-up period. Neither the location of the obstruction nor the number of silicone tubes affected the surgical success rate, but the experience of the surgeon did have an effect. This finding signifies that skilled and careful handling during trephination is a significant factor affecting success rates for this procedure.

Conflict of Interest

No potential conflict of interest relevant to this article was reported.

References

1. Nemet AY, Wilcsek G, Francis IC. Endoscopic dacryocystorhinostomy with adjunctive mitomycin C for canalic-
ular obstruction. *Orbit* 2007;26:97-100.
2. Welham RA, Henderson PH. Results of dacryocystorhinostomy analysis of causes for failure. *Trans Ophthalmol Soc U K* 1973;93:601-9.
3. Boboridis K, Ziakas N, Georgiadis N. Nasolacrimal intubation with mitomycin C. *Ophthalmology* 2004;111:416-7.
4. Baek BJ, Hwang GR, Jung DH, et al. Surgical results of endoscopic dacryocystorhinostomy and lacrimal trephination in distal or common canalicular obstruction. *Clin Exp Otorhinolaryngol* 2012;5:101-6.
5. Boboridis KG, Bunce C, Rose GE. Outcome of external dacryocystorhinostomy combined with membranectomy of a distal canalicular obstruction. *Am J Ophthalmol* 2005;139:1051-5.
6. Narioka J, Ohashi Y. Transcanalicular-endonasal semicon-
ductor diode laser-assisted revision surgery for failed external dacryocystorhinostomy. *Am J Ophthalmol* 2008;146:60-8.
7. Hwang SW, Khwarg SI, Kim JH, et al. Bicanalicular double silicone intubation in external dacryocystorhinostomy and canaliculoplasty for distal canalicular obstruction. *Acta Ophthalmologica* 2009;87:438-42.
8. Khoubian JF, Kikkawa DO, Gonnering RS. Trephination and silicone stent intubation for the treatment of canalic-
ular obstruction: effect of the level of obstruction. *Ophthal Plast Reconstr Surg* 2006;22:248-52.
9. Jones LT. The cure of epiphora due to canalicular disorders, trauma and surgical failures on the lacrimal passages. *Trans Am Acad Ophthalmol Otolaryngol* 1962;66:506-24.
10. Jones LT. Conjunctivodacryocystorhinostomy. *Am J Ophthalmol* 1965;59:773-83.
11. Nathoo NA, Rath S, Wan D, Buffam F. Trephination for canalicular obstruction: experience in 45 eyes. *Orbit* 2013;32:281-4.
12. You YG, Choi HS, Ryou JH, Kim SJ. The results of endo-
scopic canaliculocystodacryorhinostomy with two sets of silicone tube intubation in canalicular obstruction. *J Korean Ophthalmol Soc* 2004;45:882-6.
13. Kim SJ, Kim SD. The surgical results of endonasal DCR with two silicone tubes in common canalicular obstruction. *J Korean Ophthalmol Soc* 2007;48:1170-6.
14. Paik JS, Cho WK, Yang SW. Bicanalicular double silicone stenting in endoscopic dacryocystorhinostomy with lacri-
mal trephination in distal or common canalicular obstruc-
tion. *Eur Arch Otorhinolaryngol* 2012;269:1605-11.
15. Chong KK, Lai FH, Ho M, et al. Randomized trial on sili-
cone intubation in endoscopic mechanical dacryocystorhi-
nostomy (SEND) for primary nasolacrimal duct obstruc-
tion. *Ophthalmology* 2013;120:2139-45.