

A Case of Epidemic Keratoconjunctivitis Complicated by *Alcaligenes xylosoxidans* Infection

Joo Youn Oh, MD^{1,2}, Young Joo Shin, MD^{1,2,3}, Won Ryang Wee, MD^{1,2,3}

Department of Ophthalmology, Seoul National University College of Medicine¹, Seoul, Korea
Seoul Artificial Eye Center, Seoul National University Hospital Clinical Research Institute², Seoul, Korea
Seoul National University Bundang Hospital³, Seongnam, Gyeonggi-do, Korea

Purpose: To report a case of epidemic keratoconjunctivitis complicated by *Alcaligenes xylosoxidans*.

Methods: A 37-year-old man suffered epidemic keratoconjunctivitis in both eyes. Eleven days later, he developed a corneal ulcer in his left eye. Bacterial staining, culture, and antibiotics sensitivity test were performed from a corneal scrape.

Results: The cultures revealed a growth of *Alcaligenes xylosoxidans*, and the patient was treated with ceftazidime and levofloxacin, based on the sensitivity test results. After 21 days of treatment, the infection was resolved with mild scarring and final vision in the left eye of 20/20.

Conclusions: *Alcaligenes xylosoxidans* should be considered a rare but potential pathogen able to produce corneal ulcer complication in epidemic keratoconjunctivitis. *Korean Journal of Ophthalmology* 19(3):233-234, 2005

Key Words: Achromobacter xylosoxidans, *Alcaligenes xylosoxidans*, Corneal ulcer, Epidemic keratoconjunctivitis, Keratitis

Alcaligenes xylosoxidans is an opportunistic, aerobic, gram-negative, rod-shaped bacterium that rarely causes an ocular infection. It usually infects a compromised or traumatized cornea and does not respond to conventional antibiotics therapy. We report a case of epidemic keratoconjunctivitis complicated by *Alcaligenes xylosoxidans*.

Case Report

A 37-year-old man was referred to our clinic for management of a corneal ulcer in his left eye. He had initially presented to his referring eye specialist 14 days earlier, complaining of red eye and mucopurulent discharge. He was diagnosed with epidemic keratoconjunctivitis in both eyes, and treated with tobramycin (0.3%). Eleven days later, he developed pain and decreased vision in his left eye, and was found to have a corneal erosion. A pressure patch was applied, but the symptoms were aggravated. At this point he was referred to our clinic. There was no history of ocular trauma, surgery, and contact lens wear. He was generally healthy. All members of his family had suffered epidemic

keratoconjunctivitis during the same period and were treated without any complications.

On presentation, his visual acuity was hand motion in the left eye. Slit lamp examination revealed severe follicular hypertrophy with pseudomembrane in the left conjunctiva, and stromal infiltrates with a central epithelial defect and diffuse edema in the left cornea (Fig. 1A).

The infiltrate was scraped for cytology and cultured on thioglycolate broth, blood, chocolate, and Sabouraud agar. Gram-negative rods were found on smear (Fig. 2), and the treatment was modified to fortified gentamicin and levofloxacin (Cravit[®], Santen Pharm, Co., Japan) every two hours. After 7 days of treatment, cultures revealed a growth of *Alcaligenes xylosoxidans*, and sensitivity tests showed that the organism was resistant to tobramycin, gentamicin, amikacin and cefazolin, but sensitive to ceftazidime, levofloxacin, and piperacillin. The treatment was therefore changed to fortified ceftazidime and levofloxacin (Cravit[®], Santen Pharm, Co., Japan) every 4 hours. The patient completed a tapering course of antibiotics 21 days after our initial consultation. His vision was 20/20 in the left eye, and the ulcer was resolved with mild scarring (Fig. 1B).

Discussion

Alcaligenes xylosoxidans is an opportunistic, aerobic, gram-negative, rod-shaped bacterium that is oxidase positive and nonlactose fermenting. The first reported ocular infection

Received: March 18, 2005 Accepted: August 8, 2005

Reprint requests to Won Ryang Wee MD, PhD. Department of Ophthalmology, Seoul National University College of Medicine, Seoul National University Bundang Hospital, #300 Gumi-dong, Bundang-gu, Seongnam, Gyeonggi-do 463-707, Korea. Tel: 82-31-787-7371, Fax: 82-31-787-4057, E-mail: wrwee@snu.ac.kr

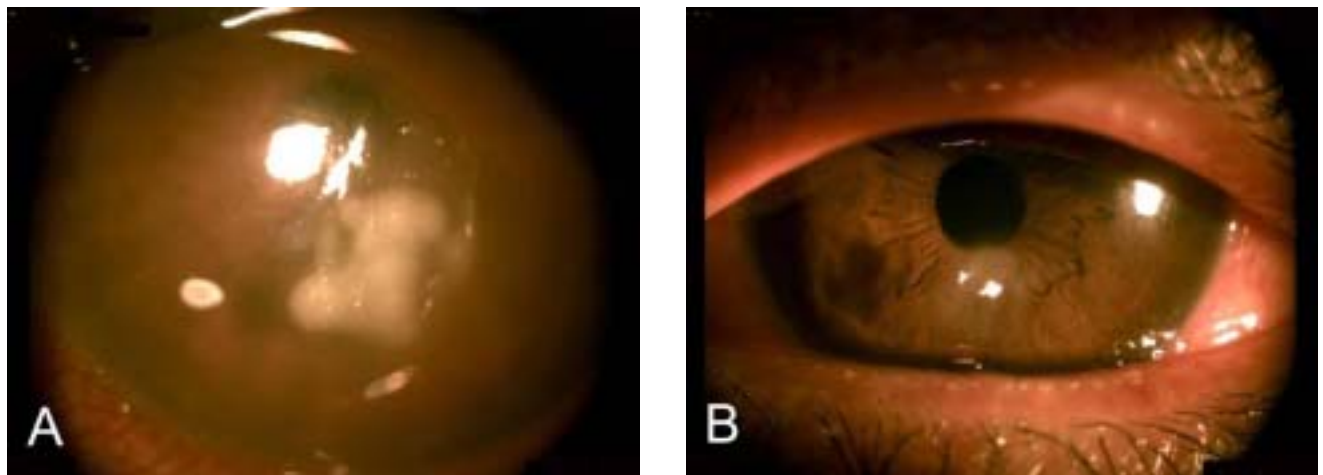


Fig. 1. (A) Corneal stromal infiltration with irregular border, corneal edema, and central epithelial defect were observed on presentation. (B) Corneal edema and infiltration disappeared after three weeks of treatment.

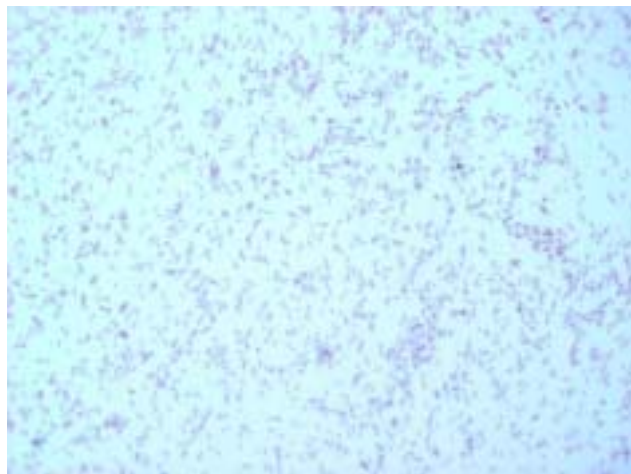


Fig. 2. Many bacilli with gram-negative staining are evident in the culture media.

by *A. xylosoxidans* was in 1977, when it was isolated from the orbit of a patient who had lost the globe after a penetrating injury from shrapnel.¹ To our knowledge, this is the first report in Korea, following six cases worldwide in the literature of corneal infections with *A. xylosoxidans*.¹⁻⁵ All six patients had had compromised or traumatized corneas and did not respond to conventional antibiotics therapy such as tobramycin, gentamicin, cefazolin, and amikacin. Our case is unique in that the infection occurred in underlying epidemic keratoconjunctivitis.

Corneal superinfection may occur after an epidemic conjunctivitis. Use of topical corticosteroid to treat conjunc-

tivitis or associated keratopathy can predispose an already compromised cornea to develop microbial keratitis. Our patient had no history of steroid use, but had a corneal erosion. We presumed that the corneal erosion caused destruction of corneal integrity and increased susceptibility of the cornea to bacteria in our patient.

In conclusion, *Alcaligenes xylosoxidans* should be considered a rare but potential pathogen able to produce corneal ulcer complication in epidemic keratoconjunctivitis. It may not respond to conventional, broad-spectrum antibiotics. Precise identification of the causative organism through cultures and appropriate management through antibiotic sensitivity tests are mandatory.

References

1. Holmes B, Snell JJ, Lapage SP. Strains of *Achromobacter xylosoxidans* from clinical material. *J Clin Pathol* 1977; 30:595-601.
2. Newman PE, Hider P, Waring GO III, et al. Corneal ulcer due to *Achromobacter xylosoxidans*. *Br J Ophthalmol* 1984; 68:472-4.
3. Pan TH, Heidemann DG, Dunn SP, et al. Delayed onset and recurrent *Alcaligenes xylosoxidans* keratitis. *Cornea* 2000;19:243-5.
4. Fiscella R, Noth J. *Achromobacter xylosoxidans* corneal ulcer in a therapeutic soft contact lens wearer. *Cornea* 1989;8:267-9.
5. Siganos DS, Tselentis IG, Papatzanaki ME, et al. *Achromobacter xylosoxidans* keratitis following penetrating keratoplasty. *Refract Corneal Surg* 1993;9:71-3.