

# Neuroprotective Effect of Citicoline on Retinal Cell Damage Induced by Kainic Acid in Rats

Yong Seop Han, MD, In Young Chung, MD, Jong Moon Park, MD, PhD, Ji Myeong Yu, MD, PhD

Department of Ophthalmology, College of Medicine, Gyeongsang National University, Jinju, Korea

**Purpose:** To examine whether citicoline has a neuroprotective effect on kainic acid (KA)-induced retinal damage.

**Methods:** KA (6 nmol) was injected into the vitreous of rat eyes. Citicoline (500mg/kg, i.p.) was administered to the rats once before and twice a day after KA-injection for 3- and 7-day intervals. The neuroprotective effects of citicoline were estimated by measuring the thickness of the various retinal layers using hematoxylin-eosin (H&E) staining. In addition, immunohistochemistry was conducted to elucidate the expression of endothelial nitric oxide synthase (eNOS) and neuronal nitric oxide synthase (nNOS).

**Results:** Morphometric analysis of retinal damage in KA-injected eyes showed significant cell loss in the inner nuclear layer (INL) and inner plexiform layer (IPL) of the retinas at 3 and 7 days after KA injection, but not in the outer nuclear layer (ONL). At 3 days after citicoline treatment, no significant changes were detected in the retinal thickness and immunoreactivities of eNOS and nNOS. The immunoreactivities of eNOS and nNOS increased in the retina at 7 days after the KA injection. However, prolonged treatment for 7 days significantly attenuated the immunoreactivities and the reduction of thickness.

**Conclusions:** The results indicate that citicoline has a neuroprotective effect on KA-induced neurotoxicity in the retina. *Korean Journal of Ophthalmology* 19(3):219-226, 2005

**Key Words:** Citicoline, Kainic acid, Neuroprotective effect, NOS

Retinal ischemic injuries are known to be associated with excitotoxicity of glutamate.<sup>1,2</sup> It is generally believed that ischemia caused by elevated intraocular pressure (IOP), which elicits mechanical damage to the retinal cells or impedes blood flow, plays an important role in the mechanism of how retinal ganglion cell death occurred.<sup>3-7</sup> In addition to retinal ischemia, excitotoxicity of glutamate, lack of neurotrophin and oxidative damage are also discussed as possible causes of retinal ganglion cell death.<sup>8,9</sup>

In a hypoxic state, there is a large release of the excitatory neurotransmitter, glutamate, into the extracellular space<sup>10-12</sup> and resultant glutamate excitotoxicity, which is promoted by N methyl D aspartate (NMDA) and kainate receptors. The excitotoxicity induced by kainic acid (KA), a glutamate analogue, involves a process in which AMPA/KA receptors are overstimulated, which in turn leads to Na<sup>+</sup> influx, cell depolarization and eventually excessive influx of Ca<sup>2+</sup> as the voltage-dependent Ca<sup>2+</sup> channel become permeable to Ca<sup>2+</sup>. Excessive accumulation of Ca<sup>2+</sup> by neural cells activates cellular proteases and nitric oxide synthase (NOS) and

increases oxygen consumption.<sup>13-15</sup> The generation of nitric oxide (NO) and NOS following the process described above triggers the fragmentation of DNA, which in turn leads to retinal ganglion cell death through the elevation of p53.<sup>16</sup>

NO mediates several biological actions, including relaxation of blood vessels and cytotoxicity, and acts as gaseous neurotransmitters in the central and peripheral nervous system.<sup>17,18</sup> Also, it plays an important role in neuronal damage in the CNS following brain ischemia, and the administration of NOS inhibitors protected the retina from degenerative changes and provided protection of retinal ganglion cells from ischemic damage.<sup>19-23</sup>

Citicoline (Cytidine-5-diphosphocholine, exogenous CDP-choline), first synthesized by Eugene Kennedy in 1956, has proved effective in treating a wide range of cognitive disorders caused by CNS ischemia, brain injury and Parkinson's disease.<sup>24,25</sup> Endogenous CDP-choline is a key intermediary in the biosynthesis of phosphatidylcholine (PtdCho). Increased biosynthesis of PtdCho prevents neuronal apoptosis and promotes neuroprotection. Citicoline is also known to preserve cardiolipin and sphingomyelin, stimulate glutathione biosynthesis, increase the activity of glutathione reductase and reduce lipid peroxidation.<sup>24,25</sup>

This study aimed to evaluate the neuroprotective effects of citicoline by analyzing the morphometric features of cells and the expression of NOS in the adult rat retina after KA-

Received: May 12, 2005 Accepted: August 25, 2005

Reprint requests to Jong Moon Park, MD, Department of Ophthalmology, College of Medicine, Gyeongsang National University, #92 Chillam-dong, Jinju, Gyeong-nam 660-280, Korea. Tel: 82-55-750-8170, Fax: 82-55-758-4158, E-mail: jmpark@gshp.gsnu.ac.kr

induced injuries.

## Materials and Methods

### 1. Sample animals preparation

Sprague-Dawley (SD) white male rats (Samtaco, Osan, Korea) weighing 200-250 g were maintained in cages under a 12-hour light and 12-hour dark cycle for a week. A total of 60 rats were divided into three groups of 20 rats each: rats treated with KA only, rats treated with citicoline one hour prior to and twice a day after the administration of KA, and normal rats (the control group). Each group were subdivided into 3- and 7-day subgroups according to time duration after injection.

### 2. A rat model for the study of Kainic acid-induced retinal damage

Each rat was intraabdominally anesthetized with a combination of a 30 mg/kg dose of ketamine (Yohan Ketamine, Yohan Corporation) and a 2.5 mg/kg dose of xylazine (Yuhan Rompun, Yuhan Corporation). The anesthetized rat was immobilized in a stereotaxic frame and a drop of ofloxacin was administered into the eye to avoid infection.

KA (Sigma, USA) was dissolved in 2 mM, 3  $\mu$ l (6 nM) of which was injected into the vitreous of the rat eyes using a 30 gauge microsyringe.<sup>26</sup> An ophthalmoscopic examination was performed to ensure that KA was accurately injected into the vitreous of the rat eyes, after which ofloxacin was once again applied.

### 3. Citicoline administration

After KA injection, rats were housed in separate cages according to the subclassification of the 3- and 7-day groups. Citicoline-treated rats received 500 mg/kg citicoline intraabdominally an hour prior to and twice a day at 12-hour intervals after KA injection. This procedure was routinely performed without anesthesia.

### 4. Tissue isolation

On days 3 and 7 after KA injection, 10 rats in each subgroup were sacrificed and the eyes were rapidly enucleated. The cornea was removed promptly from the enucleated eyeballs and then placed into 4% neutralized phosphate buffered paraformaldehyde (NBP). After an hour, the lens was removed and the eyeballs were fixed in the same NBP for 5 hours, after which the eyeballs were washed in 0.1 M PB (phosphate buffer), and soaked for 24 hours in 30% PB sucrose to prevent irreversible damage to the tissues. After soaking, sucrose solution was carefully washed off the tissue surface, and the tissues were embedded in OCT compound (Tissue-Tek<sup>®</sup>), frozen in isopentane cooled with liquid

nitrogen and then stored at -70°C until sectioning.

The tissues were kept at -20°C for an hour for sectioning into 12  $\mu$ m-thick continuous frozen sections with a cryostat (Leica, Meyer Instruments, Inc. Houston, TX). The sections were mounted on gelatin-coated slides, dried for 30 minutes at 42°C and stored at -70°C until use.

### 5. Morphometric features

The prepared frozen sections were kept at room temperature for about an hour, dehydrated to increase the stickiness between the section and the slide, washed in two changes of distilled water for 5 minutes each and dehydrated again by water deprivation. After dehydrating, the sections were stained in 0.5% hematoxylin for 5 minutes, washed in two to three changes of distilled water, soaked in hydrochloric acid for a second time and then washed in several changes of distilled water to enhance the color after hematoxylin staining. The hematoxylin-stained sections were double-stained with 0.6% eosin for 2 minutes, dehydrated through a graded alcohol series (1 minute each in 70%, 80%, 90%, 95%, and 100%), cleared in xylene series and mounted permanently. Stained tissue slides were examined using a microscope and pictures were taken. To examine the morphometric changes of the retina after administering KA and citicoline, the layer-structure of the retina thickness and retinal cells in treated and control rats were assessed and compared at the location of 800-1,000  $\mu$ m from the optic nerve in five slides per rat.

### 6. NOS immunohistochemistry

The prepared frozen sections were kept at room temperature for about an hour and dehydrated by water deprivation. After dehydrating, the sections were washed in 0.02M phosphate buffer saline (PBS), 0.5% Triton X-100/0.02 M PBS and 0.02 M PBS for 15 minutes each, treated in 0.3% H<sub>2</sub>O<sub>2</sub> for 30 minutes to inactivate endogenous peroxidase, and washed again in the same way as described above. After washing, normal serum was applied to the slides, which were then incubated for 30 minutes. After normal serum was cleaned up, each primary antibody was applied to the slides, which were then incubated for 16 to 18 hours at 4°C. For the primary antibodies against neuronal NOS (nNOS) and endothelial NOS (eNOS), mouse anti-nNOS monoclonal and mouse anti-eNOS polyclonal antibodies were used. Anti-nNOS and anti-eNOS primary antibodies were applied at a dilution of 1:100. Unbound primary antibody was washed off with 0.02 M PBS, 0.5% Triton X-100/0.02 M PBS and 0.02 M PBS, for 15 minutes each. The sections were subsequently reacted with secondary antibody (biotinylated anti-mouse IgG) for 90 minutes at room temperature. After unbound secondary antibody was washed off in the same way as described above, the slides were reacted for 90 minutes at room temperature using an

Avidin Biotin Complex kit (Vectastain, Vector Labs, Burlingame, CA) and washed again. After washing, 0.05% DAB (3, 3'-diaminobenzidine tetrahydrochloride, SIGMA) was completely dissolved in 0.05 M Tris buffer at pH 7.6 and filtered through 3 M microfilter paper. The sections were then incubated with filtered DAB solution for 10 minutes. DAB was activated by adding 0.03% H<sub>2</sub>O<sub>2</sub> to the solution and mixing them well. After immunohistological staining, the sections were washed again in the same way as described above, dehydrated through a graded alcohol series (2 minutes each), cleared in xylene series and mounted permanently in Canada balsam. A microscopic examination was performed.

## 7. Retinal thickness measurement and statistical analysis

The retinal layer thickness was obtained through measurements of three different positions: the outer nuclear layer (ONL), the inner nuclear layer (INL) and the inner plexiform layer (IPL). Retinal structure (thickness) and cell changes at the location of 800-1000  $\mu$ m from the optic nerve in five slides per each rat were measured using a soft imaging system (GmbH, Germany). With regard to immunohistological staining, the intensity of eNOS immunoreactivity was graded using a soft imaging system and cells expressing nNOS immunoreactivity were counted. All data was expressed as mean  $\pm$  standard error of the mean. The one-way ANOVA test was performed for statistical analysis.

## Results

### 1. Effects of Citicoline on retinal damage in KA-injected eyes

Morphometric analysis revealed that the thickness of

retinal layers was significantly thinned in KA-injected rats, compared with citicoline-treated rats. Retinal layers became gradually thinner in the extent of the retinal cell damage on day 3 after KA injection, and retinal thickness in the KA-injected group was reduced by 58% on day 7 after KA injection, compared with control rats (Fig. 2). A reduction in INL and IPL thicknesses was observed within 7 days of KA injection. INL was reduced to only 2-3 layers (Fig. 1, 2). While the decrease in retinal thickness of INL and IPL was substantial, the change of the outer plexiform layer (OPL) thickness was meager. In addition, ganglion cells were displaced or lost, and the inner limiting membrane was partially destroyed.

KA injection decreased the IPL and INL thicknesses in the KA-injected rats by 42.9% and 38.0% on day 3, and by 85.7% and 64.3% on day 7, respectively, showing a marked decrease in thickness (Fig. 1-3).

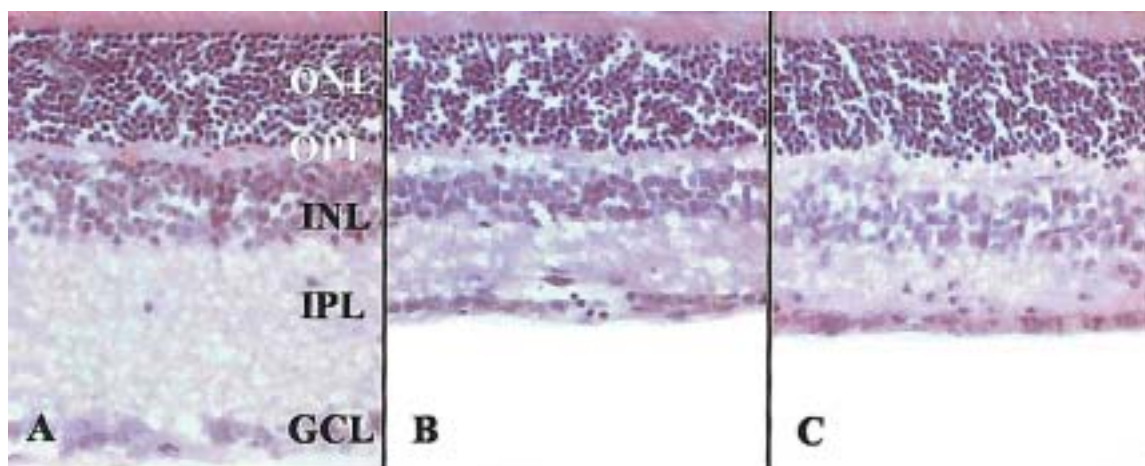
In citicoline-treated rats, the retinal thickness was thinner on day 3 after KA injection, but the difference in thickness was not statistically significant. The thickness of retinal layers and cell numbers decreased by as much as about 40% on day 7, compared with control rats. The IPL and INL thicknesses were reduced by about 65% and 47%, respectively (Fig. 1-3).

### 2. Effects of Citicoline on Neurotransmitters

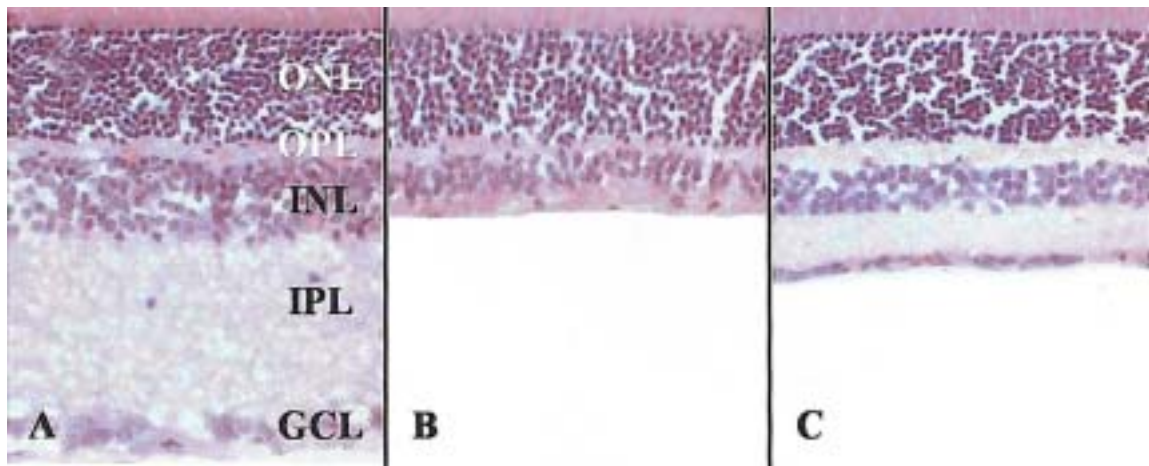
#### 1) The expression of eNOS

The neuroprotective effects of citicoline on the retinal damage in KA-injected eyes were analyzed by means of immunohistochemistry for eNOS.

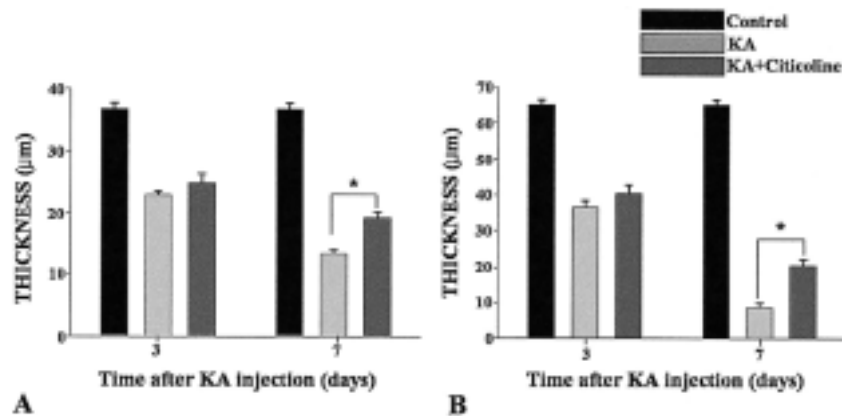
In control rats, retinal vessels were weakly stained for eNOS, but eNOS-expressing cells were not detected. The intensity of eNOS immunoreactivity substantially increased in



**Fig. 1.** Representative photomicrographs of transverse sections in rat retina at 3 days after KA injection using H-E staining. In control retina, five, well organized retinal layers are seen (A). The thickness of the retina is markedly reduced due to loss of IPL and INL in the KA-injected group (B) but is more conserved in the citicoline treated KA-injected group than in the KA-injected group (C). ONL: outer nuclear layer; OPL: outer plexiform layer; INL: inner nuclear layer; IPL: inner plexiform layer; GCL: ganglion cell layer; CTL: control rats; KA: kainic acid-injected group; Citicoline: citicoline treated group with KA injection.

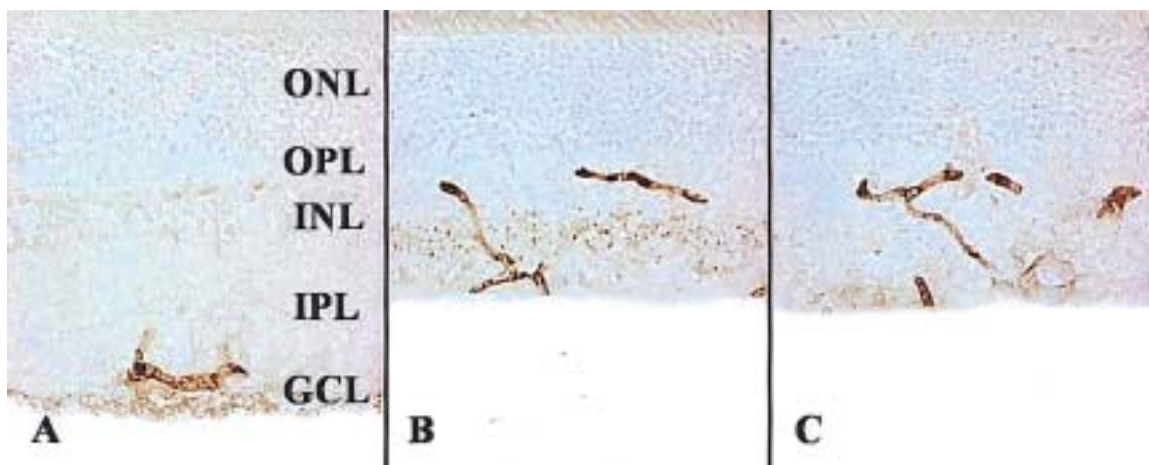


**Fig. 2.** Representative photomicrographs of transverse sections in rat retina at 7 days after KA injection using H-E staining. In control retina, five, well organized retinal layers are seen (A). The thickness of the retina is markedly reduced due to loss of IPL and INL in the KA-injected group (B) but is well conserved in the citicoline treated KA-injected group (C).



**Fig. 3.** (A) Qualification of changes in the thickness of the inner nuclear layer (INL) in each group at 3 and 7 days after KA injection. The difference shows statistical significance between the citicoline treated and only KA-injected groups at 7 days. (B) Qualification of changes in the thickness of the inner plexiform layer (IPL) in each group at 3 and 7 days after KA injection. The difference also shows statistical significance between the citicoline treated and only KA-injected groups at 7 days (\* $P < 0.05$ ).

KA: kainic acid-injected group; Citicoline: citicoline-treated group with KA injection.



**Fig. 4.** Photomicrographs of rat retina of the 3 groups using eNOS immunohistochemistry at 3 days after KA injection. In the citicoline-treated rats (C), immunoreactivity was a little weakened than in the kainic acid-injected group (B). Control group was (A).



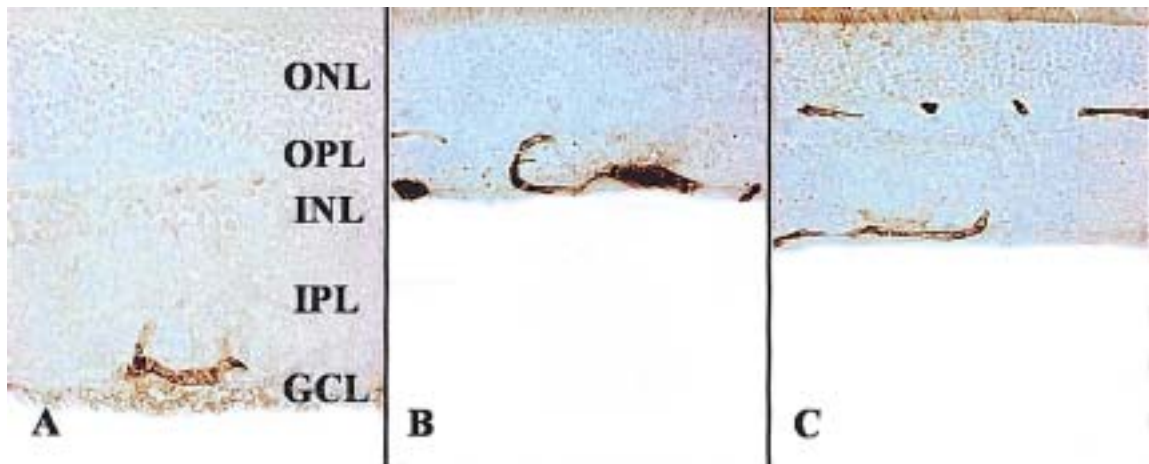


Fig. 5. Photomicrographs of rat retina of the 3 groups using eNOS immunohistochemistry at 7 days after KA injection. In the citicoline-treated rats (C), immunoreactivity was more weakened than in the kainic acid-injected group (B). Control group was (A).

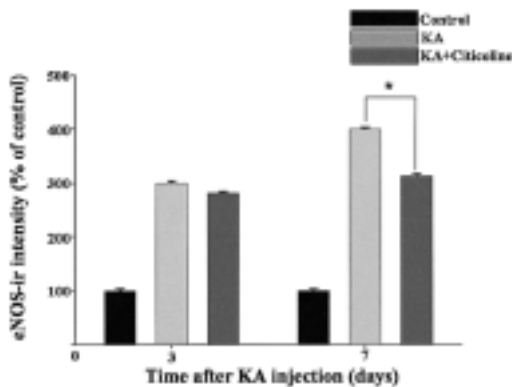


Fig. 6. Graphs showing the mean percentage value of the intensity of the eNOS (endothelial nitric oxide synthase) immunoreactivity (mean%±SD) in the retinas of the 3 groups. KA-induced retinal damage increased eNOS immunoreactivity in the retina. In the citicoline-treated retina, eNOS immunoreactivity were significantly decreased at 7 days (\* $P < 0.05$ ).

KA-injected rats on day 3 after injection (Fig. 4), and a greater intensity of eNOS immunoreactivity was detected in the retinal vessels, as well as in the ganglion cells, on day 7 (Fig. 5). In citicoline-treated rats, a higher intensity of eNOS immunoreactivity was observed, compared with control rats, but it was lower than that of KA-injected rats, although the difference was not statistically significant (Fig. 4, 6). The intensity of eNOS immunoreactivity was significantly lower in citicoline-treated rats than that of KA-injected rats on day 7 ( $p < 0.05$ ) (Fig. 5, 6).

## 2) The expression of nNOS

In control rats, nNOS-expressing cells were present in INL and the ganglion cell layer (GCL). Amacrine cells spread their dendrites in the IPL, and dendrites were stained for nNOS. The population of cells expressing nNOS significantly increased in the INL, as well as in the GCL, on day 3 after injection in the KA-injected rats and citicoline-treated rats,

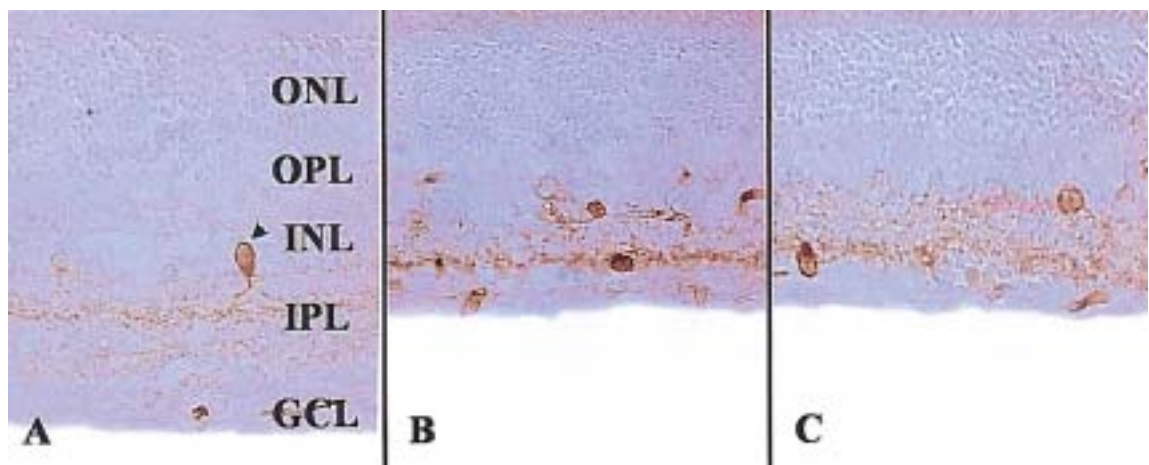


Fig. 7. Photomicrographs of rat retina of the 3 groups using nNOS immunohistochemistry at 3 days after KA injection. In the citicoline-treated rats (C), immunoreactive cells were a little decreased than in the kainic acid-injected group (B). Control group was (A).

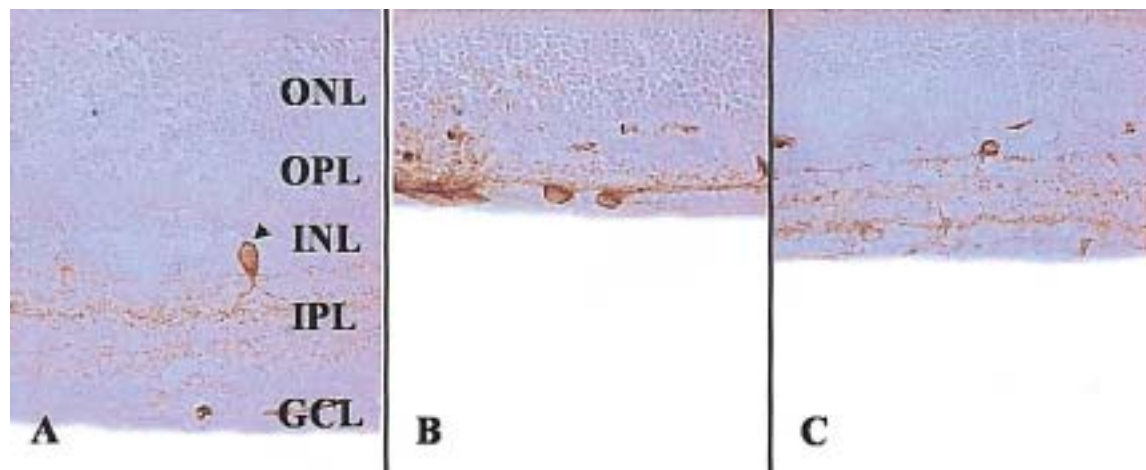


Fig. 8. Photomicrographs of rat retina of the 3 groups using nNOS immunohistochemistry at 7 days after KA injection. In the citicoline-treated rats (C), immunoreactive cells were more decreased than in the kainic acid-injected group (B). Control group was (A).

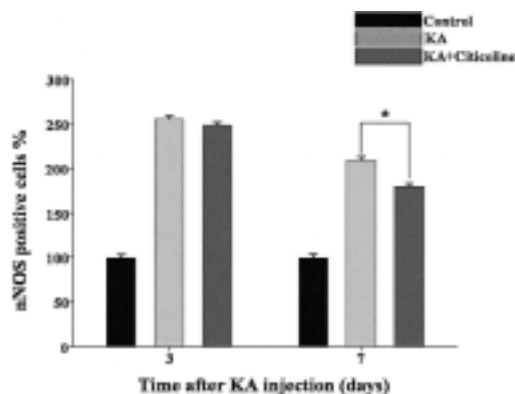


Fig. 9. Graphs showing the mean percentage value of the number of nNOS immunoreactive cells (mean $\pm$ SD) in the retinas of the 3 groups. KA-induced retinal damage increased nNOS immunoreactive cells in the retina. In the citicoline-treated retina, nNOS immunoreactive cells significantly decreased at 7 days (\* $P < 0.05$ ).

compared with control rats ( $p < 0.05$ ). The difference in cell population between the treatment groups was not significant (Fig. 7, 9). The nNOS-expressing cell population was significantly reduced in the citicoline-treated rats on day 7, compared with the KA-injected rats ( $p < 0.05$ ) (Fig. 8, 9).

## Discussion

It is well known that the mechanisms behind retinal damage involve overproduction of reactive free radicals and excessive accumulation of calcium by neural cells, which in turn leads to a deterioration of the retinal cells and ultimately cell death.<sup>27</sup> The rat model of retinal damage is usually induced as ischemic injuries through blockage of the blood flow by closing the carotid artery, ligation of the optic nerve, including the central retinal artery, and IOP elevation.<sup>28,29</sup> NMDA receptor-mediated neurotoxicity is also used to

induce retinal damage in rats.

Optic nerve disorders, retinal ischemic injuries and glaucoma are commonly manifested by a high concentration of glutamate.<sup>12,31,32</sup> Glutamate, a major neurotransmitter as well as an amino acid, can cause excitotoxicity and damage to the retina when its concentration is elevated for a long time.<sup>33,34</sup> Glutamate excitotoxicity is promoted by NMDA and kainate receptors.<sup>35-37</sup>

The efficacy of citicoline has been proven in many studies of brain injury, Alzheimer's disease, Parkinson's disease and CNS damage. Citicoline was also effective for improving visual acuity in amblyopia therapy.<sup>38</sup> Citicoline increased the release of dopamine from the retina,<sup>39</sup> had a neuroprotective effect on visual field and decreased the death of ganglion cells in glaucoma therapy.<sup>25</sup> However, there have been no studies of the effects of citicoline on the retinal ischemic injury and the expression of NOS after KA-induced injuries. KA is an analog of the major excitatory neurotransmitter glutamate.

KA-induced retinal damage is clinically and pathologically similar to retinal ischemic injuries or glaucomatous optic nerve damage in terms of the morphological and physiological features. One study of the mechanism for KA-induced retinal damage using a rat model also investigated KA-induced retinal degeneration and outcomes of citicoline treatment in damaged retina.<sup>40</sup> In agreement with earlier studies, the present study also found a substantial cell loss in the GCL and a significant loss of thickness in the IPL and INL, but much less change in the ONL. The finding that the ONL was not affected as much as other retinal layers during the 7 days after KA injection raises the likelihood that subsequent cellular damage and cell death in the ONL was not caused by overstimulation of glutamate receptors. This possibility is further supported by the findings that ionotropic and metabotropic glutamate receptors were not present in the ONL, although they were extensively distributed among cells

in the GCL and INL.

Among three structurally distinct isoforms of NOS, nNOS and eNOS are constitutively expressed. These two NOS isoforms are activated by calcium/calmodulin complex in the cell and produce NO, which is indispensable in neurotransmission and relaxation of vascular smooth muscle by activating guanylate cyclase. As proved in brain injuries, retinal expression of NO played a key role in regulating retinal blood flow given the ultrastructural relationship between NOS-expressing cells and retinal blood vessels,<sup>43</sup> and retinal expression of NO was also involved killing neuronal cells.<sup>44</sup> Immunohistochemistry showed a widespread distribution of nNOS in a population of cells in the INL and amacrine cells in the GCL, and nNOS activity was also seen among horizontal cells and photoreceptors.<sup>45</sup> The presence of eNOS was observed in not only retina cells and vascular endothelial cells in the choroid, but also in glial cells.<sup>46,47</sup> The present study also found a distribution of NOS isoform in a similar pattern to that reported by earlier studies. One study claimed that the role of nNOS is more important than that of eNOS in the pathology of various disorders associated with excitotoxicity.<sup>48</sup> In the present study, the immunoreactivity of both nNOS and eNOS increased following KA injection, and the expression of both NOS isoforms was significantly weaker in citicoline-treated rats than in KA-injected rats ( $p < 0.05$ ). It is therefore likely that the two NOS isoforms are closely related to each other.

One of the important findings of this study was the significantly increased expression of NOS isoforms in all treatment groups after KA injection. This result signifies the association of increased expression of NOS isoforms in increased NO production with cell damage following KA injection. It was also found that citicoline treatment decreased NOS expression, thereby providing protection against cell damage.

This study aimed to determine the degree of retinal damage associated with KA injection and the effects of citicoline on damaged rat retina by analyzing the morphological features of retinal cells after H&E staining and by assessing the expression of eNOS and nNOS using immunohistochemistry.

The intensity of eNOS immunoreactivity significantly increased in retinal blood vessels and ganglion cells after KA injection, but eNOS expression was decreased in citicoline-treated rats. Increased nNOS immunoreactivity was also detected in KA-induced retinal damage, and the administration of citicoline quenched nNOS activity. Morphometric analysis showed a significant reduction in INL and IPL thicknesses and GCL cell loss after KA injection, but the rate of thinning in retinal layers was reduced after citicoline treatment. These results indicate that citicoline exerts neuroprotective effects on KA-induced retinal damage.

## References

- Osborne NN, Schwarz M, Pergande G. Protection of rabbit retina from ischemic injury by flupirtine. *Invest Ophthalmol Vis Sci* 1996;37:274-80.
- Lam TT, Siew E, Chu R, Tso MO. Ameliorative effect of MK801 on retinal ischemia. *J Ocular Pharmacol Ther* 1997;13:129-37.
- Emery JM, Landis D, Paton D, et al. The lamina cribrosa in normal and glaucomatous human eyes. *Trans Am Acad Ophthalmol Otolaryngol* 1974;78:290-7.
- Quigley HA, Guy J, Anderson DR. Blockade of rapid axonal transport. Effect of intraocular pressure elevation in primate optic nerve. *Arch Ophthalmol* 1979;97:525-31.
- Yamamoto T, Kitazawa Y. Vascular pathogenesis of normal tension glaucoma: a possible pathogenetic factor, other than intraocular pressure, of glaucomatous optic neuropathy. *Prog Retin Eye Res* 1998;17:127-43.
- Hayreh SS, Podhajsky P, Zimmerman MB. Role of nocturnal arterial hypotension in optic nerve head ischemic disorders. *Ophthalmologica* 1999;213:76-96.
- Osborne NN, Melena J, Chidlow G, Wood JP. A hypothesis to explain ganglion cell death caused by vascular insults at the optic nerve head: possible implication for the treatment of glaucoma. *Br J Ophthalmol* 2001;85:1252-9.
- Dreyer EB. A proposed role for excitotoxicity in glaucoma. *J Glaucoma* 1998;7:62-7.
- Vorwerk CK, Gorla MS, Dreyer EB. An experimental basis for implicating excitotoxicity in glaucomatous optic neuropathy. *Surv Ophthalmol* 1999;43:142-50.
- Benveniste H, Drejer J, Schousboe A, Diemer NH. Elevation of the extracellular concentrations of glutamate and aspartate in rat hippocampus during transient cerebral ischemia monitored by intracerebral microdialysis. *J Neurochem* 1984;43:1369-74.
- Pellegrini-Giampietro DE, Cherici G, Alesiani M, et al. Excitatory amino acid release and free radical formation may cooperate in the genesis of ischemia-induced neuronal damage. *J Neurosci* 1990;10:1035-41.
- Neal MJ, Cunningham JR, Hutson PH, Hogg J. Effects of ischaemia on neurotransmitter release from the isolated retina. *J Neurochem* 1994;62:1025-33.
- Dreyer EB, Pan ZH, Storm S, Lipton SA. Greater sensitivity of larger retinal ganglion cells to NMDA-mediated cell death. *Neuroreport* 1994;5:629-31.
- Cazevielle C, Osborne NN. Retinal neurons containing kainate receptors are influenced by exogenous kainate and ischaemia while neurons lacking these receptors are not. Melatonin counteracts the effect of ischaemia and kainate. *Brain Res* 1997;755:91-100.
- Dutrait N, Culcasi M, Cazevielle C, et al. Calcium-dependent free radical generation in cultured retinal neurons injured by kainate. *Neurosci Lett* 1995;198:13-6.
- Nickells RW. Retinal ganglion cells death in glaucoma: the how, the why, and the maybe. *J Glaucoma* 1996;5:345-56.
- Snyder SH, Bredt DS. Biological roles of nitric oxide. *Sci Am* 1992;266:68-71,74-7.
- Bredt DS, Snyder SH. Transient nitric oxide synthase neurons in embryonic cerebral cortical plate, sensory ganglia, and olfactory epithelium. *Neuron* 1994;13:301-13.
- Bredt DS, Hwang PM, Snyder SH. Localization of nitric oxide synthase indicating a neural role for nitric oxide. *Nature* 1990;347:768-70.
- Alonso D, Serrano J, Rodriguez I, et al. Effects of oxygen and glucose deprivation on the expression and distribution of neuronal and inducible nitric oxide synthase and on protein nitration in rat cerebral cortex. *J comp Neurol* 2002;443:183-200.

21. Ju WK, Kim KY, Park SJ, et al. Nitric oxide is involved in sustained and delayed cell death of rat retina following transient ischemia. *Brain Res* 2000;881:231-6.
22. Hangai M, Yoshimura N, Hiroi K, et al. Inducible nitric oxide synthase in retinal ischemia-reperfusion injury. *Exp Eye Res* 1996;63:501-6.
23. Ostwald P, Goldstein IM, Pachanda A, Roth S. Effect of nitric oxide synthase inhibition on blood flow after retinal ischemia in cats. *Invest Ophthalmol Vis Sci* 1995;36:2396-403.
24. Adibhatla RM, Hatcher JF, Dempsey RJ. Citicoline: neuroprotective mechanisms in cerebral ischemia. *J Neurochem* 2002;80:12-23.
25. Grieb P, Rejdak R. Pharmacodynamics of citicoline relevant to the treatment of glaucoma. *J Neurosci Res* 2002;67:143-8.
26. Honjo M, Tanibara H, Kido N, et al. Expression of ciliary neurotrophic factor activated by retinal Muller cells in eyes with NMDA- and kainic acid-induced neuronal death. *Invest Ophthalmol Vis Sci* 2000;41:552-60.
27. Thompson CB. Apoptosis in the pathogenesis and treatment of disease. *Science* 1995;267:1456-62.
28. Kang JH, Park KH, Kim YJ, et al. The neuroprotective effect of Ginkgo on rat retinal ganglion cell in optic nerve crush injury model. *J Korean Ophthalmol Soc* 2003;44:965-70.
29. Cheon EW, Park CH, Kang SS, et al. Nitric oxide synthase expression in the transient ischemic rat retina. neuroprotection of betaxolol. *Neuroscience letters* 2002;330:265-9.
30. Yamauchi T, Kashii S, Yasuyoshi H, et al. Inhibition of glutamate-induced nitric oxide synthase activation by dopamine in cultured rat retinal neurons. *Neuroscience letters* 2003;347:155-8.
31. Delbarre G, Delbarre B, Calnon F, Ferger A. Accumulation of amino acids and hydroxyl free radicals in brain and retina of gerbil after transient ischemia. *J Ocul Pharmacol* 1991;1:147-55.
32. Perlman JI, McCole SM, Pulluru P, et al. Disturbance in the distribution of neurotransmitter in the rat retina after ischemia. *Curr Eye Res* 1996;15:589-96.
33. Lucas DR, Newhouse JP. The toxic effect of sodium L-glutamate on the inner layers of the retina. *Arch Ophthalmol* 1957;58:193-201.
34. Onley JW. Brain lesion, obesity and other disturbances in mice treated with monosodium glutamate. *Sciences* 1969;164:719-21.
35. Ehrlich D, Morgan IG. Kainic acid destroys displaced amacrine cells in post-hatch chicken retina. *Neurosci Lett* 1981;17:43-8.
36. Morgan IG, Ingham CA. Kainic acid affects both plexiform layers of chicken retina. *Neurosci Lett* 1981;21:275-80.
37. Siliprandi R, Canella R, Carmignoto G, et al. N-methyl D-aspartate induced neurotoxicity in the adult rat retina. *Vis Neurosci* 1992;8:567-73.
38. Campos EC, Schiavi C, Benedetti P, et al. Effect of citicoline on visual acuity in amblyopia: preliminary results. *Graefes Arch Clin Exp Ophthalmol* 1995;233:307-12.
39. Rejdak R, Toczolowski J, Solski J, et al. Citicoline treatment increases retinal dopamine content in rabbits. *Ophthalmic Res* 2002;34:146-9.
40. Choi JS, Gwag BJ, Kim SJ, Joo CK. Effect of MK801 and CNQX on retinal injury induced by ischemia, NMDA, or kainate. *J Korean Ophthalmol Soc* 1998;39:1794-800.
41. Megumi H, Hidenobu T, Noriaki K, et al. Expression of ciliary neurotrophic factor activated by retinal Muller cells in eyes with NMDA-and kainic acid-induced neuronal death. *Invest Ophthalmol Vis Sci* 2000;41:552-60.
42. Brandstatter JH, Koulen P, Wassle H. Diversity of glutamate receptors in the mammalian retina. *Vision Res* 1998;38:1385-97.
43. Iadecola C, Zhang F, Xu X. Role of nitric oxide synthase-containing vascular nerves in cerebrovasodilation elicited from cerebellum. *Am J Physiol* 1993;264:738-46.
44. Biliar TR. Nitric oxide: novel biology with clinical relevance. *Ann Surg* 1995;221:339-49.
45. Perez MT, Larsson B, Alm P, et al. Localization of neuronal nitric oxide synthase immunoreactivity in rat and rabbit retinas. *Exp Brain Res* 1995;104:207-17.
46. Haverkamp S, Kolb H, Cuenca N. Endothelial nitric oxide synthase (eNOS) is localized to Muller cells in all vertebrate retinas. *Vision Res* 1999;39:2299-303.
47. Yamamoto R, Brecht DS, Snyder SH, Stone RA. The localization of nitric oxide synthase in the rat eye and related cranial ganglia. *Neuroscience* 1993;54:189-200.
48. Vorwerk CK, Hyman BT, Miller JW, et al. The role of neuronal and endothelial nitric oxide synthase in retinal excitotoxicity. *Invest Ophthalmol Vis Sci* 1997;38:2038-44.