

Clinical Experiences of Unruptured Vertebral Artery Dissection

Ji Sang Kim, MD, Jin Hwan Cheong, MD, PhD, Sang Kook Lee, MD, PhD,
Jae Min Kim, MD, PhD and Choong Hyun Kim, MD, PhD

Department of Neurosurgery, Guri Hospital, College of Medicine, Hanyang University, Guri, Korea

Objective: The natural course of unruptured vertebral artery dissection remains unclear. The clinical manifestation of unruptured vertebral artery dissection varies from headache, focal neurologic deficits caused by ischemia to subarachnoid hemorrhage with high mortality. The purpose of this study is to investigate the clinical course of unruptured vertebral artery dissection.

Methods: From March 2011 to April 2013, 7 patients with headache or nuchal pain by spontaneous vertebral artery dissection visited our institute were retrospectively reviewed. Their clinical data was obtained by medical records and radiologic studies including computed tomographic angiography, magnetic resonance imaging, magnetic resonance angiography and digital subtraction angiography.

Results: No patient experienced fatal outcome by subarachnoid hemorrhage or vertebrobasilar ischemia during follow-up period. Radiologic studies also did not show the evidence of subarachnoid hemorrhage or vertebrobasilar ischemia. Follow-up angiography showed the decreased size or disappearance of aneurysm in 3 patients.

Conclusion: This study suggests that the natural course of unruptured vertebral artery dissection is not aggressive. Patients with unruptured vertebral artery dissection could be managed with conservative treatment including anticoagulants and/or antiplatelet agents.

(Korean J Neurotrauma 2013;9:69-73)

KEY WORDS: Vertebral artery dissection · Subarachnoid hemorrhage · Dissecting aneurysm.

Introduction

The annual incidence rate of spontaneous vertebral artery dissection (VAD) has been reported at about 1 to 1.5 per 100,000.³⁾ However, the natural history of spontaneous unruptured VAD is not completely understood.⁸⁾

The primary presentation of spontaneous unruptured VAD is severe headache only or focal neurologic deficits caused by vertebrobasilar artery ischemia.

Unruptured VAD tends not to follow an aggressive clinical course, and because the prognosis tends to be favorable, conservative treatment of these lesions has been advocated.^{5,9,11,14,17,20,24)}

However, if there is the event of aneurysmal rupture, it might lead to be fatal. Therefore, complete understanding

of mechanism and pathogenesis of VAD is needed, and patients with VAD need a careful follow-up.

In this retrospective review, we investigated the clinical outcomes of unruptured VAD and discuss strategies for their treatment with review of literatures.

Materials and Methods

Seven patients with headache or nuchal pain by unruptured VAD visited our institute between March 2011 and April 2013, were included in our investigation. Clinical data included chart of medical records and angiographic studies. Age, sex, past medical history of hypertension, related trauma history, the pattern of initial presentation, functional outcome were reviewed.

Either computed tomographic angiography (CTA) or vascular wall magnetic resonance angiography (MRA) was performed to identify double lumen or thrombus in the vessel at the initial diagnosis. All patients with unruptured VAD were followed up at the outpatient clinic. Radiologic studies including CTA, magnetic resonance imaging (MRI), MRA

Received: July 15, 2013 / **Revised:** October 7, 2013

Accepted: October 7, 2013

Address for correspondence: Jin Hwan Cheong, MD, PhD
Department of Neurosurgery, Guri Hospital, College of Medicine,
Hanyang University, 153 Gyeongchun-ro, Guri 471-701, Korea
Tel: +82-31-560-2324, Fax: +82-31-560-2327
E-mail: cjh2324@hanyang.ac.kr

or digital subtraction angiography were performed every 1 month to 6 months, those were mostly done with CTA.

Results

Of 7 patients with unruptured VAD, 3 were men and 4 were women. Mean age was 54.14 years (ranging from 33 to 75 years). Mean total follow-up period was 10.4 months (ranging from 1 month to 2 years). Table 1 shows the characteristics of the patients. Four patients had a history of preceding symptoms including headache after minor trauma, and the other 3 patients were detected spontaneously.

At the time of diagnosis, 5 VAD were categorized as distal vertebral artery dissection above the origin of posterior inferior cerebellar artery (PICA)(distal vertebral artery), 2 involving the PICA. No one had VAD below the origin of PICA (proximal vertebral artery).

In two patients, aneurysms showed getting smaller during follow-up period. One of them showed the complete disappearance of aneurysm. Another two patients showed unstable state of aneurysm due to change in shape during the follow-up period. They were evaluated more frequently using CTA, roughly weekly base. They were also managed with antihypertensive and analgesics medications. In one of them with unstable aneurysm, the aneurysmal size decreased in the last follow-up study. Others show no interval change of size or shape of aneurysm during the follow-up period.

No patient experienced neurological deterioration due to subarachnoid hemorrhage or vertebrobasilar ischemia during follow-up period.

Illustrated cases

Case 2

A 54-year-old woman visited outpatient clinic complaining intermittent headache after swimming 7 days ago. Neck CTA was taken to identify stenosis of carotid arteries and it showed a fusiform aneurysm at left V4 segment (Figure 1A). We followed up her monthly, the aneurysm disappeared completely after 4 months (Figure 1B). Finally, intermittent headache of the patient subsided in accordance with the disappearance of dissecting aneurysm.

Case 4

A 56-year-old male presented headache after a physical fight 10 days ago. He had a history of hypertension and heavy smoking. Brain CTA was taken in consideration of transient ischemic attack and it showed a fusiform aneurysm

TABLE 1. Clinical characteristics of the patients and location and shape of aneurysm

Case no.	Age	Sex	Presentation	Onset (days ago)	Cause	Location of aneurysm	Shape of aneurysm	Co-morbidity	SAH	F/U period (mos)
1	44	M	Headache	3	Sit up	Left V4 distal VA	Fusiform		-	6
2	54	F	Headache	7	Swimming	Left V4	Fusiform False lumen		-	8
3	38	M	Headache	7	Coitus	Left distal VA	Fusiform		-	24
4	56	M	Headache	10	Fight	Left distal VA	Globular to fusiform Circumferential enhanced-plaque	HT, smoking	-	22
5	74	F	Headache	2	Sudden attack	Left PICA	Saccular with daughter sac Wide neck		-	1
6	75	F	Nuchal pain	7	Sudden attack	Left proximal PICA	Dumbbell-shaped, bilobular		-	11
7	38	F	Headache	3	Sudden attack	Rt. V4	Fusiform		-	1

M: male, F: female, VA: vertebral artery, V4: V4 segment of vertebral artery, PICA: posterior inferior cerebellar artery, SAH: subarachnoid hemorrhage, HT: hypertension, mos: months

at left distal vertebral artery (Figure 2A). After 5 months from initial CTA, follow-up angiography showed an increase in size and a change in shape of the aneurysm from fusiform to globular (Figure 2B). The next follow-up angiography was done one month later, size of the aneurysm decreased and its shape also changed from globular to fusiform (Figure 2C). Two follow-up CTAs were done during 3 months thereafter, which showed no significant change of contour or size of aneurysm. In the next follow-up studies, 14 months and 22 months from the initial one, aneurysm became smaller gradually (Figure 2D).

Discussion

VAD is a relatively uncommon disease, however, its clinical course is known to be somewhat devastating, with estimated mortality to be 17–46%.^{1,12)} VAD can occur spontaneously or after blunt or penetrating trauma. Spontaneous VAD is the term used to describe vertebral dissections that do not involve blunt or penetrating trauma as a precipitating factor. Traumatic VAD means VAD due to major blunt or penetrating traumas like motor vehicle accidents, falls or penetrating injuries. Minor trauma also causes VAD. Mechanical stress to the arteries may be even caused by sudden head rotation in daily life.²⁾

The first type of VAD is partial thickness disruption. Dissections of vertebral arteries usually arise from an intimal tear. The internal elastic lamina is weakened and disrupted with aging and long-standing hemodynamic stress. The tear allows blood under arterial pressure to enter the wall of the artery and form an intramural hematoma. The intramural hematoma is located within the layers of the tunica media, but it may be eccentric, either toward the intima or toward adventitia. Most of this type showed tapered narrowing or double lumen, and presented as vertebrobasilar artery ischemia with a fair outcome. In this analysis, no patient showed the evidence of vertebrobasilar artery ischemia on radiologic evaluation.

The other type of VAD is full thickness disruption, the most common type. It shows a widespread disruption of the entire thickness of the arterial wall with the formation of a dilated pseudo-aneurysm, which consisted of thin adventitia. This type of VAD appeared as subarachnoid hemorrhage (SAH) and resulted in devastating disease with high mortality rates.⁸⁾

Most defects were located near the branching of the PICA 10 to 20 mm distal to the site of penetration of the dura mater, this may be related to the development of dissection at these site.

According to Kim et al.,⁸⁾ the shape of VAD was not considerably related to the functional outcome. There were 5 patients with fusiform aneurysm, 1 with saccular aneurysm, and 1 with dumbbell-shaped aneurysm in our analysis. All the patients had benign clinical outcomes. The shape of VAD was not significantly related to the outcome. Many studies suggested that shape of aneurysm is related to the risk of rupture, but those in VAD are few. More studies are needed to verify the relationship between shape of VAD and its risk.

Conventional angiography has long been the gold standard in the diagnosis of VAD, since it can show the arterial lumen and allows extensive characterization of dissections of vertebral arteries. In our analysis, not all patients were

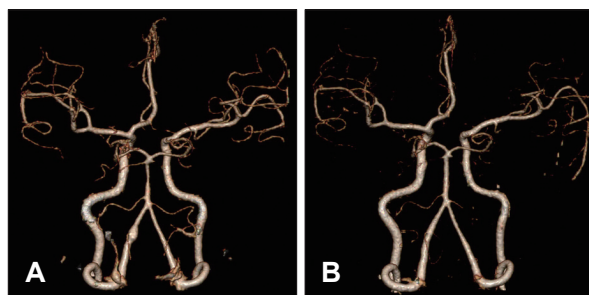


FIGURE 1. Case 2. A 54-year-old woman with intermittent headache after swimming. A: Initial CTA showing fusiform aneurysm at left V4 segment. B: After 4 months, the aneurysm disappeared completely. CTA: computed tomographic angiography.

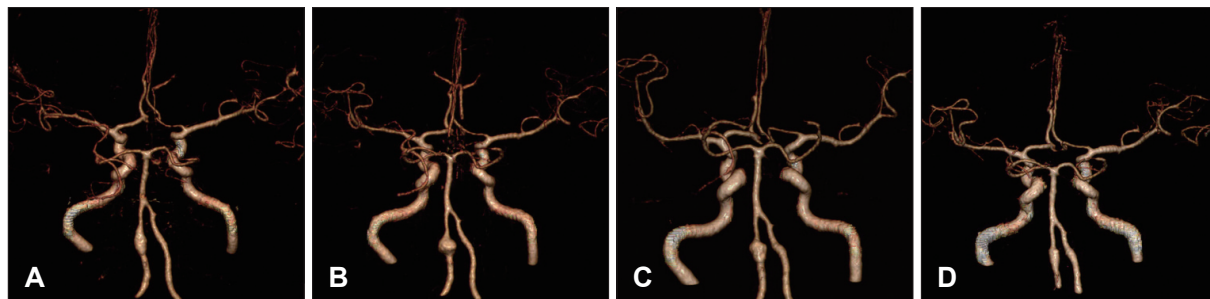

FIGURE 2. Case 4. A 56-year-old male with headache after a physical fight. A: Initial CTA showing fusiform aneurysm at left distal vertebral artery. B: After 5 months, increase in size and change in shape of the aneurysm from fusiform to globular. C: One month later, size of the aneurysm decreased reversely and its shape changed from globular to fusiform. D: The recent CTA, aneurysm became smaller. CTA: computed tomographic angiography.

diagnosed with conventional angiography. Conventional angiography was done at initial presentation only in 3 cases of acute onset. But vascular wall MRI was used to diagnose in all patients. The diagnosis of dissecting aneurysm has been discussed by many authors based on angiographic findings such as “pearl and string” sign,^{12,16,22)} fusiform,^{3,19)} linear defect,⁴⁾ true and false lumen (double lumen),⁶⁾ and retention of the contrast medium in the venous phase.¹⁰⁾

Some authors reported the interval between onset of preceding symptoms and bleeding episode.^{7,11,13,15,21,22)} Those studies suggest that if 4 or more days pass without bleeding episodes, the prognosis of patient with unruptured VAD may be good. In our analysis, most patients visited our institute after the acute stage. Because initial angiography was performed at least several days after the onset of the preceding symptoms, most of the VADs that were unruptured at diagnosis already had little risk for bleeding.

There were several debates for the treatment and prognosis of unruptured VAD, and their optimal treatment has not been established. The most important factor for treatment and prognosis was the clinical presentation of the patients,^{9,12,14,17,19,21,23,24)} SAH versus non-SAH. Therefore the treatment should be adapted to the patient's clinical presentation. The VAD patients with SAH should have surgical or endovascular treatment immediately. Some studies showed that VAD patients with SAH had a high rebleeding and high mortality rate.^{12,18)} But those without SAH, could be managed conservatively with antiplatelet therapy and/or anticoagulation. Also, they tend to follow a benign clinical course.

One of the limitations of this study is small number of patient and short term of follow-up period. Another limitation is that it was a retrospective analysis performed at a single center. Finally, there was no control group of unruptured VAD patients with surgical or endovascular treatment. A control group consisting of ruptured VAD patients with conservative treatment could have also been included as well.

Conclusion

Unruptured VAD are not usually aggressive. VAD patients without SAH could be managed conservatively to prevent ischemia, and serial follow-up angiography is needed.

■ The authors have no financial conflicts of interest.

REFERENCES

- 1) Aoki N, Sakai T. Rebleeding from intracranial dissecting aneurysm in the vertebral artery. *Stroke* 21:1628-1631, 1990
- 2) Auer RN, Krcek J, Butt JC. Delayed symptoms and death after minor head trauma with occult vertebral artery injury. *J Neurol Neurosurg Psychiatry* 57:500-502, 1994
- 3) Broom ND, Ramsey G, Mackie R, Martin BJ, Stehbins WE. A new biomechanical approach to assessing the fragility of the internal elastic lamina of the arterial wall. *Connect Tissue Res* 30: 143-155, 1993
- 4) Hayes WT, Bernhardt H, Young JM. Fusiform arteriosclerotic aneurysm of the basilar artery. Five cases including two ruptures. *Vasc Surg* 1:171-178, 1967
- 5) Hosoya T, Adachi M, Yamaguchi K, Haku T, Kayama T, Kato T. Clinical and neuroradiological features of intracranial vertebro-basilar artery dissection. *Stroke* 30:1083-1090, 1999
- 6) Ishikawa T, Nakamura N, Houkin K, Nomura M. Pathological consideration of a “blister-like” aneurysm at the superior wall of the internal carotid artery: case report. *Neurosurgery* 40:403-405; discussion 405-406, 1997
- 7) Kai Y, Nishi T, Watanabe M, Morioka M, Hirano T, Yano S, et al. Strategy for treating unruptured vertebral artery dissecting aneurysms. *Neurosurgery* 69:1085-1091; discussion 1091-1092, 2011
- 8) Kim CH, Son YJ, Paek SH, Han MH, Kim JE, Chung YS, et al. Clinical analysis of vertebrobasilar dissection. *Acta Neurochir (Wien)* 148:395-404, 2006
- 9) Kitanaka C, Tanaka J, Kuwahara M, Teraoka A, Sasaki T, Takakura K, et al. Nonsurgical treatment of unruptured intracranial vertebral artery dissection with serial follow-up angiography. *J Neurosurg* 80:667-674, 1994
- 10) Masawa N, Glagov S, Zarins CK. Quantitative morphologic study of intimal thickening at the human carotid bifurcation: II. The compensatory enlargement response and the role of the intima in tensile support. *Atherosclerosis* 107:147-155, 1994
- 11) Mizutani T. Natural course of intracranial arterial dissections. *J Neurosurg* 114:1037-1044, 2011
- 12) Mizutani T, Aruga T, Kirino T, Miki Y, Saito I, Tsuchida T. Recurrent subarachnoid hemorrhage from untreated ruptured vertebro-basilar dissecting aneurysms. *Neurosurgery* 36:905-911; discussion 912-913, 1995
- 13) Mizutani T, Kojima H, Asamoto S. Healing process for cerebral dissecting aneurysms presenting with subarachnoid hemorrhage. *Neurosurgery* 54:342-347; discussion 347-348, 2004
- 14) Mokri B, Houser OW, Sandok BA, Piepgras DG. Spontaneous dissections of the vertebral arteries. *Neurology* 38:880-885, 1988
- 15) Naito I, Iwai T, Sasaki T. Management of intracranial vertebral artery dissections initially presenting without subarachnoid hemorrhage. *Neurosurgery* 51:930-937; discussion 937-938, 2002
- 16) Nass R, Hays A, Chutorian A. Intracranial dissecting aneurysms in childhood. *Stroke* 13:204-207, 1982
- 17) Pozzati E, Padovani R, Fabrizi A, Sabbatini L, Gaist G. Benign arterial dissections of the posterior circulation. *J Neurosurg* 75:69-72, 1991
- 18) Ramgren B, Cronqvist M, Romner B, Brandt L, Holtås S, Larsson EM. Vertebrobasilar dissection with subarachnoid hemorrhage: a retrospective study of 29 patients. *Neuroradiology* 47:97-104, 2005
- 19) Sakata N, Takebayashi S, Kojima M, Masawa N, Suzuki K, Takatama M, et al. Different roles of arteriosclerosis in the rupture of intracranial dissecting aneurysms. *Histopathology* 38:325-337, 2001
- 20) Sasaki O, Ogawa H, Koike T, Koizumi T, Tanaka R. A clinicopathological study of dissecting aneurysms of the intracranial vertebral artery. *J Neurosurg* 75:874-882, 1991
- 21) Schievink WI. Spontaneous dissection of the carotid and vertebral arteries. *N Engl J Med* 344:898-906, 2001
- 22) Tsutsumi M, Kawano T, Kawaguchi T, Kaneko Y, Ooigawa H. Dissecting aneurysm of the vertebral artery causing subarachnoid hemorrhage after non-hemorrhagic infarction--case report. *Neurol Med Chir (Tokyo)* 40:628-631, 2000

- 23) Willis BK, Greiner F, Orrison WW, Benzel EC. The incidence of vertebral artery injury after midcervical spine fracture or subluxation. **Neurosurgery** 34:435-441; discussion 441-442, 1994
- 24) Yoshimoto Y, Wakai S. Unruptured intracranial vertebral artery dissection. Clinical course and serial radiographic imagings. **Stroke** 28:370-374, 1997