

Results of Combined 360-Degree Fusion versus Posterior Fixation Alone for Thoracolumbar Burst Fractures

Eui-Gyu Sin, MD, Hyun-Woo Kim, MD, Cheol-Young Lee, MD,
Ho-Gyun Ha, MD and Chul-Ku Jung, MD

Department of Neurosurgery, Konyang University Hospital, Daejeon, Korea

Objectives: To identify the better option of treatment, we compared the surgical results and efficacy of combined anterior-posterior approach versus posterior fixation alone.

Methods: During a 10 years period from 2002 to 2011, 111 patients with thoracolumbar burst fracture was surgically managed at our institute. 25 patients were managed by a combined anterior-posterior surgery and 86 patients were managed by posterior fusion alone. Radiographs were repeated at 3, 6, 12 and 24 months after operation. Radiologic outcome was evaluated by measuring Kyphotic angulation and vertebral height and the clinical outcome was evaluated by visual analogue scale (VAS) score comparison.

Results: The average Cobb's angle difference between immediate post operative and last follow up was 15.0° in combined 360-degree fusion group and 7.5° in posterior surgery alone group. A corrections of vertebral body height between immediate post operative and last follow up was 2.27 mm in 360-degree fusion group while 0.59 mm in posterior fixation group. The VAS score decreased from 8.4 to 2.2 after post operation 24 months in 360-degree fusion group and the posterior surgery alone group decreased 9.3 to 6.2 after post operation 24 months.

Conclusion: The combined anterior-posterior approach resulted in less deterioration of the kyphotic angle postoperatively and improvement of vertebral height (sagittal index). Clinical outcome was also better in the combined group.

(Korean J Neurotrauma 2013;9:52-56)

KEY WORDS: Burst fracture · Thoracolumbar · Circumferential fusion · Posterior fixation.

Introduction

The optimal management of thoracolumbar fractures remains a matter of debates. A variety of treatment options is both available and effective, but none has been definitively proven superior. Especially in cases of anterior column involvement, the questions of how these fractures should be approached and stabilized remains unanswered. Many authors have advocated conservative managements^{5,8,19-21,23} especially in stable fractures without neurological injury. But the risk of delayed neurological deterioration or the development of painful kyphosis are not well defined. Denis

et al.¹¹) reported 17% neurological complications and 17% severe kyphosis after nonoperative treatment.

Decompression and stabilization surgeries can be performed anterolaterally or posteriorly. When the posterior route is used, access to the canal is gained by laminectomy or facetectomy. Posterior stabilization generally requires longer segment fixations which are placed more than two levels above and below the site of injury.^{18,22} The anterolateral retroperitoneal approach allows the surgeons to perform corpectomy and fusion, reconstructing the anterior and middle column of the spine. And both the anterolateral and the posterior approaches have been associated with favorable result.^{18,22}

Here we present result of two groups of patients in whom a staged posterior fusion following anterolateral fusion and posterior fixation only for unstable thoracolumbar burst fractures during follow up periods.

Received: March 27, 2013 / **Revised:** May 20, 2013

Accepted: May 20, 2013

Address for correspondence: Hyun-Woo Kim, MD

Department of Neurosurgery, Konyang University Hospital, 158 Gwanjeodong-ro, Seo-gu, Daejeon 302-718, Korea

Tel: +82-42-600-9130, Fax: +82-42-600-8983

E-mail: naturalspine@gmail.com

Materials and Methods

Patient population

During 10 years period from 2002 to 2011, 111 patients with thoracolumbar burst fracture was surgically managed at our institute.

Twenty-five patients were managed by a combined anterior-posterior fusion (360-degree fusion) and 86 patients were managed by posterior fixation alone.

Indications for 360-degree fusion were loss of vertebral

TABLE 1. Characteristics of the patients in the 360-degree fusion groups and posterior fixation group

	Group A (n=25)	Group B (n=86)
Age (years)	49.2 ± 10.8	48.5 ± 14.5
Male : Female ratio	17 : 8	28 : 15
Follow up (month)	31.7 ± 17.0	30.2 ± 5.4
Fracture level		
T12	9	21
L1	14	40
L2	2	15
Others	0	10
Cause of injury		
Fall down	15	51
Traffic accidents	9	32
Others	1	3
TLICS score (mean)	9	7

Group A was 360-degree fusion group and group B was posterior fixation group. TLICS: ThoracoLumbar Injury Classification and Severity

TABLE 2. ThoracoLumbar Injury Classification and Severity (TLICS) Score*

Parameter	Points
Morphology	
Compression fracture	1
Burst fracture	2
Translational/rotational	3
Distraction	4
Neurologic involvement	
Intact	0
Nerve root	2
Cord or conus medullaris	
Incomplete	3
Complete	2
Cauda equina	3
Posterior ligamentous complex	
Intact	0
Injury suspected/indeterminate	2
Injured	3

*Rihn JA, Anderson DT, Harris E, Lawrence J, Jonsson H, Wilsey J, et al.: A review of the TLICS system: a novel, user-friendly thoracolumbar trauma classification system. *Acta Orthop* 79:461-466, 2008

body height by more than 50%, severe compromise of the spinal canal, and instability such as three column injury and fracture dislocation with or without neurological deficits. The other patients were treated with only posterior pedicle screw fixation with or without posterior decompression. The patients' demographics are summarized in Table 1 and 2.

Pain scale and radiographic analysis

All patients were questioned their pain scales using visual analogue scale (VAS) at a regular follow up day. On admission, all patients underwent plain (anterior-posterior and lateral) supine radiographs in CT and MR imaging. Kyphotic angulation was determined by evaluating lateral radiographs on which we measured the angle of intersection of the adjacent intact endplates rostral and caudal to the fracture (Cobb's method). Interbody height was measured between the anterior-superior endplate of the lower non-injured vertebra and the anterior-inferior endplate of the upper non-injured vertebra. Postoperative spinal alignment, hardware position and the presence of a fusion mass were evaluated on AP and lateral radiographs.

Operative technique

In 360-degree fusion group, staged operation were performed by posterior fusion with or without decompressive laminectomy followed by anterolateral fusion using expandable cage after corpectomy. Posterior fixation was performed first because of the useful kyphotic correction at the prone position that maintained stabilization and decompression of the spinal canal by laminectomy simultaneously. One week later, we did anterolateral fusion. An extra-pleural and retroperitoneal approach with removal of the left tenth or eleventh rib was used to expose the thoracolumbar junctions. The twelfth rib was not removed from most patients because it is too small to obscure the operative field. The intervertebral discs cephalad and caudad to the injured level were almost completely excised, leaving the anterior longitudinal ligament intact. The displaced fragments of the vertebral body in the spinal canal were removed from the anterior aspect of the posterior longitudinal ligament with using a long sharp curettes, high speed drill, and punch. We placed the Synex expandable cage (Synthes Ltd., Mississauga, ON) in distractive corpectomy space (Figure 1).

Follow up data

Follow up examinations, including standing or upright AP and lateral radiography, were scheduled at 3, 6, 12 and

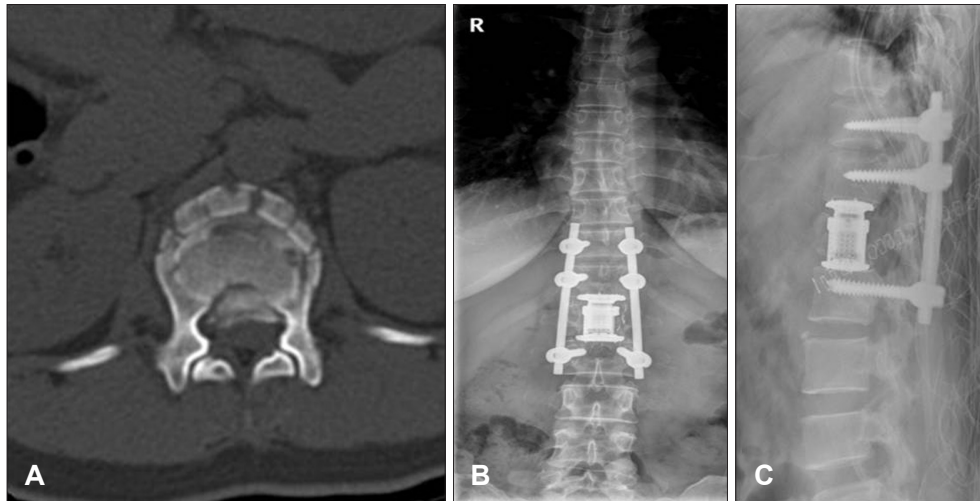


FIGURE 1. A case of thoracolumbar vertebral fracture managed by 360-degree fusion. A: Axial computed tomography scan image of a fractured spine. Bilateral pedicles and facet joints were resected and a cage was inserted. B and C: Plain radiograph showing cage insertion and transpedicular screw fixation.

TABLE 3. Summary of corrections for kyphotic angle and interbody height during follow up

	Group A	Group B	p value
Kyphotic angle (°)			
Intraoperative correction	16.9±5.25	12.4±7.58	<0.05
Pre OP-last F/U (final angle correction)	15.0±2.28	7.5±6.56	<0.05
Last F/U-Post OP (maintenance of angle)	1.9±1.26	4.9±4.33	<0.05
Interbody height (mm)			
Intraoperative correction	8.15±4.22	3.89±2.65	<0.05
Last F/U-pre OP (final height correction)	2.27±3.29	0.59±4.33	<0.05
Post OP-last F/U (maintenance of height)	3.33±4.56	3.15±5.27	0.345

*group A was 360-degree fusion group and group B was posterior fixation group. OP: operation, F/U: follow up

24 months and annually thereafter.

Statistical analysis

Data were analyzed using analysis of variance, the Wilcoxon test, and the Fisher exact test. Data were presented as mean±standard deviation (SD). Significance was accepted at a probability value of less than or equal to 0.05. The SPSS v.17.0 (SPP Inc., Chicago, IL) statistical package was used for all calculations.

Results

Patient population

There were no significant differences between the two groups with respect to age, sex, duration of follow up and fractured level.

Radiologic outcomes

Kyphotic angle

After the operation, in 360-degree group (Group A), in-

traoperative correction as determined by comparison with the kyphotic angle before the operation was 16.9±5.25° while posterior fixation group (Group B) was 12.4±7.58°. In addition, there was 15.0±2.28° of kyphotic angle correction at final follow up, as determined by comparison with the kyphotic angle before the operation in group A, while 7.5±6.56° in group B. Between group A and B, there were a statistically significant differences in the degree of kyphotic angle correction at intraoperative and final follow up ($p<0.05$). In addition, there were changes of kyphotic angle, including 1.9±1.26° in group A, 4.9±4.33° in group B between the surgery and last follow up. These results are summarized in Table 3.

Vertebral body height

In group A, intraoperative correction of vertebral body height was 8.15±4.22 mm and in group B, it was 3.89±2.65 mm. In addition, at the final follow up, group A has 2.27±3.29 mm of correction in body height as compared with the interbody height before the operation but in group B has 0.59±4.33 mm interbody correction. There was a sta-

tistically significant difference between the two groups in terms of the correction as compared with the preoperative result ($p < 0.05$). These results are summarized in Table 2.

Fusion level

As for posterior pedicle screw fixation, mean fixation level was 2.3 in group A, and 4.3 in group B ($p < 0.05$).

Clinical outcomes

Postoperative pain

Patients' VAS score was highest at preoperative period (on admission) in both groups and it decreased gradually. After 3 months surgery, VAS score of group A was less than group B statistically significantly (4.36 vs. 7.55, $p < 0.05$), and it last at the final follow up (2.24 vs. 6.23). These results are summarized in Figure 2.

Complications

There was no case of mechanical failure fracture, or dislocation of the 360-degree fusion using combined anterior and posterior stabilization. But there was 2 case of screw dislocation at post operative follow up periods (12 month) in posterior fixation (group B). There was 1 case of pneumonia in a critically ill patient whose mobilization was impaired by associated with multiple rib fractures and severe lung contusion in 360-degree fusion group (group A). In group B, four patients were having neurologic deterioration and progressive kyphosis, so they had an operation for anterior fusion almost 12 months after posterior fixation.

Discussion

Burst fracture of the thoracolumbar spine may cause instability and deformity of the spine as well as neurologic damage.¹²⁾ The extent of instability is determined by identification of the fracture pattern according to any number of classification, all of which describe trauma to two or three of the columns as defined by Denis.¹²⁾ Historically, a posterior approach with or without decompression along with placement of intersegmental instrumentation has been much more popular than either an anterior approach or combined anterior-posterior approach.^{10,25)} Those who support posterior instrumentation with or without transpedicular decompression cite excellent results in spinal stability, anatomical alignment, postoperative neurologic improvement, and low patient morbidity.^{1,7,9,13-15,17)} Today, controversy still surrounds the approach for decompression of an unstable thoracolumbar burst fracture.

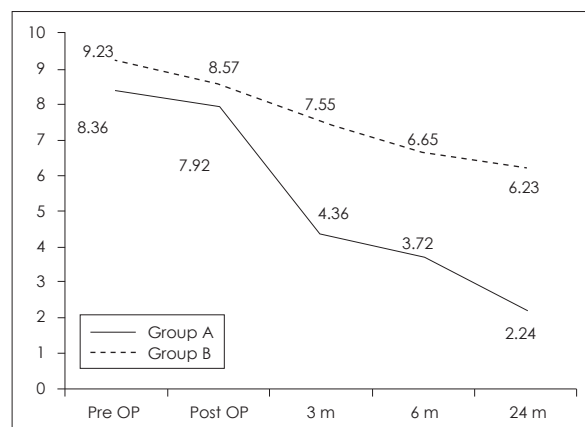


FIGURE 2. Graph showing VAS score at admission, immediate post operation and 3, 6, 24 month after surgery. Group A was 360-degree fusion group and group B was posterior fixation group. VAS: visual analogue scale.

The posterior approach has been attractive due to the familiar anatomy and approach. This method can be performed in a timely fashion without the assistance of a general or vascular surgeon, and its use helps avoiding thoracotomy associated complications such as iatrogenic vascular, bowel, or pulmonary injuries.²⁴⁾ We think that the success of this technique for achieving deformity reduction depends on the presence of an intact posterior longitudinal ligament and annulus fibrosus of the intervertebral disc.

Direct canal decompression can be achieved using an anterior procedure. One benefit of the anterior approach is that it permits more direct and complete decompression of the spinal canal, potentially resulting in better neurological outcomes. Esses et al.¹⁶⁾ reported a prospective randomized study of 40 patients who underwent either anterior decompression or posterior transpedicular distraction. They found no intergroup differences with respect to Frankel grade improvement or kyphosis correction, although canal decompression was substantially greater after completion of the anterior operation.

Anterior decompression and instrumentation augmented fusion for thoraco-lumbar fractures can be effectively restore vertebral body height and correct the kyphotic deformity. Briem et al.⁶⁾ observed a loss in vertebral body height only in posterior stabilization group. In our study, the progression of kyphotic deformity and loss of vertebral body height after the surgery is more in posterior fixation group than 360-degree fusion group. It is noteworthy feature that maintenance of vertebral alignment in 360-degree fusion is superior than posterior fixation. Also anterior column support can negate the need for long segment fixation.²⁶⁾ Our data showed a statistically significant reduction of fusion level in 360-degree fusion group than posterior

fixation only group.

Use of posterior instrumentation alone results in a respectively high risk of failure, instability, or correction loss.^{3,4,18)} In 1 series of 70 patients with thoracic and lumbar fractures, 25% of the screws adjacent to the fracture bent or broke, while the hardware was removed from 4 patients as a result of pain or it becoming prominent.²²⁾ Our series showed similar outcome that group for 360-degree fusion had no mechanical failure while 3 patients had loosening or displacement of screws in posterior fixation. Been and Bouma²⁾ reported the results of combined anterior and posterior stabilization surgery for unstable thoracolumbar burst fractures. The improvement of the kyphotic correction between the combined AP approach ($3.3 \pm 7.7^\circ$) and the posterior fusion only ($4.1 \pm 12.4^\circ$) approach was significantly greater in the combined surgery.

Use of 360-degree fusion and posterior fusion combined with anterolateral fusion for unstable thoracolumbar burst fractures has many benefits, including kyphosis correction, canal decompression, and spinal stabilization. But in our series, these approaches also have the risk. Many postoperative complications such as infection, hypovolemic shock, and other medical problems might be avoided.

Conclusion

In the present study, staged 360-degree fusion is favorable approach than posterior fixation in terms of kyphotic angle correction, interbody height, fusion level and postoperative pain for thoracolumbar burst fractures.

■ The authors have no financial conflicts of interest.

REFERENCES

- 1) Aebi M, Etter C, Kehl T, Thalgot J. Stabilization of the lower thoracic and lumbar spine with the internal spinal skeletal fixation system. Indications, techniques, and first results of treatment. *Spine (Phila Pa 1976)* 12:544-551, 1987
- 2) Been HD, Bouma GJ. Comparison of two types of surgery for thoraco-lumbar burst fractures: combined anterior and posterior stabilisation vs. posterior instrumentation only. *Acta Neurochir (Wien)* 141:349-357, 1999
- 3) Been HD. Anterior decompression and stabilization of thoracolumbar burst fractures by the use of the Slot-Zielke device. *Spine (Phila Pa 1976)* 16:70-77, 1991
- 4) Benzel EC. Short-segment compression instrumentation for selected thoracic and lumbar spine fractures: the short-rod/two-claw technique. *J Neurosurg* 79:335-340, 1993
- 5) Braakman R, Fontijne WP, Zeegers R, Steenbeek JR, Tanghe HL. Neurological deficit in injuries of the thoracic and lumbar spine. A consecutive series of 70 patients. *Acta Neurochir (Wien)* 111:11-17, 1991
- 6) Briem D, Lehmann W, Ruecker AH, Windolf J, Rueger JM, Linhart W. Factors influencing the quality of life after burst fractures of the thoracolumbar transition. *Arch Orthop Trauma Surg* 124:461-468, 2004
- 7) Carl AL, Tromanhauser SG, Roger DJ. Pedicle screw instrumentation for thoracolumbar burst fractures and fracture-dislocations. *Spine (Phila Pa 1976)* 17(8 Suppl):S317-S324, 1992
- 8) Chan DP, Seng NK, Kaan KT. Nonoperative treatment in burst fractures of the lumbar spine (L2-L5) without neurologic deficits. *Spine (Phila Pa 1976)* 18:320-325, 1993
- 9) Cotler JM, Vernace JV, Michalski JA. The use of Harrington rods in thoracolumbar fractures. *Orthop Clin North Am* 17:87-103, 1986
- 10) Danisa OA, Shaffrey CI, Jane JA, Whitehill R, Wang GJ, Szabo TA, et al. Surgical approaches for the correction of unstable thoracolumbar burst fractures: a retrospective analysis of treatment outcomes. *J Neurosurg* 83:977-983, 1995
- 11) Denis F, Armstrong GW, Searls K, Matta L. Acute thoracolumbar burst fractures in the absence of neurologic deficit. A comparison between operative and nonoperative treatment. *Clin Orthop Relat Res*:142-149, 1984
- 12) Denis F. Spinal instability as defined by the three-column spine concept in acute spinal trauma. *Clin Orthop Relat Res*:65-76, 1984
- 13) Dick W. The "fixateur interne" as a versatile implant for spine surgery. *Spine (Phila Pa 1976)* 12:882-900, 1987
- 14) Dickson JH, Harrington PR, Erwin WD. Results of reduction and stabilization of the severely fractured thoracic and lumbar spine. *J Bone Joint Surg Am* 60:799-805, 1978
- 15) Edwards CC, Levine AM. Early rod-sleeve stabilization of the injured thoracic and lumbar spine. *Orthop Clin North Am* 17:121-145, 1986
- 16) Esses SI, Botsford DJ, Kostuik JP. Evaluation of surgical treatment for burst fractures. *Spine (Phila Pa 1976)* 15:667-673, 1990
- 17) Hardaker WT Jr, Cook WA Jr, Friedman AH, Fitch RD. Bilateral transpedicular decompression and Harrington rod stabilization in the management of severe thoracolumbar burst fractures. *Spine (Phila Pa 1976)* 17:162-171, 1992
- 18) Hitchon PW, Torner J, Eichholz KM, Beeler SN. Comparison of anterolateral and posterior approaches in the management of thoracolumbar burst fractures. *J Neurosurg Spine* 5:117-125, 2006
- 19) James KS, Wenger KH, Schlegel JD, Dunn HK. Biomechanical evaluation of the stability of thoracolumbar burst fractures. *Spine (Phila Pa 1976)* 19:1731-1740, 1994
- 20) Kinoshita H, Nagata Y, Ueda H, Kishi K. Conservative treatment of burst fractures of the thoracolumbar and lumbar spine. *Paraplegia* 31:58-67, 1993
- 21) Knight RQ, Stornelli DP, Chan DP, Devanny JR, Jackson KV. Comparison of operative versus nonoperative treatment of lumbar burst fractures. *Clin Orthop Relat Res*:112-121, 1993
- 22) McLain RF. Functional outcomes after surgery for spinal fractures: return to work and activity. *Spine (Phila Pa 1976)* 29:470-477; discussion Z6, 2004
- 23) Mumford J, Weinstein JN, Spratt KF, Goel VK. Thoracolumbar burst fractures. The clinical efficacy and outcome of nonoperative management. *Spine (Phila Pa 1976)* 18:955-970, 1993
- 24) Oskouian RJ Jr, Shaffrey CI, Whitehill R, Sansur CA, Pouratian N, Kanter AS, et al. Anterior stabilization of three-column thoracolumbar spinal trauma. *J Neurosurg Spine* 5:18-25, 2006
- 25) Sasso RC, Cotler HB. Posterior instrumentation and fusion for unstable fractures and fracture-dislocations of the thoracic and lumbar spine. A comparative study of three fixation devices in 70 patients. *Spine (Phila Pa 1976)* 18:450-460, 1993
- 26) Tezeren G, Kuru I. Posterior fixation of thoracolumbar burst fracture: short-segment pedicle fixation versus long-segment instrumentation. *J Spinal Disord Tech* 18:485-488, 2005