

Delayed Meningitis Complicated by the Frontal Sinus Opening to the Dura Mater in a Patient with Intracranial Injury Fifteen Years Ago

Jaesik Shin, MD, Sunghan Oh, MD, Bongsub Chung, MD,
Jongkook Rhim, MD, Chungjae Lee, MD and Jongwon Choi, MD

Department of Neurosurgery, Bundang Jesaeng General Hospital, Seongnam, Korea

Meningitis is the inflammation of the membranes of the brain and spinal cord. This disease is considered life threatening and classified as a medical and emergency. Here we report a case of delayed meningitis occurred in a patient with craniotomy for traumatic brain injury fifteen years ago. Meanwhile, he had been well, however he complained of headache for five days. A brain computed tomographic scan showed air density on the frontal lobe with frontal sinus defect and pansinusitis. His mental state was suddenly changed to stuporous, despite a day of empirical antibiotics. Therefore, a successful cranialization was performed and he was gradually improved. This is a rare case report. Our case shows that surgical intervention is to be considered in some cases of posttraumatic meningitis for effective and rapid control of infection.

(Korean J Neurotrauma 2013;9:142-145)

KEY WORDS: Basal skull fracture · Cranialization · Meningitis.

Introduction

Post-traumatic meningitis may occur in moderate to severe head injuries.²⁾ It generally occurs within two weeks after traumatic event.¹⁶⁾ Seventy five percent of cases have demonstrable basal skull fracture, and fifty eight percent had obvious cerebrospinal fluid (CSF) rhinorrhea. As expected from above, there is a high rate of infection with organisms indigenous to the nasal cavity. All the accessory sinuses of the nose on one or both sides, pansinusitis and even death may also be possible in such cases. We present one case of posttraumatic meningitis occurred 15 years after trauma, in which surgical intervention is helpful for rapid control of infection and good recovery.

Case Report

A thirty-year-old male patient was admitted with fever and headache. On past history, he underwent craniotomy due to traumatic intracerebral hemorrhage fifteen years ago at a regional hospital. On neurologic examination, he did not show any neurological deficit. His body temperature was 38.6°C. On laboratory evaluation, initial white blood cell (WBC) count was checked 19600/mm³. The erythrocyte sedimentation rate and C-reactive protein were checked 26 mm/h and 6.57 mg/dL, respectively. CSF examination was compatible with bacterial meningitis as follows; red blood cells count was 960/uL, WBC 5120/uL, Glucose 30 mg/dL, Protein 198 mg/dL, and pH 8.0. A brain CT scans showed air density with cerebromalacic change on the left frontal lobe with frontal sinus defect and pansinusitis (Figure 1). The patient was managed with third-generation cephalosporin. Notwithstanding the use of antibiotics, suddenly his mental state was changed to stuporous with high fever on second hospital day. Follow-up brain CT showed no definite change. It was decided to perform a surgery for persistent fever and altered mentality due to posttraumatic meningitis. The patient underwent cranialization on the second

Received: September 15, 2013 / **Revised:** October 7, 2013

Accepted: October 7, 2013

Address for correspondence: Sunghan Oh, MD

Department of Neurosurgery, Bundang Jesaeng General Hospital,
20 Seohyeon-ro 180beon-gil, Bundang-gu, Seongnam 463-774,
Korea

Tel: +82-31-779-0285, Fax: +82-31-779-0895

E-mail: swalme@hanmail.net

hospital day (Figure 2). There was abscess pocket with pus in the frontal sinus. It was connected into frontal lobe through defect in dura. Pathologic specimen obtained from the abscess revealed chronic active inflammation, marked with granulation tissue (Figure 3). Many *Streptococcus pneumoniae* were cultured from the pus. Four days after the operation and medication, his mental status was recovered to alert. The patient's antibiotics was used for 4 weeks. He left hospital with sufficient management on 35th hospital day. At this point in time, seventeen months passed, he is very well.

Discussion

Meningitis is an infection of the meninges (coverings) of

the brain and spinal cord. Bacterial meningitis is dangerous with high risk of complications, even death. This illness may start like a cold or flu-like symptom, and then might show full blown feature of meningitis.

The etiology of meningitis is various. Among them, post-traumatic meningitis occurs in 1–20% of patients with moderate to severe head injuries.²⁾ The onset of meningitis occurs within two weeks in about fifty percent, but within 1 year after trauma in twenty five percent.¹⁶⁾ Although the longest interval was reported in thirty five years after the trauma, it rarely occurs over ten years after the trauma.¹⁶⁾ Characteristics of initial head trauma, location of skull fracture, dural defect, complications of trauma is correlated with post-

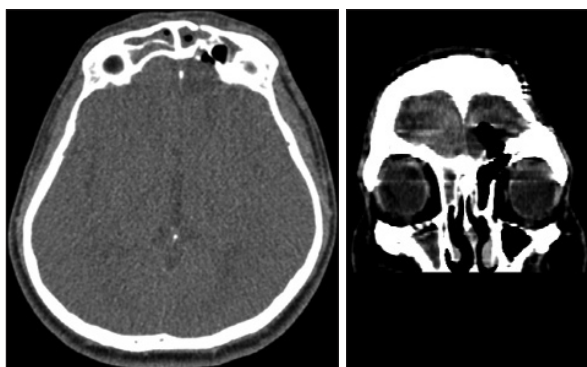


FIGURE 1. Axial and coronal brain CT scan showing pneumocephalus with frontal sinus opening to the left frontal lobe.

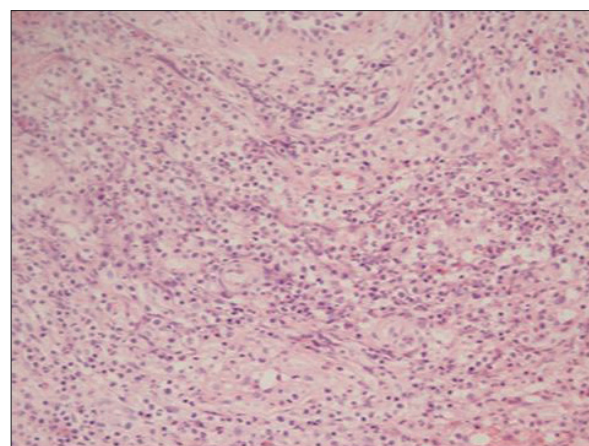


FIGURE 3. The high power microscopic finding demonstrating abscess formation, predominantly neutrophils (H&E, ×200).

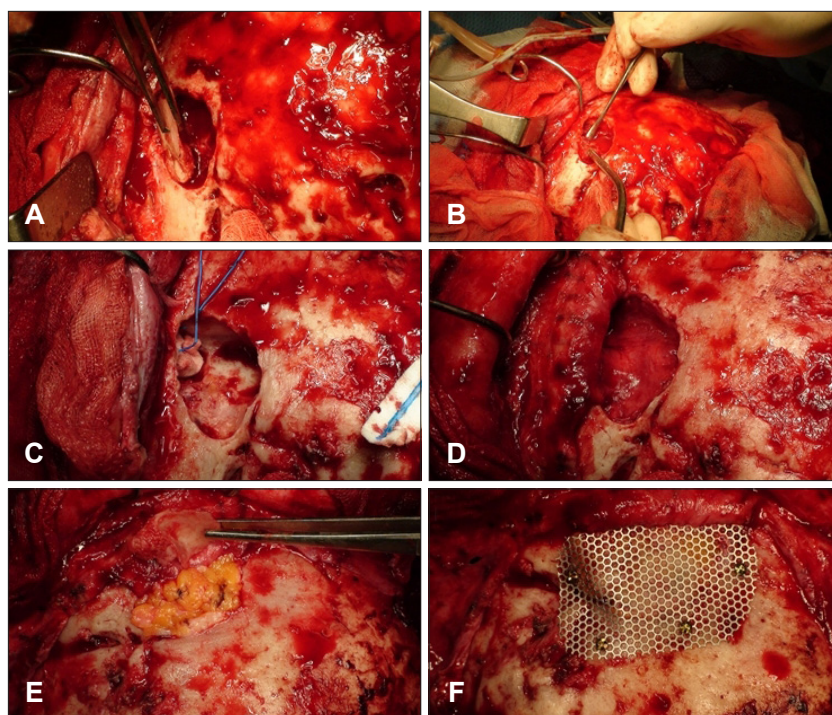


FIGURE 2. Operative photographs demonstrating the cranialization procedure. A: Removal anterior wall of the frontal sinus. B: Removal of the granulated and inflamed wall of the frontal sinus. C: Meticulous extirpation of the frontal sinus mucosa. D: Flapping with the pericranial fascia to close the sinonasal tract. E: Packing the empty cavity with free fat tissue. F: Reconstruction of the anterior wall of the frontal sinus with a Mesh sheet.

traumatic meningitis.

Trauma to the frontal area, which contains the nasal sinuses, is particularly hazardous, since the dura in this region can be easily stripped from the bone and result in fistulous communications, allowing the entrance of organisms from the nasal passages.¹⁾ Traumatic CSF rhinorrhea is reported in about 1–3% of head trauma cases and patients with CSF leaks have a 25–37% risk of meningitis.^{9,10,12)} There are considered three routes of CSF rhinorrhea; through the frontal sinus, ethmoidal sinus and sphenoidal sinus.⁹⁾ A case with late post-traumatic rhinorrhea who died of fulminant meningitis within a day has been reported.¹⁴⁾ To verify the defect of CSF leakage, it is essential to study routine horizontal CT scans, cranial tomography, or magnetic resonance images. Especially, three dimensional reconstruction with sagittal view makes find the exact location of bony defects.¹¹⁾ In addition, brain CT scan is a highly accurate diagnostic tool to detect as little as 0.5 mL of air in the intracranial compartment.¹³⁾ Pneumocephalus may occur after destruction of the skull base or disruption of the dura matter.³⁾ Markham's survey of 295 patients with pneumocephalus, trauma was in 73.9%, followed by tumor (12.9%), infection (8.8%), surgical intervention (3.7%), and unknown causes (0.6%) as etiologic factors.¹¹⁾ Skull base destruction and cerebrospinal fistulous communication can be estimated by pneumocephalus occurrence.

Primary management for the post-traumatic meningitis is administration of proper antibiotics based on CSF penetration and organism sensitivities. *Streptococcus pneumoniae* is the most common causative agent of post-traumatic meningitis. Another common pathogens are *Staphylococcus aureus*, *Coagulase negative Staphylococcus*, *Enterobacter*, *Escherichia coli*, *Klebsiella pneumoniae*.^{6,8,15,16)} In this case, the patient was medicated empirical antibiotics (third generation cephalosporine and aminoglycoside). Although this regimen is suitable for *Streptococcus pneumoniae* that cultured from the abscess, his neurological state is suddenly and markedly deteriorated on the next day with antibiotics administration.

We raised a question, which therapy is better between the conservative and surgical management in this frontal sinus opening to the cerebral lobe with meningitis. On the surgical management, Emanuel reported that it is necessary to close a fistulous dural communication in order to prevent recurrent or persistent CSF rhinorrhea and bouts of meningitis.¹⁾ Our patient had underwent craniotomy for the traumatic fifteen years ago at a regional hospital. A brain CT scans showed air density with cerebromalactic change on the left frontal lobe with frontal sinus defect and pansinus-

itis. It was thought that the dural defect and craniotomy site deficit have progressed slowly for fifteen years. The appropriate antibiotics for posttraumatic meningitis is selected based on CSF penetration and organism sensitivities. Empiric antibiotics are vancomycin and ceftazidime. It is recommended to continue antibiotic for one week after CSF is sterilized. If rhinorrhea persists at this time, surgical repair is recommended. Early surgical treatment may be considered as a good treatment option. Immediate surgical treatment is needed for meningitis cannot be treated with certain antibiotics. A successful surgical option is cranialization. Cranialization of the frontal sinus was first described in 1978 by Donald and Bernstein.⁴⁾ The original description consisted of removing the posterior wall of the frontal sinus, meticulous removal of the frontal sinus mucosa, and allowing the frontal lobe dura mater to come to rest against the anterior table and floor of the frontal sinus.³⁾ Goals of this procedure are the extirpation of all sinus mucosa and the complete separation of the intracranial cavity from the sinonasal tract below. Conventionally, the area originally occupied by the frontal sinus is left as dead space or filled with free adipose tissue.^{4,5,17)} Pericranial flaps based on the supra-orbital and supra-trochlear vasculature have previously been used with significant success for separation of intracranial and extracranial spaces after major reconstructive efforts in the head, neck, and anterior skull base.^{7,18)}

Conclusion

Posttraumatic meningitis can occur at any time after traumatic brain injury, from a few days to years. Therefore, possibility of posttraumatic meningitis is to be kept in mind in managing patients with history of traumatic brain injury. There may be different opinion which treatment is first-line therapy for the post-traumatic meningitis between antibiotics and surgery. Our case shows surgical treatment for rapid control of infection is to be considered in some cases of posttraumatic meningitis. We think that frontal sinus opening to the dura mater should be managed by cranialization for the prevention of recurrent attack of possible life-threatening posttraumatic meningitis.

■ The authors have no financial conflicts of interest.

REFERENCES

- 1) Appelbaum E. Meningitis following trauma to the head and face. *JAMA* 173:1818-1822, 1960
- 2) Baltas I, Tsoulfa S, Sakellariou P, Vogas V, Fylaktakis M, Kondodimou A. Posttraumatic meningitis: bacteriology, hydrocephalus.

- lus, and outcome. *Neurosurgery* 35:422-426; discussion 426-427, 1994
- 3) Byron BJ (ed). Head and neck surgery-otolaryngology. Philadelphia: Lippicott Williams & Wilkins, Vol 2, pp1107, 1993
 - 4) Donald PJ. Frontal sinus ablation by cranialization. Report of 21 cases. *Arch Otolaryngol* 108:142-146, 1982
 - 5) Donald PJ, Bernstein L. Compound frontal sinus injuries with intracranial penetration. *Laryngoscope* 88(2 Pt 1):225-232, 1978
 - 6) Friedman JA, Ebersold MJ, Quast LM. Post-traumatic cerebrospinal fluid leakage. *World J Surg* 25:1062-1066, 2001
 - 7) Johns ME, Winn HR, McLean WC, Cantrell RW. Pericranial flap for the closure of defects of craniofacial resection. *Laryngoscope* 91:952-959, 1981
 - 8) Kim DS, Lee JY, Coe CJ, Suh JS. A case of recurrent bacterial meningitis with CSF rhinorrhea. *J Korean Pediatr Soc* 32:1161-1166, 1989
 - 9) Leech P. Cerebrospinal fluid leakage, dural fistulae and meningitis after basal skull fractures. *Injury* 6:141-149, 1974
 - 10) Lewin W. Cerebrospinal fluid rhinorrhea in nonmissile head injuries. *Clin Neurosurg* 12:237-252, 1964
 - 11) Markham JW. The clinical features of pneumocephalus based upon a survey of 284 cases with report of 11 additional cases. *Acta Neurochir (Wien)* 16:1-78, 1967
 - 12) Mincy JE. Posttraumatic cerebrospinal fluid fistula of the frontal fossa. *J Trauma* 6:618-622, 1966
 - 13) Osborn AG, Daines JH, Wing SD, Anderson RE. Intracranial air on computerized tomography. *J Neurosurg* 48:355-359, 1978
 - 14) Saito H. Late posttraumatic rhinogenic meningitis. Temporal bone findings of meningogenic labyrinthitis. *Adv Otorhinolaryngol* 31: 175-183, 1983
 - 15) Stillwell M, Hoge C, Hoyt N, Joshi M. Posttraumatic meningococcal meningitis: case report. *J Trauma* 31:1693-1695, 1991
 - 16) Wada N, Takeuchi Y, Fujii M, Fujiwara F, Odani I, Sawada T. A case of bacterial meningitis complicated by post-traumatic cerebrospinal fluid rhinorrhea. *Acta Paediatr Jpn* 36:276-279, 1994
 - 17) Wallis A, Donald PJ. Frontal sinus fractures: a review of 72 cases. *Laryngoscope* 98(6 Pt 1):593-598, 1988
 - 18) Wolfe SA. The utility of pericranial flaps. *Ann Plast Surg* 1:147-153, 1978