

Single Stage Posterior Lumbar-Sacral Reconstruction with Expendable Cage and Iliac Screw for Fifth Lumbar Fracture-Dislocation

Won-Seo Choi, MD, Kyoung-Suok Cho, MD, PhD, Sang-Bok Lee, MD, Pill-Woo Huh, MD, PhD and Do-Sung Yoo, MD, PhD

Department of Neurosurgery, Uijeongbu St. Mary's Hospital, The Catholic University College of Medicine, Uijeongbu, Korea

Fracture-dislocations of the fifth lumbar vertebra are rare. Treatment of L5 vertebra fractures depends on fracture type and neurological findings. The authors describe a single-staged surgical technique of only posterior circumferential decompression, spinal reconstruction with expendable cage insertion and instrument fixation.

(Korean J Neurotrauma 2013;9:135-138)

KEY WORDS: Burst fracture · Expendable cage · Fracture-dislocation · Fifth lumbar vertebra.

Introduction

Burst fractures most frequently affect the thoracolumbar spine due to the fulcrum of increased motion occurring at the T12-L1 junction. However, isolated burst fractures of the fifth lumbar (L5) vertebra can occur but are very rare.^{10,17)}

We present a woman with a fracture-dislocation of the fifth lumbar vertebra complicated by neurological damage. She was treated by posterior surgery with transpedicular instrumentation and an expendable cage via posterior approach. Methods involving a corpectomy, placement of an expendable cage (Synex Cage, Synthes, West Chester, PA, USA), and implantation of posterior instrumentation via a single posterior approach are discussed.

Case Report

A 48-year-old female was taken to our hospital with a fracture-dislocation of the L5 vertebra complicated by neurolo-

gical damage. She had jumped from a bridge 7 m high while intoxicated and landed on her feet. She complained of severe pain in her lower back and both legs and had a fracture of the L5 vertebra and fractures of both legs. On examination, she had lower limbs weakness on bilateral hip and knee with grade IV- power and below knee with grade II power. Sensation was decreased in the L5 and S1 distributions bilaterally as well as in the perineal region. Distal pulses were strong in both lower extremities. Plain radiographs and computed tomographic scans of the lumbosacral spine revealed a three-column injury at L5 with spondylolisthesis of the L5 vertebral body and multiple injuries of the thorax and both legs (Figure 1). A lower extremity CT angiography was performed to assess for potential vascular injury to the abdominal aorta or iliac vessels. This study revealed no evidence of arterial injury or vascular compression with the L5 body located between the iliac vessels below the aortic bifurcation. We decided to perform emergency operation to promote early neurologic recovery because patient had incomplete neurologic deficit. In the prone position, a standard midline posterior subperiosteal dissection was carried out above and below the injured vertebral body. Due to neurological involvement, total laminectomy and complete facetectomy of the L5 were performed, with removal of all bone fragments and decompression of neural structures. The dura was absent with multiple transected nerve roots noted. The

Received: March 25, 2013 / **Revised:** July 30, 2013

Accepted: July 30, 2013

Address for correspondence: Sang-Bok Lee, MD
Department of Neurosurgery, Uijeongbu St. Mary's Hospital, The Catholic University of Korea College of Medicine, 271 Cheonbo-ro, Uijeongbu 480-130, Korea
Tel: +82-31-820-3024, Fax: +82-31-846-3117
E-mail: doctorwish@hanmail.net

dural defect was sutured using 5/0 prolene and covered with gelfoam, a lumbosacral fascial flap, and fibrin glue. Pedicle screw fixation was achieved at the L3, L4, and S1 levels and the alar screw fixation was performed to the alar wings bilaterally. It is difficult to restore the affected vertebra by means of distracting the L4 and S1 screws. So, we inserted an expandable cage into the L5 body space via posterior approach for distraction. Complete discectomies of the adjacent discs L4/5 and L5/S1 were undertaken. The corpectomy was then performed using large curettes, Kerrison rong-

eurs, and pituitary graspers while the dura and root were protected with a nerve retractor. The expandable cage was filled with bone chips from the vertebral body to achieve fusion. After careful separation of the thecal sac, the Synex expandable cage for thoracic vertebrae, which is narrower than a lordotically curved lumbar one, was inserted between the bodies of L4 and S1 from the left side while simultaneously lifting the sacrum with the two L4 and alar screws inserted into iliac crest as well as distraction of the inserted Synex, and a favorable position of the spine was achieved

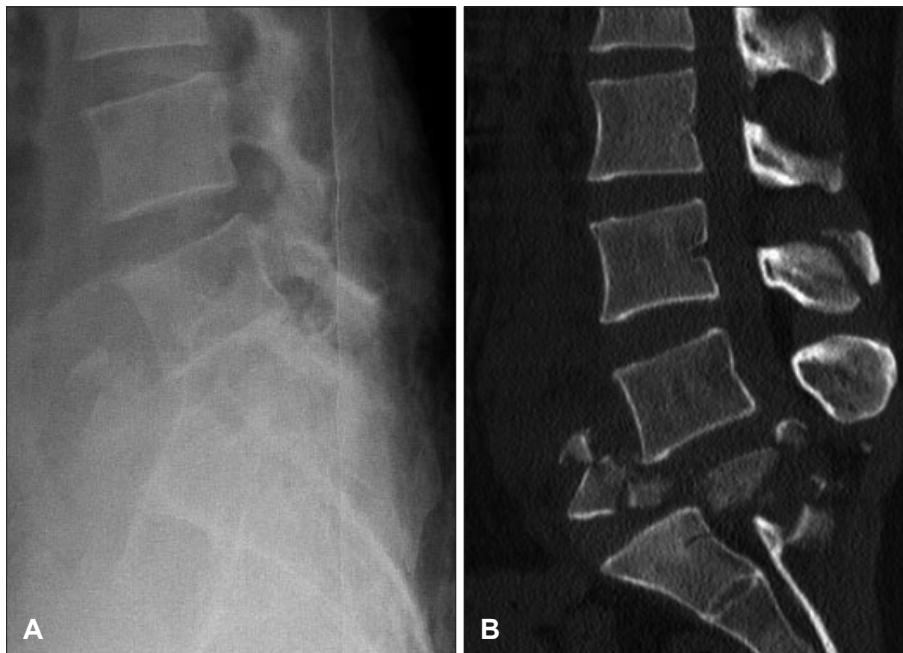

FIGURE 1. A: Fracture of the fifth lumbar vertebra-lateral view. B: Fracture of the fifth lumbar vertebra-CT sagittal reconstruction.

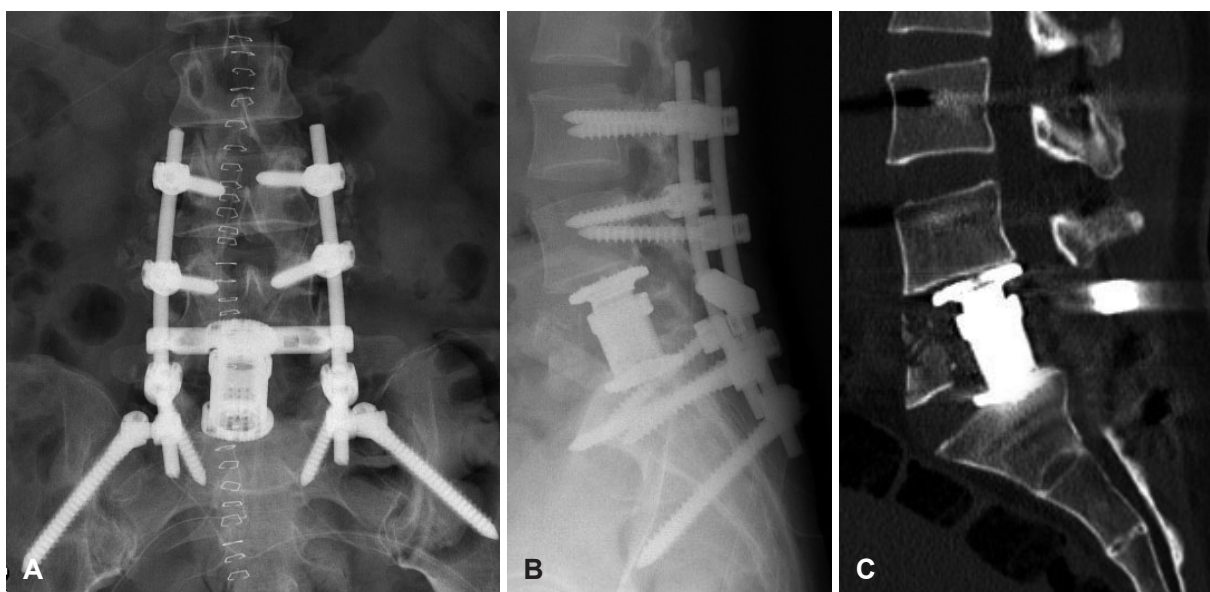


FIGURE 2. A: AP view after stabilization L4-S1-alar screw and Synex expandable cage. B: Lateral view after stabilization. C: CT scan 1 year after operation (sagittal reconstruction) shows fully decompressed canal and the presence of fused anterior reconstruction.

(Figure 2). An arthrodesis was then performed from L4 to S1 using autologous iliac crest bone grafts. The wound was then copiously irrigated with antibiotic-laden normal saline and closed in routine fashion. Prophylactic lumbar drainage was performed for prevention of cerebrospinal fluid leakage. The patient was on bed rest for 4 weeks before beginning active rehabilitation. Six months postoperatively, the patient was neurologically improved and lower limb motor power showed grade V on both hip, knee and below knee with grade III; however, she was able to walk with the aid of a cane. Lumbosacral X-rays revealed normal alignment of the lumbosacral spine with good position of instrumentation.

Discussion

Complete fracture-dislocation of the L5 vertebra is rare, and little information can be found in the literature regarding the surgical treatment of this entity.^{11,17)} The literature reports only individual patients or very small groups of patients. Fractures of the lumbosacral spine have to be distinguished from fractures of the thoracolumbar spine, because of the particular anatomic and biomechanical characteristics of this region of the spine. At the level of L5, the spinal canal is wide and the nerve roots are more resistant to compressive forces than is the conus medullaris at the thoracolumbar junction.^{1,7)} For this reason, neurologic deficits are less common in L5 fractures than in fractures involving the thoracolumbar area, and recommendations for treatment are controversial.⁹⁾ Conservative management was proposed in patients with isolated burst fractures of the L5 vertebra without neurological damage and satisfactory clinical outcome with very good pain status was reported.^{5,6)}

In contrast to the results of Mick et al.¹⁴⁾ described a significant loss of height in the anterior column in five patients treated non-operatively, whereas in six fractures that underwent posterior stabilization, an increase of height in the anterior column was noted. They propose conservative management in young patients with minimal canal compromise. Surgical treatment is more appropriate when neurologic deficits exist.

In view of the reported data in the above literature, surgical stabilization of burst fractures of the fifth lumbar vertebra seems not to be recommended on a routine basis. The question of whether stabilization provides better radiological results has yet to be answered, but obviously the radiological result does not correlate with the functional outcome. Surgery can decompress neural structures and stabilize the spine but does not improve neurological status in most fracture-dislocations.⁸⁾ Operative stabilization is only recom-

mended if the patient has a severe neurologic deficit due to canal compromise and pain is intractable despite adequate pain medication. In our case, the burst fracture of the L5 vertebra with dislocation in the patient was completely different from the types of L5 fractures that had been mentioned previously. This patient completely disrupted all three columns of the L5 vertebra. Patients uniformly complained of severe lower back pain as well as exquisite pain to palpation. She had also complete fracture-dislocations of L5 cause an L4 paraparesis.

Lumbar and lumbosacral fracture-dislocations may be treated surgically from an anterior, posterior, or combined anteroposterior approach. The anterior operative approach and the posterior approach have been used with good success and fewer complications. Combined procedures of posterior arthrodesis and anterolateral decompression are indicated in patients with residual canal compromise after posterior fusion. In our case, posterior transpedicular fixation alone was not enough to stabilize the affected lumbar spine due to complete bursting fracture-dislocations of the L5 vertebral body. The anterior-only surgical approach is not appropriate for our case because of severe injury to the posterior ligamentous complex. Additionally, the anterior approach to the L5 vertebra is associated with danger to the superior hypogastric plexus and large vessel injury.^{4,13)}

We decided a single-stage surgery with inserting the expandable cage via posterior approach. We performed total L5 laminectomy to decompress both the L5 nerve and dural sac, L5 corpectomy was done while the dura and root were protected with a nerve retractor, and spinal reconstruction was achieved with cage insertion, and the placement of posterior instrumentation.

There are two reasons for using an expandable cage in our case. First, our patient had a combination of a fracture-dislocation of the L5 vertebra with dislocation and complete disruption of the posterior ligamentous complex between L5 and the sacrum. Due to the severe comminution of the L5 vertebral body and ligamentous injury, the sacrum lost the support of the lumbar vertebra and was tilted forward. To maintain the surgically accomplished proper sagittal alignment of the sacrum, we inserted a Synex expandable cage into the gap between L4 and S1. We achieved reduction by distraction against the endplates of L4 and S1 by the expandable cage.

Second, combined anteroposterior approaches are associated with a higher complication rate than those involving single-stage surgery. Patients are more likely to have wound, nutritional, respiratory, fluid overload, and blood depletion problems compared with those who have undergone single-

stage surgery. Additionally, avoidance of the anterior incision averts potential muscle denervation and injury to vessels, ureter, sympathetic nerves, and peritoneum. It is difficult to restore lumbar sagittal alignment via only anterior approach in case of severe fracture-dislocation spine fracture. In our case, single-stage surgery with expandable cage reconstruction of the lumbar spine via posterior approach can be feasible and an alternative treatment instead of circumferential approach. In review of other articles, there are 3 series involving one stage corpectomy and expandable cage insertion.^{10,12,16)} The method presented in these papers offer most of the advantages associated with the anterior approach while avoiding the risks. Use of a posterior approach for burst fractures is positive in that it is familiar to the spine surgeon, eliminates risk of damage to vital visceral-vascular structures, and allows for safe surgical re-exploration. The presented technique is a posterior approach that involves spinal decompression (including laminectomy), corpectomy, and vertebral reconstruction with placement of an expandable cage in the anterior column and with posterior transpedicular screwing and instrumentation. This single-stage posterior approach for acute lumbar burst fractures offers some advantages over the classic combined anterior-posterior approach. Most cases of lumbar or lumbosacral fracture-dislocation result in a permanent neurological deficit,¹⁵⁾ although complete recovery has been reported in some cases.¹⁸⁾ However, in this region it is no longer the spinal cord that is affected. The nerve roots that form the cauda equina originate from the second motor neuron, and neurological deficits at this level are similar to peripheral nerve lesions and demonstrate a prognostically advantageous tendency for spontaneous recovery.³⁾ The cauda equina shows a higher resistance than the conus medullaris to external effects.²⁾ Preoperative evaluation does not predict neurological outcome, because the amount of canal compromise revealed by computed tomography correlates poorly with the degree of neurological deficit.⁸⁾ Also, there are significant doubts that improvement of the neurological situation can be achieved by “surgical clearance” of the canal.

Conclusion

Fracture-dislocations of the L5 vertebra are rare. Surgical treatment and approach direction depend on fracture morphology and neurological status. In this case, this surgical technique showed methods for L5 corpectomy, circumferential reconstruction, and arthrodesis performed solely via a posterior approach, thus avoiding the complications of combined anterior-posterior surgery and facilitating a quicker

recovery.

■ The authors have no financial conflicts of interest.

REFERENCES

- 1) Abdel-Fattah H, Rizk AH. Complete fracture-dislocation of the lower lumbar spine with spontaneous neurologic decompression. *Clin Orthop Relat Res*:140-143, 1990
- 2) An HS, Vaccaro A, Cotler JM, Lin S. Low lumbar burst fractures. Comparison among body cast, Harrington rod, Luque rod, and Steffee plate. *Spine (Phila Pa 1976)* 16(8 Suppl):S440-S444, 1991
- 3) Andreychik DA, Alander DH, Senica KM, Stauffer ES. Burst fractures of the second through fifth lumbar vertebrae. Clinical and radiographic results. *J Bone Joint Surg Am* 78:1156-1166, 1996
- 4) Bingol H, Cingoz F, Yilmaz AT, Yasar M, Tatar H. Vascular complications related to lumbar disc surgery. *J Neurosurg* 100(3 Suppl Spine):249-253, 2004
- 5) Blanco JF, De Pedro JA, Hernández PJ, Paniagua JC, Framiñán A. Conservative management of burst fractures of the fifth lumbar vertebra. *J Spinal Disord Tech* 18:229-231, 2005
- 6) Butler JS, Fitzpatrick P, Ni Mhaolain AM, Synnott K, O'Byrne JM. The management and functional outcome of isolated burst fractures of the fifth lumbar vertebra. *Spine (Phila Pa 1976)* 32:443-447, 2007
- 7) Chan DP, Seng NK, Kaan KT. Nonoperative treatment in burst fractures of the lumbar spine (L2-L5) without neurologic deficits. *Spine (Phila Pa 1976)* 18:320-325, 1993
- 8) Durward QJ, Schweigel JF, Harrison P. Management of fractures of the thoracolumbar and lumbar spine. *Neurosurgery* 8:555-561, 1981
- 9) Fredrickson BE, Yuan HA, Miller H. Burst fractures of the fifth lumbar vertebra. A report of four cases. *J Bone Joint Surg Am* 64:1088-1094, 1982
- 10) Hunt T, Shen FH, Arlet V. Expandable cage placement via a posterolateral approach in lumbar spine reconstructions. Technical note. *J Neurosurg Spine* 5:271-274, 2006
- 11) Kaminski A, Müller EJ, Muhr G. Burst fracture of the fifth lumbar vertebra: results of posterior internal fixation and transpedicular bone grafting. *Eur Spine J* 11:435-440, 2002
- 12) Kocis J, Wendsche P, Visna P. Complete burst fracture of the fifth lumbar vertebra treated by posterior surgery using expandable cage. *Acta Neurochir (Wien)* 150:1301-1305; discussion 1305, 2008
- 13) Mayer HM, Wiechert K, Korge A, Qose I. Minimally invasive total disc replacement: surgical technique and preliminary clinical results. *Eur Spine J* 11 Suppl 2:S124-S130, 2002
- 14) Mick CA, Carl A, Sachs B, Hresko MT, Pfeifer BA. Burst fractures of the fifth lumbar vertebra. *Spine (Phila Pa 1976)* 18:1878-1884, 1993
- 15) Prasad VS, Vidyasagar JV, Purohit AK, Dinakar I. Early surgery for thoracolumbar spinal cord injury: initial experience from a developing spinal cord injury centre in India. *Paraplegia* 33:350-353, 1995
- 16) Sasani M, Ozer AF. Single-stage posterior corpectomy and expandable cage placement for treatment of thoracic or lumbar burst fractures. *Spine (Phila Pa 1976)* 34:E33-E40, 2009
- 17) Seybold EA, Sweeney CA, Fredrickson BE, Warhold LG, Bernini PM. Functional outcome of low lumbar burst fractures. A multicenter review of operative and nonoperative treatment of L3-L5. *Spine (Phila Pa 1976)* 24:2154-2161, 1999
- 18) Suomalainen O, Pääkkönen M. Fracture dislocation of the lumbar spine without paraplegia. A case report. *Acta Orthop Scand* 55:466-468, 1984