

Preliminary Report of Percutaneous Vertebroplasty for the Treatment of the Burst Fractures with Spinal Canal Encroachment

Ji Won Choi, MD, Je Hoon Jeong, MD, PhD, Il Young Shin, MD,
Seung-Myung Moon, MD and Hyung Sik Hwang, MD

Department of Neurosurgery, Hangeang Sacred Heart Hospital, College of Medicine, Hallym University, Seoul, Korea

Objective: Percutaneous vertebroplasty is a minimally invasive procedure to relieve or decrease pain in patients with osteoporotic compression fractures. However, vertebroplasty in the osteoporotic burst fracture patients with preoperative canal encroachment are still being debated, because it can aggravate spinal canal encroachment. The objects of this study is evaluation of the changes in spinal canal narrowing after percutaneous vertebroplasty.

Methods: Inclusion criteria was osteoporotic bursting fracture patients with 5 to 20% canal encroachment (less than 5 mm). Exclusion criteria included pathological fractures, unstable vertebral fractures involving the posterior column, and severe neurological deficit. We measured the changes in spinal canal narrowing by pre- and postoperative computed tomography. Degree of canal encroachment was measured as the distance between the imaginary line along the posterior margin of the bony fragment and the maximal anterior imaginary line of the spinal canal in the axial CT scan.

Results: This study was based on 10 patients (1 male and 9 female; age range, 52–89 years; mean age, 75 years). The mean decrease in the compression rate of the vertebral body height was 14.4% (43.4% to 29%). The mean decrease in the kyphotic angle was 4.3° (11.7° to 7.4°). The mean preoperative canal encroachment were 3.5 mm and postoperative canal encroachment was 3.7 mm, respectively. The mean preoperative VAS score was 4.3 and postoperative VAS score was 1.4.

Conclusion: Vertebroplasty can be a safe treatment option for osteoporotic burst fractures with preoperative minimal canal encroachment.

(Korean J Neurotrauma 2012;8:64-67)

KEY WORDS: Vertebroplasty · Spinal injuries · Osteoporotic fractures · Kyphosis · Spinal canal.

Introduction

Vertebroplasty, a surgical procedure developed by Galibert and Deramond in 1987, involves the injection of bone cement into a collapsed vertebral body.⁹⁾ The main indications of vertebroplasty have been extended to painful osteoporotic compression fractures, vertebral myelomas, and metastases and so on.^{14,16)}

Several previous studies have evaluated the radiological

changes in vertebral body height, kyphotic angle, and spinal canal diameter after vertebroplasty.^{2,8,11,15,18,24)} However, there are few reports on the changes in the spinal canal of patients with preoperative canal encroachment.¹⁾ Furthermore, because vertebroplasty can aggravate spinal canal encroachment, its use in the treatment of osteoporotic burst fractures accompanied with preoperative canal encroachment remains debatable. Therefore, we evaluated the changes in spinal canal diameter after percutaneous vertebroplasty.

Materials and Methods

Patients

From January 2005 to October 2010, we performed vertebroplasty in total 201 patients. Inclusion criteria was osteoporotic bursting fracture patients with 5 to 20% canal en-

Received: March 2, 2012 / **Revised:** April 4, 2012

Accepted: April 6, 2012

Address for correspondence: Je Hoon Jeong, MD, PhD
Department of Neurosurgery, Hangeang Sacred Heart Hospital,
College of Medicine, Hallym University, 94-200 Yeongdeungpo-
dong, Yeongdeungpo-gu, Seoul 150-719, Korea
Tel: +82-2-2639-5650, Fax: +82-2-2676-7020
E-mail: neuri71@gmail.com

croachment and bone mineral density lower than -3.0 . Exclusion criteria included pathological fractures, unstable vertebral fractures involving the posterior column, and severe neurological deficits.

Patients under 80 years old were treated with postural reduction preoperatively during about 2 weeks but patients over 80 years old were performed vertebroplasty immediately after the onset. Pre- and postoperative computed tomography (CT) was performed in all patients. After discharge, X-ray follow up was done in the outpatient office. We reviewed the radiological and clinical data retrospectively.

ately after the onset. Pre- and postoperative computed tomography (CT) was performed in all patients. After discharge, X-ray follow up was done in the outpatient office. We reviewed the radiological and clinical data retrospectively.

Vertebroplasty technique

The patients were placed in a prone position. An 11-G

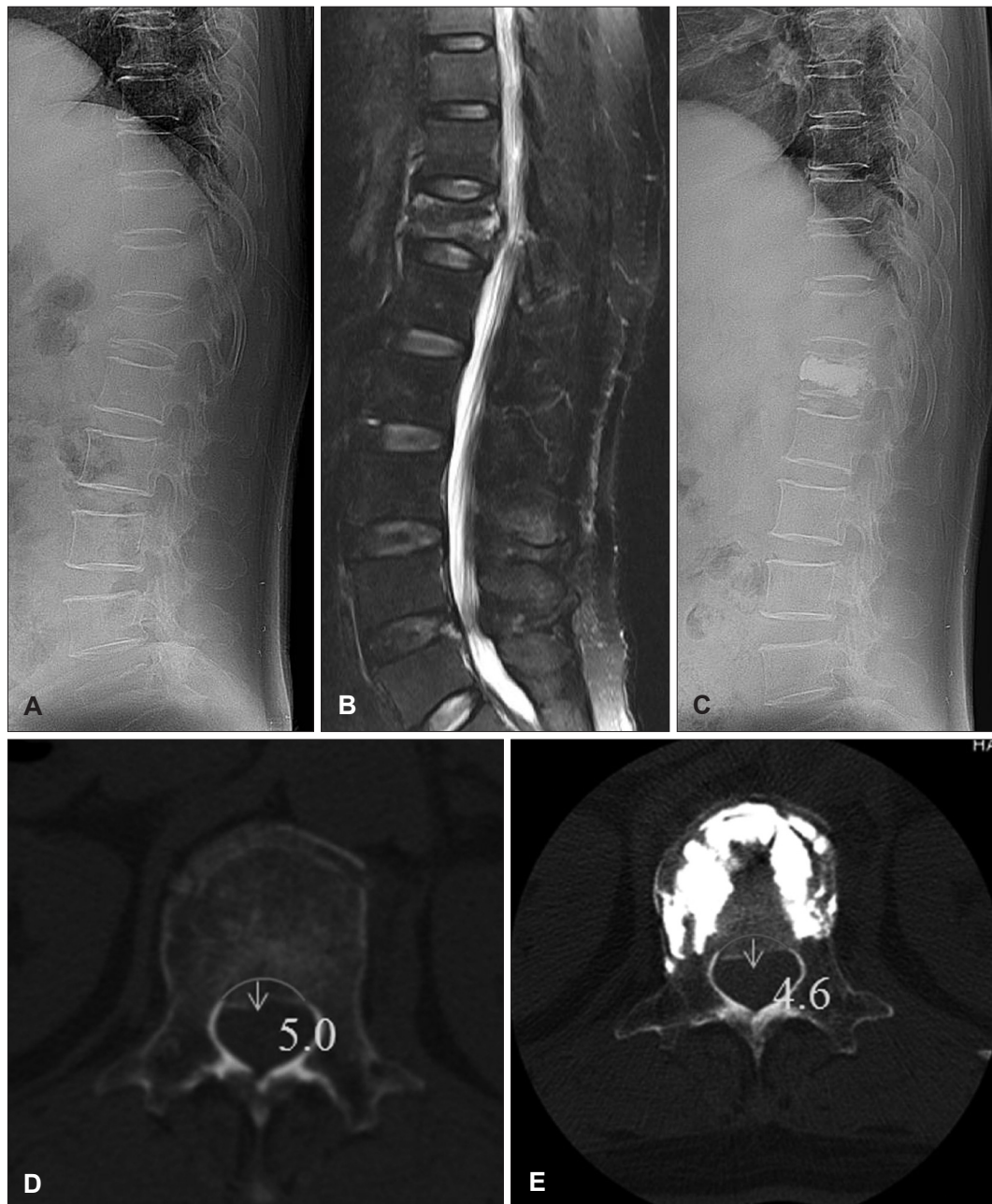


FIGURE 1. A: 73-year-old female patient had a burst fracture of T12 on initial plain film. B: magnetic resonance image T2 weighted image shows the collapsed vertebra with canal encroachment. C: After the percutaneous vertebroplasty, the height of the vertebral body was increased and kyphotic angle was decreased. D: Encroachment of the bone fragment was measured in the axial plane by using a distance from the line between the posterior margin of the bony fragment and maximal anterior imaginary line of the spinal canal in axial computed tomography scan. E: After the percutaneous vertebroplasty, there is no exacerbation with canal encroachment.

vertebroplasty needle was inserted via a transpedicular approach by using Siremobil Iso-C3D (Siemens Medical Solutions, Erlangen, Germany). The needle tip was placed at the anterior one third of the vertebral body. Once the needle was placed inside the vertebral body, and the liquid and powder component of polymethylmethacrylate (PMMA) were mixed and injected steadily 1.5 cc per 1 min through the needle under fluoroscopic guidance. PMMA was injected using uni- or bilateral pedicle needles. After vertebroplasty, the patients were rested in a supine position for 3–4 h.

Radiological assessment

We measured the radiological changes by pre- and postoperative simple X-ray and three dimensional computed tomography. Degree of canal encroachment was measured as the distance between the imaginary line along the posterior margin of the bony fragment and the maximal anterior imaginary line of the spinal canal in the axial CT scan (Figure 1). We also measured the vertebral body height in the anterior portions of the vertebra and the wedge angle in the midsagittal plane, as previously described.^{11,12)}

Results

Ten consecutive patients (9 women and 1 man) with fractured vertebrae were treated using vertebroplasty. The average age of these patients was 75.1 years (range, 52–89 years). The mean T score was –3.64. The following vertebrae levels were treated with vertebroplasty for spinal canal encroachment: T12 (n=4), L1 (n=3), L2 (n=1), L3 (n=1), and L4 (n=1). The average amount of PMMA injected into these levels was 5.0 mL (range, 3–10 mL).

After the procedure, all the patients reported an improvement in the pain and no aggravation of neurological deficit. The mean preoperative Visual Analog Scale (VAS) score was 4.3 (range, 3–5), while that postoperative VAS score was 1.4 (range, 1–2).

The mean compression rate of the vertebral body height decreased from 43.4% before to 29% after vertebroplasty (mean decrease, 14.4%). Furthermore, the mean kyphotic angle decreased from 11.7° before to 7.4° after vertebroplasty (mean decrease, 4.3°). The mean preoperative spinal

canal encroachment were 3.5 (range 2.3–5.4) and postoperative spinal canal encroachment was 3.7 (range 1–5.4) mm (Table 1).

The follow-up period ranged from 2 to 38 months (mean, 13 months). After vertebroplasty, complications such as clinical sequelae that require surgical intervention or exacerbate the neurological condition were not observed.

Discussion

Percutaneous vertebroplasty involves percutaneous injection of PMMA or bone cement into a diseased vertebra. The use of vertebroplasty in the treatment of benign or malignant disease has been widely reported.^{4,19,27)} The effectiveness of percutaneous vertebroplasty in alleviating pain has been discussed comprehensively.^{6,17)} In our study, all the patients experienced an improvement in the pain. The mean VAS score before vertebroplasty was 4.3 (range, 3–5), whereas that after vertebroplasty was 1.4 (range, 1–2).

Vertebroplasty has an extra benefit, in that it allows restoration of some of the lost vertebral body height and improves the kyphotic angle.^{2,8,11,15,18,24)} Many previous studies have reported an increase in the vertebral body height after vertebroplasty,^{11,18,24)} and many clinical studies also have reported that burst fracture reduction was the most consistent predictor of a satisfactory outcome.⁷⁾

Cement leakage is the one of the serious potential complication of vertebroplasty, which can result in major complications, such as spinal cord compression and paraplegia requiring emergent decompression.^{3,10,23,25)} In especially, there are more risks of leakage in burst fracture with separated fragment or endplate fracture, such as our cases. Since PMMA tends to flow to the area of least resistance, creating a cavity within the fractured vertebra enables low-pressure injection, thus theoretically reducing this risk. We used the preoperative postural reduction to expand the collapsed vertebral fractures for the acquisition of more additional space of the bone cement. Another precautionary measure is continuous fluoroscopy during cement injection. If the PMMA seems to be nearing the posterior vertebral cortex, further injection is aborted.²¹⁾

Because the vertebroplasty procedure involves the injec-

TABLE 1. Mean vertebral body height, kyphotic angle, canal encroachment, Visual Analog Scale (VAS) score changes

	Compression rate of vertebral body (%)	Kyphotic angle (°)	Canal Encroachment (mm)	VAS score
Preoperative	43.4	11.7	3.5	4.3
Postoperative	29	7.4	3.7	1.4
Changes	–14.4	–4.3	+0.2	–2.9

tion of a large amount of PMMA, this procedure carries a risk of exacerbating the spinal canal encroachment.^{4,10,22} Therefore, spinal canal encroachment and spinal cord compression have been cited as relative contraindications by previous literature.^{13,20,26} For this reason, surgeons are reluctant to perform vertebroplasty in patients with osteoporotic burst fractures accompanied with spinal canal encroachment. In our study, the mean spinal canal encroachment before and after vertebroplasty, was 3.5 mm and 3.7 mm, respectively. Vertebroplasty did not exacerbate the canal encroachment that required surgical intervention. We think that obtaining stable space for bone cement injection by preoperative postural reduction and steady PMMA injection (1.5 cc per 1 minute) are important.

Although good postoperative result of this study, it has many limitations such as short follow up period, small patients, no follow up computed tomography. Therefore, we think that further study with long term follow up and large population is needed.

Conclusion

In this study, the authors safely performed vertebroplasty in patients with 5 to 20% preoperative canal encroachment. Therefore, vertebroplasty might be a safe treatment option for burst fractures accompanied with mild preoperative canal encroachment and no neurological deficit.

■ The authors have no financial conflicts of interest.

REFERENCES

- 1) Appel NB, Gilula LA. Percutaneous vertebroplasty in patients with spinal canal compromise. *AJR Am J Roentgenol* 182:947-951, 2004
- 2) Carlier RY, Gordji H, Mompoint DM, Vernhet N, Feydy A, Vallée C. Osteoporotic vertebral collapse: percutaneous vertebroplasty and local kyphosis correction. *Radiology* 233:891-898, 2004
- 3) Chen YJ, Tan TS, Chen WH, Chen CC, Lee TS. Intradural cement leakage: a devastatingly rare complication of vertebroplasty. *Spine (Phila Pa 1976)* 31:E379-E382, 2006
- 4) Cotten A, Boutry N, Cortet B, Assaker R, Demondion X, Leblond D, et al. Percutaneous vertebroplasty: state of the art. *Radiographics* 18:311-320; discussion 320-323, 1998
- 5) Cotten A, Dewatre F, Cortet B, Assaker R, Leblond D, Duquesnoy B, et al. Percutaneous vertebroplasty for osteolytic metastases and myeloma: effects of the percentage of lesion filling and the leakage of methyl methacrylate at clinical follow-up. *Radiology* 200:525-530, 1996
- 6) Deramond H, Depriester C, Galibert P, Le Gars D. Percutaneous vertebroplasty with polymethylmethacrylate. Technique, indications, and results. *Radiol Clin North Am* 36:533-546, 1998
- 7) Dimar JR 2nd, Wilde PH, Glassman SD, Puno RM, Johnson JR. Thoracolumbar burst fractures treated with combined anterior and posterior surgery. *Am J Orthop (Belle Mead NJ)* 25:159-165, 1996
- 8) Dublin AB, Hartman J, Latchaw RE, Hald JK, Reid MH. The vertebral body fracture in osteoporosis: restoration of height using percutaneous vertebroplasty. *AJNR Am J Neuroradiol* 26:489-492, 2005
- 9) Galibert P, Deramond H, Rosat P, Le Gars D. [Preliminary note on the treatment of vertebral angioma by percutaneous acrylic vertebroplasty]. *Neurochirurgie* 33:166-168, 1987
- 10) Harrington KD. Major neurological complications following percutaneous vertebroplasty with polymethylmethacrylate: a case report. *J Bone Joint Surg Am* 83-A:1070-1073, 2001
- 11) Hiwatashi A, Moritani T, Numaguchi Y, Westesson PL. Increase in vertebral body height after vertebroplasty. *AJNR Am J Neuroradiol* 24:185-189, 2003
- 12) Hiwatashi A, Sidhu R, Lee RK, deGuzman RR, Piekut DT, Westesson PL. Kyphoplasty versus vertebroplasty to increase vertebral body height: a cadaveric study. *Radiology* 237:1115-1119, 2005
- 13) Jensen ME, Dion JE. Percutaneous vertebroplasty in the treatment of osteoporotic compression fractures. *Neuroimaging Clin N Am* 10:547-568, 2000
- 14) Kallmes DF, Jensen ME. Percutaneous vertebroplasty. *Radiology* 229:27-36, 2003
- 15) Lee ST, Chen JF. Closed reduction vertebroplasty for the treatment of osteoporotic vertebral compression fractures. Technical note. *J Neurosurg* 100(4 Suppl Spine):392-396, 2004
- 16) Martin JB, Jean B, Sugiu K, San Millán Ruiz D, Pötter M, Murphy K, et al. Vertebroplasty: clinical experience and follow-up results. *Bone* 25(2 Suppl):11S-15S, 1999
- 17) Mathis JM, Petri M, Naff N. Percutaneous vertebroplasty treatment of steroid-induced osteoporotic compression fractures. *Arthritis Rheum* 41:171-175, 1998
- 18) McKiernan F, Jensen R, Faciszewski T. The dynamic mobility of vertebral compression fractures. *J Bone Miner Res* 18:24-29, 2003
- 19) Peh WC, Gilula LA, Peck DD. Percutaneous vertebroplasty for severe osteoporotic vertebral body compression fractures. *Radiology* 223:121-126, 2002
- 20) Peters KR, Guiot BH, Martin PA, Fessler RG. Vertebroplasty for osteoporotic compression fractures: current practice and evolving techniques. *Neurosurgery* 51(5 Suppl):S96-S103, 2002
- 21) Rahamimov N, Mulla H, Shani A, Freiman S. Percutaneous augmented instrumentation of unstable thoracolumbar burst fractures. *Eur Spine J* 21:850-854, 2012
- 22) Ratliff J, Nguyen T, Heiss J. Root and spinal cord compression from methylmethacrylate vertebroplasty. *Spine (Phila Pa 1976)* 26:E300-E302, 2001
- 23) Teng MM, Cheng H, Ho DM, Chang CY. Intraspinous leakage of bone cement after vertebroplasty: a report of 3 cases. *AJNR Am J Neuroradiol* 27:224-229, 2006
- 24) Teng MM, Wei CJ, Wei LC, Luo CB, Lirng JF, Chang FC, et al. Kyphosis correction and height restoration effects of percutaneous vertebroplasty. *AJNR Am J Neuroradiol* 24:1893-1900, 2003
- 25) Tsai TT, Chen WJ, Lai PL, Chen LH, Niu CC, Fu TS, et al. Polymethylmethacrylate cement dislodgment following percutaneous vertebroplasty: a case report. *Spine (Phila Pa 1976)* 28:E457-E460, 2003
- 26) Watts NB, Harris ST, Genant HK. Treatment of painful osteoporotic vertebral fractures with percutaneous vertebroplasty or kyphoplasty. *Osteoporos Int* 12:429-437, 2001
- 27) Weill A, Chiras J, Simon JM, Rose M, Sola-Martinez T, Enkaoua E. Spinal metastases: indications for and results of percutaneous injection of acrylic surgical cement. *Radiology* 199:241-247, 1996