

Undiagnosed Anaplastic Ganglioglioma Resulting in the Sudden Unexpected Death of a Young Woman

Moon-Young Kim^{1,2},
Hanna Kim^{1,2}, Sung-Hye Park²,
Soong Deok Lee^{1,3}

¹Department of Forensic Medicine,
Seoul National University College
of Medicine, Seoul, Korea,

²Department of Pathology, Seoul
National University Hospital,
Seoul, Korea, ³Institute of Forensic
Science, Seoul National University
College of Medicine, Seoul, Korea

Received: July 18, 2015
Revised: August 4, 2015
Accepted: August 20, 2015

Correspondence to

Soong Deok Lee
Department of Forensic Medicine, Seoul
National University College of Medicine,
103 Daehak-ro, Jongno-gu, Seoul
03080, Korea
Tel: +82-2-740-8359
Fax: +82-2-764-8340
E-mail: sdlee@snu.ac.kr

Intracranial neoplasms usually have definitive symptoms, causing a need for medical intervention, but a few cases result in sudden unexpected death even before diagnosis. In these cases, autopsy or post-mortem imaging may be the only way of identifying the existence of a tumor, so investigators or forensic specialists who participate in the post-mortem inspection should be aware of these possibilities. We report on a case of a 26-year-old woman without any medical history found dead in her home. A 5-cm intraventricular tumor was found during autopsy, which was histologically consistent with anaplastic ganglioglioma a very rare type of neuroglial tumor with the potential for malignant behavior. The tumor showed the characteristic features of anaplastic ganglioglioma, such as increased cellularity, a high Ki-67 proliferative index, and necrosis. There were signs of increased intracranial pressure, including flattened gyri and dilated ventricles, which led to the conclusion that this brain tumor was the cause of death.

Key Words: Unknown primary neoplasms; Brain neoplasms; Ganglioglioma;
Cause of death

Introduction

Intracranial neoplasm is a rare cause of death; most autopsy studies have reported the incidence as being under 1% [1]. Typically, the patient experiences related symptoms for a long time owing to the impaired brain function of the involved area. However, these tumors may not show any definitive manifestations of intracranial lesions. When undiagnosed, the patient

experiences only mild symptoms for a relatively short period of time and rapidly progresses to death. In these cases, an autopsy, or at least post-mortem imaging tools such as computed tomography, is needed to diagnose the tumor and determine the cause of death. Although this particular type of sudden unexpected death has been reported, herein, we report a case due to a very rare type of brain tumor-anaplastic ganglioglioma. We share this experience and discuss a case of sudden unexpected death due to an undiagnosed

intracranial neoplasm.

Case Report

A 26-year-old woman was found unconscious by her live-in partner. He called the emergency services who confirmed that she had already died before they arrived at the scene despite cardiopulmonary resuscitation (CPR) being performed by the live-in partner. He stated that she had not felt well for the past 1 or 2 weeks and was staying at home from work that day. They fell asleep together after she took her medications. A toxicology test revealed that these medications included metoclopramide, chlorpheniramine, and ketorolac; their levels were all within therapeutic range. Any tested toxic materials were not detected, and the level of ethyl alcohol was under 0.01%.

External and internal examination showed only mild perioral abrasion and small hemorrhages in the left lateral neck, right chest, and cardiac surface, which was consistent with CPR-related bruises. The brain showed flattened gyri (Fig. 1A) but there was no definitive intracranial hemorrhage. A flesh-colored soft tumor was exposed at the base of the brain, just in front of the optic chiasm. The size of the tumor was about $5 \times 4 \times 3$ cm, filling more than half of the right lateral and third ventricle. The tumor exhibited intratumoral hemorrhage and necrosis (Fig. 1B). Microscopically, the tumor showed a relatively clear border (Fig. 2A) with mixed differentiation of the neu-

ronal and glial components (Fig. 2B). Some eosinophilic granular bodies and radial scar-like fibrotic foci with irregular collagen deposition were observed, which implied a long-standing ganglioglioma. Notably, there were multifocal areas of high cellularity (Fig. 2C) and Ki-67 proliferative index (Fig. 2D) accompanying necrosis (Fig. 2E), characteristic features of anaplastic transformation. Other organs in the rest of the body presented no abnormal findings.

The brain tumor, histologically consistent with anaplastic ganglioglioma, was thought to have a mass effect because of the flattened gyri and dilated ventricles, implying that there was increased intracranial pressure. We concluded that this brain tumor was the cause of death.

Discussion

Included in the World Health Organization (WHO) grade I category, ganglioglioma is a rare type of mature neuronal tumor with a glial element and relatively benign behavior. The glial component resembles a low-grade astrocytoma, whereas the neuronal component consists of ganglion cells with dysmorphic morphology, such as pleomorphism, clustering, or multinucleation. Eosinophilic granular bodies, perivascular lymphocytic cuffing, and fibrosis with collagen deposition are other histologic features of ganglioglioma.

A small subset of these tumors is known to have the

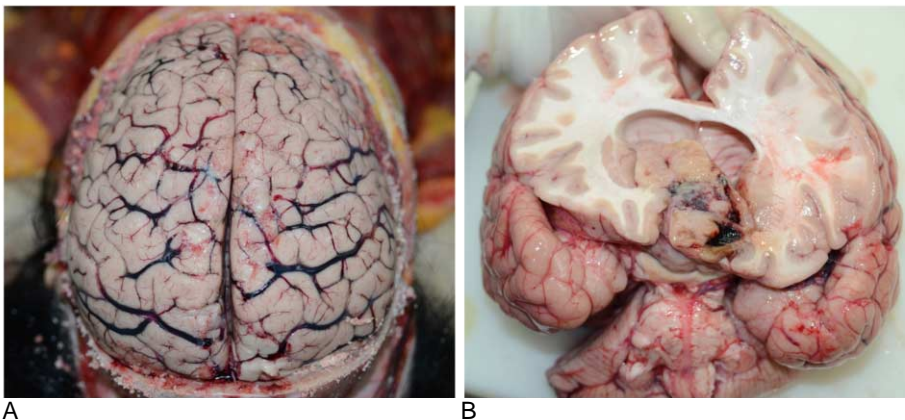


Fig. 1. (A) Flattened gyri of the cerebral cortex are observed, implying increased intracranial pressure. (B) The tumor was located in the right lateral and third ventricle, resulting in ventricular dilation. The cut surface of the tumor shows focal hemorrhage and necrosis.

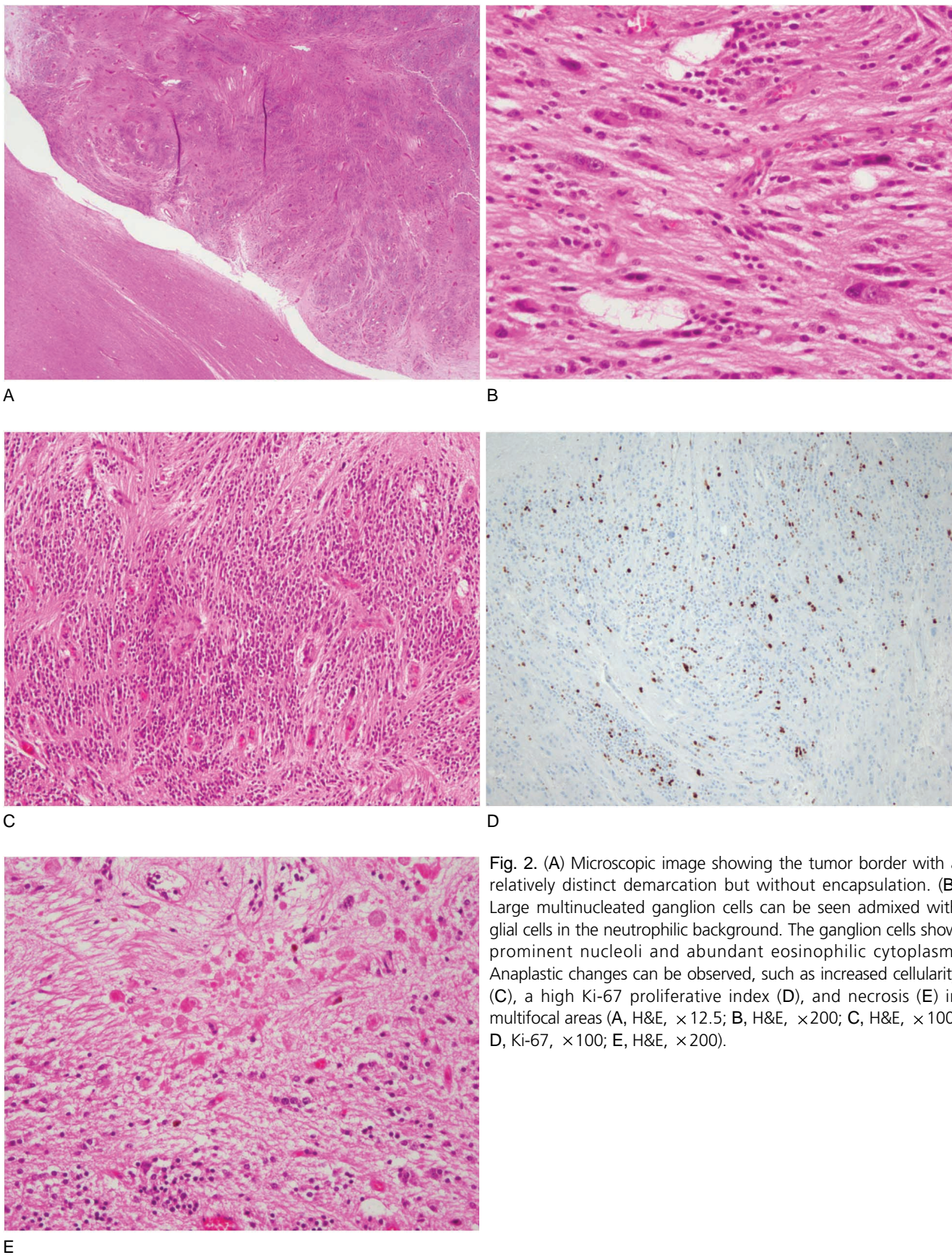


Fig. 2. (A) Microscopic image showing the tumor border with a relatively distinct demarcation but without encapsulation. (B) Large multinucleated ganglion cells can be seen admixed with glial cells in the neutrophilic background. The ganglion cells show prominent nucleoli and abundant eosinophilic cytoplasm. Anaplastic changes can be observed, such as increased cellularity (C), a high Ki-67 proliferative index (D), and necrosis (E) in multifocal areas (A, H&E, $\times 12.5$; B, H&E, $\times 200$; C, H&E, $\times 100$; D, Ki-67, $\times 100$; E, H&E, $\times 200$).

potential for malignant transformation, mostly in the glial component. Today, these tumors are generally referred to as WHO grade III anaplastic gangliogliomas. They are histologically characterized by high cellularity, increased mitotic activity, and necrosis, with an increased incidence of local recurrence and metastasis that results in a more unfavorable prognosis than their benign counterpart.

Thus far, the largest study about anaplastic ganglioglioma was reported by Selvanathan et al. [2], analyzing the clinicopathologic characteristics and prognostic factors in 58 patients from Surveillance, Epidemiology, and End Results (SEER) cancer registry data for 35 years. The 5-year survival rate was 63% and the median overall survival was 28.5 months despite therapeutic intervention. The prognosis improved when the tumor was completely resected [2].

However, the woman in this case had never been diagnosed with a brain tumor; her tumor was only revealed after the autopsy was performed. A few cases of sudden death due to brain tumor have been reported globally in individuals of all ages. The prevalence of undiagnosed central nervous system tumors during

autopsy was reported as ranging from 0.02% to 2.7% [1]. Such variance may be due to differences in national or regional policies regarding forensic autopsy or a national healthcare system that has continuously advanced for the last few decades.

Increased intracranial pressure is the most important mechanism of sudden unexpected death due to undiagnosed intracranial neoplasm, induced by (1) the mass effect of the tumor itself, (2) secondary hydrocephalus due to large tumor volume or obstruction of the cerebrospinal fluid pathway, or (3) acute hemorrhage [3,4]. Impaired brain stem function caused by primary involvement of the tumor or secondary compression may also contribute to death through disordered respiratory control [5]. Presenting signs and symptoms, if experienced, often include headache, vomiting, acute loss of consciousness, and, in children, lethargy. In a few cases, epilepsy and psychiatric behaviors were also observed [3–5].

Both malignant and benign tumors maybe the cause of sudden unexpected death. Matschke and Tsokos [6] reported that among 83 cases of sudden unexpected death due to undiagnosed brain tumor, 55 cases

Table 1. Summarized cases of sudden unexpected death due to intracranial neoplasm reported in Korea for the past 10 years

Author	Sex	Age (yr)	Medical history	Premortem symptoms or signs	Tumor size (cm)	Tumor location	Histologic diagnosis	WHO grade	Associated intracranial change
Huh et al. (2008) [7]	F	56	Asymptomatic hypertension	N/A	5.5	Olfactory groove	Meningioma, meningothelial type	I	Edematous brain
Kim et al. (2009) [8]	F	6	Mental retardation	Vomiting, seizure	6.5	Anterior wall of the left lateral ventricle	Ganglioglioma	I	Edematous brain, dilated left ventricle
Kim et al. (2009) [9]	M	2	N/A	Vomiting, dyspnea, LOC, seizure	N/A	Cerebellar vermis (extending to the third, fourth, and lateral ventricles)	Medulloblastoma	IV	Severe brain edema, hydrocephalus
Kim et al. (2013) [10]	F	51	Depression, Hyperlipidemia	Small amount of vomitus	5.5	Olfactory groove	Meningioma, meningothelial type (with brain invasion)	II	Edematous brain, flattened gyri, tonsillar herniation
Present case	F	26	Previously healthy	N/A	5	In front of the optic chiasm (extending to the right lateral and third ventricles)	Anaplastic ganglioglioma ventricles	III	Flattened gyri, dilated

WHO, World Health Organization; F, female; N/A, not available; M, male; LOC, loss of consciousness.

involved benign tumors, including 2 cases of ganglioglioma, and 28 cases involved malignancy. In the last 10 years, 4 cases of sudden unexpected death due to intracranial neoplasm were reported in Korea [7–10]. Two cases involved meningothelial meningioma and, interestingly, both tumors were about 5 cm, located in the olfactory groove, and occurred in middle-aged women in their fifties [7,10]. Two pediatric cases had common symptoms of vomiting, initially diagnosed as a gastrointestinal problem. A 6-year-old girl had a 6.5-cm benign ganglioglioma located in the left lateral ventricle, with acute intratumoral hemorrhage and ventricular dilatation similar to our case [8]. A 2-year-old boy died from medulloblastoma accompanied by severe brain edema [9]. These cases are summarized in Table 1.

Most intracranial neoplasms have specific symptoms of increased intracranial pressure or focal neurologic deficit associated with the involved area. However, some of these tumors have a short duration of symptoms before death or unlocalized and vague signs, similar to the presented case. Poor accessibility to the healthcare system may influence the delayed diagnosis. When the deceased presents with a concurrent medical condition such as cardiovascular disease, the forensic pathologist should decide whether the undiagnosed intracranial neoplasm contributed to his or her death. Careful history taking for any signs or symptoms exhibited before death will provide important information to reach a decision. Gross and microscopic findings that reveal the presence of high intracranial pressure, such as flattened gyri, parenchymal edema, acute hemorrhage, ventricular dilatation, and brain herniation (midline shifting, transtentorial or transforaminal herniation, and distortion of the brainstem), should be investigated. Furthermore, the location of the tumor itself could be associated with the patterns of signs or symptoms and the contributiveness to the death.

An unexpected death may raise suspicion about the involvement of surrounding people who may be innocent. Without identification of the cause of death,

human rights may be abused and the investigators may waste their time and effort undergoing unnecessary investigation processes. In our case, without the autopsy of the deceased, her live-in partner may have been blamed for the unclear circumstances of her death by the bereaved family. In addition, as with other medical conditions, it benefits bereaved families to gain knowledge about their family member's medical history for the prevention and prediction of hereditary syndromes. In the case of sudden unexpected death, an examination of the deceased's history and a cautious post-mortem inspection should be undertaken to consider the possibility of undiagnosed medical conditions, including rare intracranial neoplasms.

Conflicts of Interest

No potential conflict of interest relevant to this article was reported.

Acknowledgments

This study was supported by the SNUH Educational Research Consulting Program.

References

1. Vougiouklakis T, Mitselou A, Agnantis NJ. Sudden death due to primary intracranial neoplasms: a forensic autopsy study. *Anticancer Res* 2006;26:2463-6.
2. Selvanathan SK, Hammouche S, Salminen HJ, et al. Outcome and prognostic features in anaplastic ganglioglioma: analysis of cases from the SEER database. *J Neurooncol* 2011;105:539-45.
3. DiMaio SM, DiMaio VJ, Kirkpatrick JB. Sudden, unexpected deaths due to primary intracranial neoplasms. *Am J Forensic Med Pathol* 1980;1:29-45.
4. Elgamal EA, Richards PG. Sudden death in children due to intracranial mass lesion. *Childs Nerv Syst* 2006;22:305-9.
5. Eberhart CG, Morrison A, Gyure KA, et al. Decreasing incidence of sudden death due to undiagnosed primary central nervous system tumors. *Arch Pathol Lab Med* 2001;125:1024-30.
6. Matschke J, Tsokos M. Sudden unexpected death due to undiagnosed glioblastoma: report of three cases and review of the literature. *Int J Legal Med* 2005;119:280-4.
7. Huh GY, Kim KH, Ahn YW, et al. Sudden death due to undiagnosed intracranial meningioma: a case report. *Korean J Leg Med* 2008;32:150-2.

8. Kim KH, Ahn YW, Jo GR, et al. Sudden death due to a ganglioglioma. *Korean J Leg Med* 2009;33:126-9.
9. Kim SH, Kim TG, Seo IS, et al. Sudden unexpected death due to medulloblastoma. *Korean J Leg Med* 2009;33:130-2.
10. Kim JH, Cho MH, Kim H, et al. Sudden unexpected death caused by olfactory groove meningioma: a case report. *Korean J Leg Med* 2013;37:208-11.