

# The Efficacy of Connexin 43 Expression in the Myocardium as an Early Ischemic Marker in Forensic Autopsy

Jae Woo Ahn, Gi Yeong Huh

*Department of Forensic Medicine,  
Pusan National University School  
of Medicine, Yangsan, Korea*

Received: January 20, 2015  
Revised: February 1, 2015  
Accepted: February 13, 2015

## Correspondence to

Gi Yeong Huh  
Department of Forensic Medicine, Pusan  
National University School of Medicine,  
49 Busandaehak-ro, Mulgeum-eup,  
Yangsan 626-870, Korea  
Tel: +82-51-510-8058  
Fax: +82-51-510-8143  
E-mail: gyhuh@pusan.ac.kr

The postmortem diagnosis of ischemic heart disease is sometimes difficult for forensic pathologists especially when microscopic ischemic change in the myocardium is not detected at the early stages of ischemic injury by conventional staining techniques. Connexin 43 (Cx43) is a gap junction protein in human myocardium, which is phosphorylated and localized to the intercalated discs in the normal cardiac muscles. However, during ischemia and hypoxia, total Cx43 (tCx43) undergoes progressive dephosphorylation and concomitant accumulation of non-phosphorylated Cx43 (npCx43) at the lateral cell borders. This study was aimed to evaluate the efficacy of the immunohistochemical expression of Cx43 in the myocardium as an early ischemic marker in forensic autopsy. The study group consisted of 24 cases listing patients who died of ischemic heart disease (IHD) with severe coronary atherosclerosis that showed no myocardial pathology. Cases of sudden death of individuals from non-IHD (n=16) were used as controls. The survival times in both IHD and non-IHD groups were within 24 hours of the onset of angina symptoms, related injury, or the event for the cause of death. There was a statistically significant difference in tCx43 and npCx43 immunopositivity in the IHD group due to their expression patterns. In the IHD group, the redistribution of Cx43 expression from the intercalated discs to the lateral cell borders occurred more frequently than in the non-IHD group. In conclusion, the different expression patterns of tCx43 and npCx43 in the myocardium in IHD could be used as adjunctive ischemic markers.

**Key Words:** Connexin 43; Immunohistochemistry; Myocardial ischemia;  
Forensic pathology; Autopsy

## Introduction

Sudden cardiac death is frequently encountered in forensic practice. In Korea, around 15% of all forensic autopsy cases are attributed to ischemic heart disease (IHD), including acute myocardial infarction [1]. However, the postmortem diagnosis of IHD is sometimes very difficult for forensic pathologists when microscopic ischemic changes in the myocardium are not detected at the early stages of

myocardial infarction by conventional staining techniques [2]. No definitive method has yet been developed for this postmortem diagnosis. However, various techniques, including special stain, enzyme histochemistry, immunohistochemistry, fluorescent methods, and electron microscopy, have been studied with the aim of finding specific ischemic evidence in the myocardium. For practical use in immunohistochemistry, some plasma and cellular markers like myoglobin, cardiac troponin I, fibronectin, desmin, C5b-9 complex, etc. have been considered. However,

there are limitations of these markers due to their sensitivity, specificity, and reproducibility. Recently the immunohistochemically-focused study of potential early ischemic markers has extended to gap junction molecules.

Connexin 43 (Cx43) is a phosphoprotein that is a major gap junction protein in human cardiac myocytes of the ventricle and regulates gap-junction intercellular communication [3]. In normal cardiac muscle, Cx43 is phosphorylated and localized to the intercalated discs. However, harmful stimuli such as ischemia, hypoxia, and hypothermia induce dephosphorylation and redistribution of Cx43 to the cytoplasm and/or lateral cell borders of cardiomyocytes [4,5]. Beardslee et al. [4] reported that during ischemia, total Cx43 (tCx43) undergoes progressive dephosphorylation and concomitant accumulation of non-phosphorylated Cx43 (npCx43).

In animal models, dephosphorylation and redistribution of Cx43 are early signs of cardiac injury after hypoxia [6,7]. These results suggest that the expression of Cx43 in the heart could be a potential ischemic marker for practical diagnostic application. However, most studies of Cx43 redistribution after ischemic and hypoxic injury have been performed in animal models, not human myocardium. Therefore, in our study we aimed to evaluate the efficacy of immunohistochemical expression of Cx43 in the myocardium as an early ischemic marker in forensic practice.

## Materials and Methods

### 1. Materials

The study cohort consisted of patients who died of IHD due to severe coronary atherosclerosis of the left anterior descending branch that showed no myocardial pathology (IHD group,  $n=24$ ; 22 males and 2 females; aged 35–76 years; median age, 53.5 years). The control groups consisted of individuals who died suddenly from non-ischemic heart disease (non-IHD group,  $n=16$ ; 13 males and 3 females; aged

21–75 years; median age, 53.0 years). The survival times in both IHD and non-IHD groups were within 24 hours of the onset of angina symptoms, related injury, or the event that led to their death. Survival times were calculated according to the hospital and police records. The study and control groups were selected from the cadavers that underwent autopsy within 24 hours of postmortem at the Institute of Forensic Medicine, Pusan National University School of Medicine between 2010 and 2011.

The causes of death in the non-IHD group included head injury ( $n=4$ ), multiple organ injury ( $n=2$ ), hypovolemic shock ( $n=2$ ), pulmonary thromboembolism ( $n=2$ ), tetrodotoxin poisoning ( $n=1$ ), phosphamidon poisoning ( $n=1$ ), oxygen deficiency ( $n=1$ ), intracerebral hemorrhage ( $n=1$ ), anaphylactic shock ( $n=1$ ), and ligature strangulation ( $n=1$ ).

## 2. Methods

### (1) Histological and immunohistochemical analyses

For histological and immunostaining of tissue specimens, routine heart sections (anterior wall of the

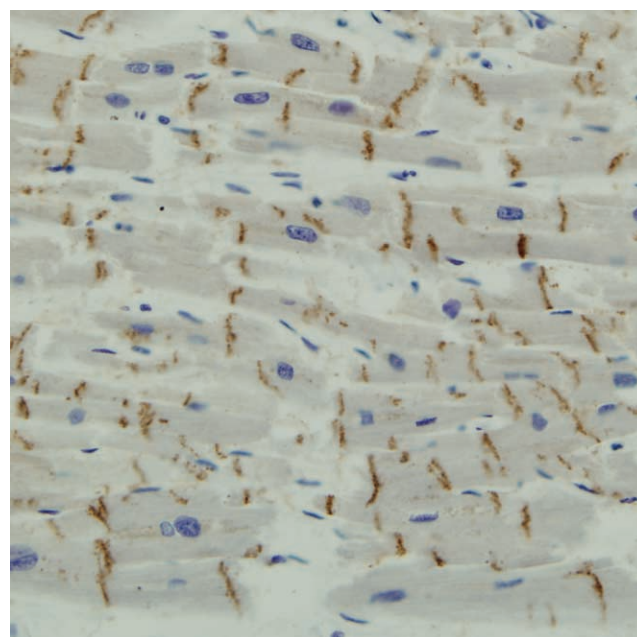


Fig. 1. Immunopositivity for total connexin 43 (Cx43) was present in the myocardium only at the intercalated discs (intercalated disc pattern) in the case of the ischemic heart disease group. Performed using antibody Cx43 detection, with visualization using the polymer method, and H&E ( $\times 200$ ).

left ventricle) were taken during autopsy and fixed in 10% formaldehyde in phosphate-buffered saline (pH 7.4), embedded in paraffin, and then sectioned at a thickness of 4  $\mu$ m. First, a standard hematoxylin and eosin (H&E) staining was performed. Immunostaining was performed using the avidin-biotin complex (ABC) method. The primary antibodies used were rabbit polyclonal anti-Cx43 antibody (1:2,000, Sigma-Aldrich, St. Louis, MO, USA), detecting both phosphorylated Cx43 and npCx43, and mouse monoclonal anti-npCx43 antibody (1:100, Life Technologies, Frederick, MD, USA), detecting only npCx43. Then, tissue endogenous peroxidase was blocked by incubation with peroxidase block for 30 minutes, and subsequently the sections were incubated with enzyme retrieval 0.1% trypsin for 30 minutes at 37°C, followed by 10% blocking serum for 30 minutes. Following overnight incubation at room temperature, immunoreactions were visualized using the polymer method (Vectastain ABC kits, PK-4000, Vector Laboratories, Burlingame, CA, USA), and later color development was carried out with 3,3'-

diaminobenzidine tetrahydrochloride (DAB) and counterstaining with hematoxylin.

Histological evaluation was performed on the routine H&E sections, to observe whether there was myocardial pathology in the cardiac tissue or not, and focused on the presence of definite ischemic injury.

Immunopositivity was considered to be present when linear or intermittent brown granular deposits were visualized predominantly along the intercalated discs and lateral cell borders, irrespective of intensity and cytoplasmic staining. Immunoreaction patterns were divided into intercalated disc patterns (ID pattern, when confined to the intercalated discs) (Fig. 1) and redistribution patterns (R pattern, when immunopositivity was shown to extend to lateral cell borders) (Figs. 2, 3). The immunopositivity was mostly evaluated on the longitudinal sections of the myocardial fibers and a more advanced pattern into lateral cell borders was considered as the final pattern if there was a regional difference in intensity on an individual slide.

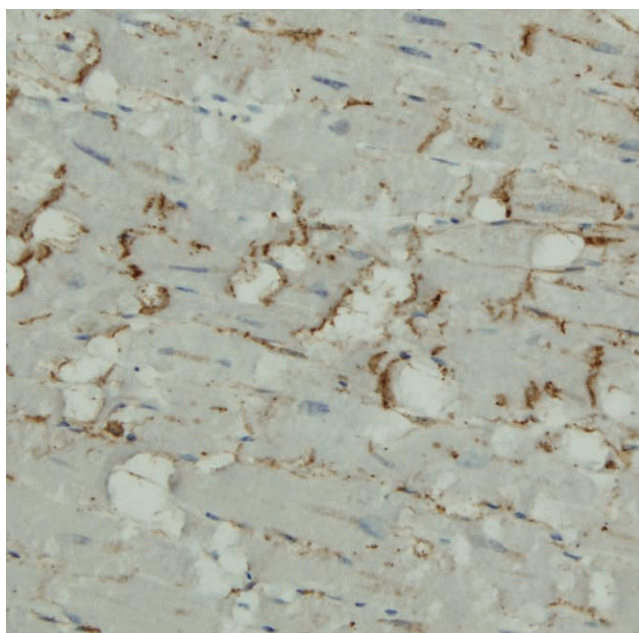


Fig. 2. Immunopositivity for non-phosphorylated connexin 43 (Cx43) was present in the myocardium at both the intercalated discs (intercalated disc pattern) and lateral cell borders (redistribution pattern) in the case of the ischemic heart disease group. Performed using antibody Cx43 detection, with visualization using the polymer method, and H&E ( $\times 200$ ).

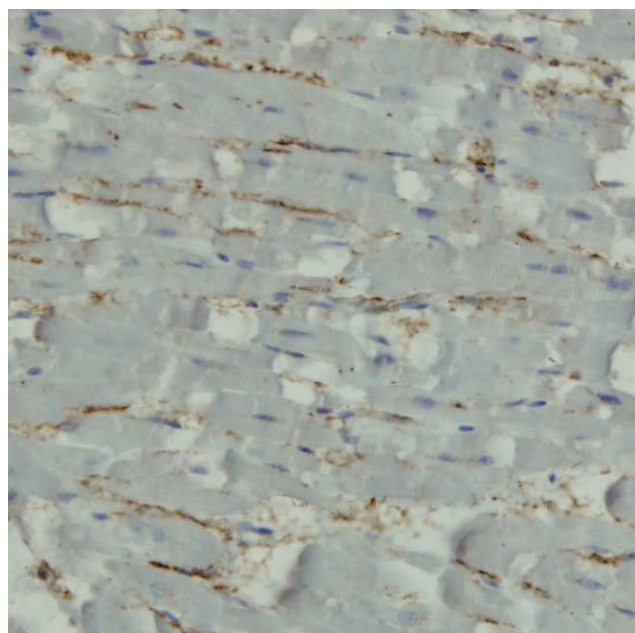


Fig. 3. Immunopositivity of non-phosphorylated connexin 43 (Cx43) was present in the myocardium only at the lateral cell borders (redistribution pattern) in the case of the ischemic heart disease group. Performed using antibody Cx43 detection, with visualization using the polymer method, and H&E ( $\times 200$ ).

### 3. Statistical analysis

The chi-square test was used to analyze the difference of tCx43 and npCx43 expression in and between both the IHD and non-IHD groups. A P-value of  $<0.05$  was considered statistically significant. Statistical analysis was performed using the SPSS ver. 12.0 (SPSS Inc., Chicago, IL, USA).

## Results

The immunohistochemical expression of tCx43 and npCx43 was present to some degree in the myocardium of all individuals in both the IHD and also the non-IHD group. In IHD group, npCx43 expression was present in 7 cadavers as ID pattern and 17 cadavers as R pattern, among the total 24 cases, while tCx43 expression was present in 14 cadavers as the ID pattern and 10 cadavers as the R pattern (Table 1). There was significant difference in the expression of tCx43 and npCx43 in the IHD group for the immunopositivity pattern ( $P < 0.05$ ). In the non-IHD group, npCx43 expression was present in 5 cadavers as ID pattern and 11 cadavers as R pattern out of 16 cases in total, whereas tCx43 expression in 10 cadavers was present as ID pattern and in 6

cadavers as R pattern (Table 2). There was no significant difference in the expression of tCx43 and npCx43 in the non-IHD group. Moreover, there was no statistically significant difference in individual expression of tCx43 and npCx43 between the IHD and non-IHD groups (Tables 3, 4).

## Discussion

Our results indicate that the redistribution of Cx43 expression, in the non-phosphorylated form, from the intercalated discs to the lateral cell borders occurred most frequently in the IHD group. These findings suggest that this difference in the expression pattern of Cx43 in the myocardium could be used as a potential postmortem early ischemic marker.

The efficacy of immunohistochemical markers of early ischemic injury in the myocardium has been studied for the diagnosis of early stage myocardial infarction. For this purpose, several plasma and cellular markers have already been investigated. Among them, myoglobin, cardiac troponin I, fibronectin, desmin, and the C5b-9 complex have been particularly well studied [8,9]. However, it is very difficult to apply them in practice due to the lack

**Table 1.** Distribution of total connexin 43 (tCx43) and non-phosphorylated Cx43 (npCx43) expression in the myocardium of the ischemic heart disease group categorized by the pattern of immunopositivity

Type of Cx43	Pattern of immunopositivity		P-value
	Intercalated disc	Redistribution to lateral cell border	
tCx43	14	10	0.042
npCx43	7	17	

**Table 2.** Distribution of total connexin 43 (tCx43) and non-phosphorylated Cx43 (npCx43) expression in the myocardium of the non-ischemic heart disease group categorized by the pattern of immunopositivity

Type of Cx43	Pattern of immunopositivity		P-value
	Intercalated disc	Redistribution to lateral cell border	
tCx43	10	6	0.077
npCx43	5	11	

**Table 3.** Differences in total connexin 43 (tCx43) expression in the myocardium between the ischemic heart disease (IHD) and non-IHD group categorized by the pattern of immunopositivity

Group	Pattern of immunopositivity		P-value
	Intercalated disc	Redistribution to lateral cell border	
IHD	14	10	0.792
Non-IHD	10	6	

**Table 4.** Difference in non-phosphorylated connexin 43 (npCx43) expression in the myocardium between the ischemic heart disease (IHD) and non-IHD group categorized by the pattern of immunopositivity

Group	Pattern of immunopositivity		P-value
	Intercalated disc	Redistribution to lateral cell border	
IHD	7	17	0.888
Non-IHD	5	11	

of reproducibility, sensitivity, and specificity of these methods. Recently the immunohistochemical study of early ischemic markers has extended to the consideration of gap junction molecules.

Gap junction proteins provide the intercellular communication necessary to facilitate direct communication among adjacent cells by allowing the passage of ions and small metabolites through these gap junctions. Gap junctions exist in nearly every mammalian cell type and their ubiquitous distribution may be due to their composition of connexin family transmembrane proteins, consisting of 20 members in the mice and 21 members in humans [3]. The most ubiquitously expressed connexin is Cx43, which is expressed in at least 35 cell types including cardiomyocytes, keratinocytes, astrocytes, endothelial cells, and smooth muscle cells [3].

Previous studies have shown that Cx43 in normal cardiac muscle is concentrated in gap junction plaques at the intercalated discs. When hypoxia is induced, Cx43 is redistributed to the lateral cell borders, longer maintaining its concentration at the intercalated discs [4]. In addition, the diffuse signal for Cx43 along the non-disc region was only detected for the dephosphorylated form, while ischemia caused a redistribution of total Cx43 from the intercalated discs to the lateral borders of myocytes [7]. The redistribution of Cx43 expression to the lateral cell borders in cadavers when IHD was the cause of death was more frequent than for non-IHD group [4,7]. The present study showed immunohistochemical findings similar to those that have been exhibited in previous reports that demonstrated the pattern of Cx43 positivity due to ischemic injury of the myocardium in animal models.

In spite of a plethora of animal studies having been performed regarding the association of Cx43 in myocardial ischemia and hypoxia, data for this association in humans is lacking in publication. Recently, a study similar to ours reported that, using human autopsy material, the npCx43 positivity score in myocardial infarction and acute IHD without

apparent myocardial necrosis was higher in the cytoplasm than the intercalated discs, indicating redistribution due to myocardial ischemia and the authors suggested that Cx43 could be a potential early ischemic marker when combined with C5b-9 [10].

Another important finding of our study was that, there was a no significant difference in individual expression patterns of tCx43 and npCx43 in the IHD and non-IHD groups. This finding indicates that tCx43 and npCx43 have little specificity as an early ischemic marker. We hypothesize two possible explanations for the reasons as to why tCx43 and npCx43 expression patterns were similar in both the IHD and non-IHD group. The first is that Cx43 is reversibly dephosphorylated and is rephosphorylated during hypoxia and reoxygenation according to nonlethal fluctuations in cellular ATP [5], which could be seen in early stage IHD as well as in the non-IHD groups. The second is that non-IHD group in our study also had some degree of global hypoxia that was similar to that in the IHD groups during the perimortem period, resulting in the redistribution of Cx43 expression in the myocardium, thus mimicking changes in the IHD group.

The limitation of this study was that there was a small sample size for the control group due to a lack in specification of the cause of death and a lack of evaluation of the exact survival time of these individuals, therefore the critical time of redistribution of Cx43 expression could not be assessed. Moreover, it would have been advantageous to perform a comparative study with other potential early ischemic markers, particularly other gap junction proteins, such as zonula occludens-1, to strengthen the results and our deductions [10].

In conclusion, the redistribution pattern of Cx43 expression in the myocardium of patients, who died of IHD, could be applied as a postmortem adjunctive early ischemic marker, although some limitations are apparent in the individual differentiation of IHD from non-IHD groups.



### Conflicts of Interest

No potential conflict of interest relevant to this article was reported.

### Acknowledgments

This work was supported by a 2-Year Research Grant of Pusan National University.

### References

1. Na JY, Park JP, Park HJ, et al. The statistical analysis on legal autopsy performed in Korea during 2012 year. *Korean J Leg Med* 2013;37:198-207.
2. Saukko P, Knight B. *Knight's forensic pathology*. 3rd ed. London: Arnold; 2004. p. 495-502.
3. Laird DW. Life cycle of connexins in health and disease. *Biochem J* 2006;394:527-43.
4. Beardslee MA, Lerner DL, Tadros PN, et al. Dephosphorylation and intracellular redistribution of ventricular connexin43 during electrical uncoupling induced by ischemia. *Circ Res* 2000;87:656-62.
5. Turner MS, Haywood GA, Andreka P, et al. Reversible connexin 43 dephosphorylation during hypoxia and reoxygenation is linked to cellular ATP levels. *Circ Res* 2004;95:726-33.
6. Hatanaka K, Kawata H, Toyofuku T, et al. Down-regulation of connexin43 in early myocardial ischemia and protective effect by ischemic preconditioning in rat hearts in vivo. *Jpn Heart J* 2004;45:1007-19.
7. Matsushita S, Kurihara H, Watanabe M, et al. Alterations of phosphorylation state of connexin 43 during hypoxia and reoxygenation are associated with cardiac function. *J Histochem Cytochem* 2006;54:343-53.
8. Ortmann C, Pfeiffer H, Brinkmann B. A comparative study on the immunohistochemical detection of early myocardial damage. *Int J Legal Med* 2000;113:215-20.
9. Campobasso CP, Dell'Erba AS, Addante A, et al. Sudden cardiac death and myocardial ischemia indicators: a comparative study of four immunohistochemical markers. *Am J Forensic Med Pathol* 2008;29:154-61.
10. Kawamoto O, Michiue T, Ishikawa T, et al. Immunohistochemistry of connexin43 and zonula occludens-1 in the myocardium as markers of early ischemia in autopsy material. *Histol Histopathol* 2014;29:767-75.