

## Blood Chimerism in a Dizygotic Dichorionic Pregnancy

Ja-Hyun Jang, M.D.<sup>1</sup>, Haiyoung Jung, M.D.<sup>1</sup>, Jong-Hwa Kim, M.D.<sup>2</sup>, Won-Soon Park, M.D.<sup>3</sup>, and Sun-Hee Kim, M.D.<sup>1</sup>

Departments of Laboratory Medicine & Genetics<sup>1</sup>, Obstetrics and Gynecology<sup>2</sup>, and Pediatrics<sup>3</sup>, Samsung Medical Center, Sungkyunkwan University School of Medicine, Seoul, Korea

Blood chimerism in twins is known to occur through the transfer of hematopoietic stem cells between the fetuses via a common placenta. We present a case of blood chimerism in a dizygotic dichorionic twin pregnancy. The female twin was delivered at 34 weeks of gestation, and the male twin was stillborn. Pathologic examination confirmed dichorionic diamniotic placentas. The karyotype of the female child was obtained using peripheral blood sample, and it revealed a mixture of 46,XX and 46,XY cells (chi 46,XY[13]/46,XX[7]). FISH analysis performed on the buccal cells by using CEP X/Y probe (Abbott Molecular Inc., USA) revealed 100% XX signals (nuc ish Xcen(DXZ1x2)[500]). Gross examination of the external genitalia and abdominal ultrasonography revealed no definitive abnormal findings in relation to sex differentiation. When XX/XY chimerism is present in blood lymphocytes, careful examination of external genitalia and reproductive organs and further studies are required to detect chimerism in non-hematopoietic tissues. This is a rare case of blood chimerism in dichorionic placentas, in contrast to those in monochorionic placentas. (*Korean J Lab Med* 2010;30:521-4)

**Key Words :** *Blood chimerism, Dizygotic dichorionic twins, Vascular anastomosis*

### INTRODUCTION

Chimerism refers to a condition in which an organism has different cell lines that originated in different zygotes. Chimerism is different from mosaicism, which refers to a condition in which different cell lines originate from the same zygote. The presence of 2 different cell lines in a person is generally presumed to be mosaicism since mosaicism is much more common than chimerism. However, if a blood karyotype of an individual reveals an admixture of cells with 46,XX and 46,XY, the possibility of chimerism increases. Chimerism is an extremely rare

event in humans, although it is common in animals. Herein, we report a case of chimerism that is limited to blood lymphocytes in a dizygotic dichorionic twin pregnancy; we also report the clinical implications and laboratory evaluation of the case.

### CASE REPORT

A 33-yr-old woman pregnant with twins was referred to an obstetrics clinic with the finding of fetal heart anomalies at 28 weeks of gestation. The pregnancy was achieved via in vitro fertilization (IVF) with intracytoplasmic sperm injection according to a protocol followed in a private fertility clinic. Ultrasonographic examinations revealed that one of the twin fetuses (twin A) had cardiomegaly, severe tricuspid valve regurgitation, enlarged right atrium, and a hydrocele, while the other (twin B) was suspected to have intrauterine growth restriction. In addition, the placenta was suspected to be

Received : December 22, 2009

Revision received : June 3, 2010

Accepted : July 21, 2010

Corresponding author : Sun-Hee Kim, M.D.

Department of Laboratory Medicine and Genetics, Samsung Medical Center, Sungkyunkwan University School of Medicine, 50 Irwon-dong, Gangnam-gu, Seoul 135-710, Korea  
Tel : +82-2-3410-2704, Fax : +82-2-3410-2719  
E-mail : sunnyhk@skku.edu

Manuscript No : KJLM10-002

a dichorionic, diamniotic placenta. The fetuses were of different sex, and twin A was larger than twin B.

At 34 weeks of gestation, the patient was admitted to the obstetrics clinic with vaginal spotting and regular contractions. Ultrasound scan performed after admission revealed that twin A had no heart beat, and therefore, labor was induced. The woman delivered a stillborn male child and its female twin (twin B), and refused further evaluation, including an autopsy, of twin A. Twin B had Apgar scores of 7 and 8 at 1 and 5 min, respectively. No structural abnormalities were detected in twin B.

Karyotyping was performed on peripheral blood lymphocytes of twin B; analysis revealed a mixture of 46,XY and 46,XX cells (chi 46,XY[13]/46,XX[7]) (Fig. 1). A FISH study was performed on the buccal cells from twin B by using CEP X/Y probe (Abbott Molecular Inc., Des Plaines, IL, USA), which is specific for the alpha satellite of the X centromere region and satellite III of Yq12. The analysis revealed X-probe signals in 500 interphase cells (nuc ish Xcen(DXZ1x2)[500]) (Fig. 2) with no signals of Y-probes. Pathologic examination of the placenta confirmed a dichorionic, diamniotic placenta. The baby showed no abnormalities of the external genitalia, but the uterus was not visible ultrasonography performed at day 26. This finding can be attributed to the under-filling of the child's urinary bladder, which caused difficulty in discriminating her uterus from her bowel. Follow-up ultrasonography performed at day 29 revealed a

uterus-like structure. Another follow-up ultrasound scan was scheduled to be performed after 1 yr to confirm the presence of a uterus. Furthermore, a chromosome study will be repeated to check whether the chimerism is transient or persistent.

## DISCUSSION

When an admixture of cells with 46,XX and 46,XY is detected, it should be determined whether the admixture is present in the entire body or limited to the blood. Blood chimerism is defined as the condition characterized by the presence of cells from at least 2 zygote lineages in only the lympho-hematopoietic system. To distinguish

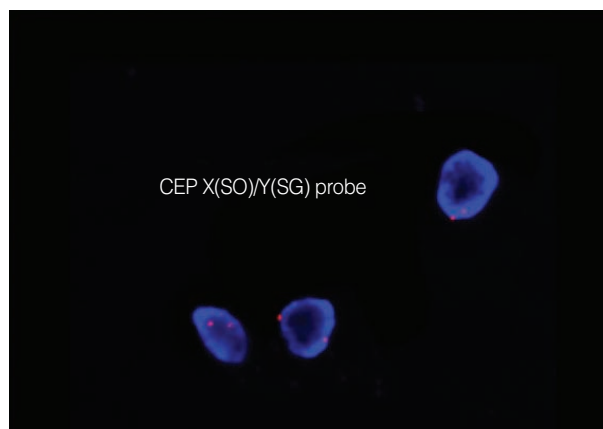


Fig. 2. FISH X/Y showing that all interphase nuclei have XX signals (nuc ish Xcen(DXZ1x2)[500]).

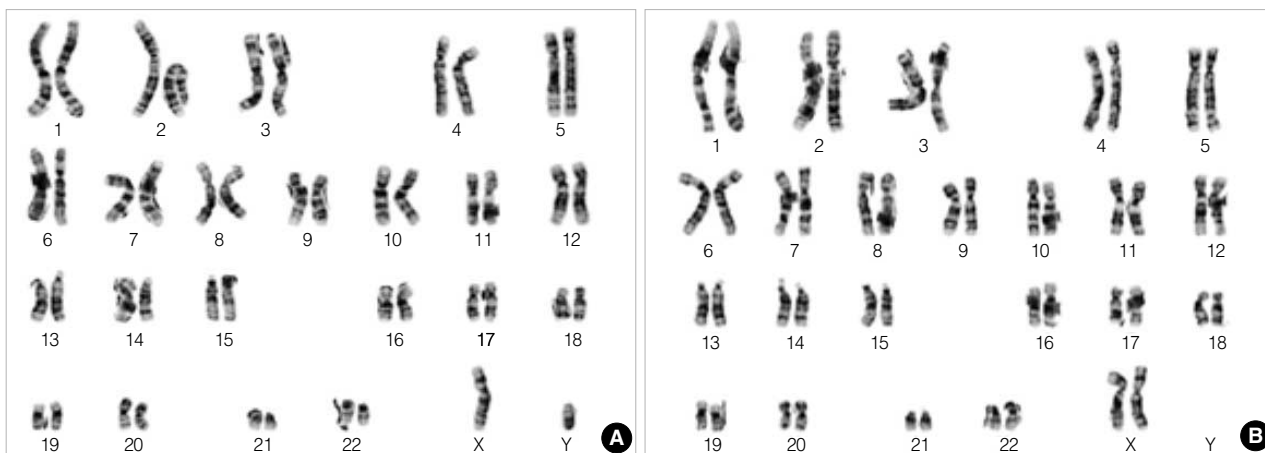


Fig. 1. G-banded karyotype of the patient's peripheral blood showing an admixture of 46,XY (A) and 46,XX (B) (chi 46,XY[13]/46,XX[7]).

whole-body chimerism from blood chimerism, molecular analysis of blood cells and non-hematopoietic tissue (e.g., buccal cells, hair, and nails) by performing PCR and FISH is necessary. The clinical phenotypes of whole-body chimeras may be a normal fertile female [1], intersex disorder [2], or normal males [3]. Individuals with blood chimerism show no abnormality in relation to sexual development [4–6]. Therefore, careful examinations of the external genitalia and reproductive organs as well as further laboratory investigation are important when chimerism is revealed in a blood karyotype.

In twins, chimerism has been reported to result from the transfusion of hematopoietic stem cells between fetuses through vascular anastomoses of placentas during the first trimester. Blood chimerism has been detected in 8% of twins and 21% of triplets [7]. It has been suggested that twins may have long-term blood chimerism postnatally because twins acquire immunotolerance to their sibling's cell type. Sudik et al. [6] reported the case of a 30-yr-old woman with blood chimerism.

Interestingly, the major proportion of XX/XY in blood cells does not necessarily indicate the true genetic cell type [8–10]. Interpretation of cytogenetic findings of twins warrants careful attention since minor cell populations may not be analyzed during conventional cytogenetic analysis. If the missed minor population is the true genetic cell type, the condition can be misdiagnosed as gonadal dysplasia, as in the case reported by Johannsen et al. [11]. Another implication of twin chimerism would be evident in blood group testing. The presence of chimeric blood groups may yield mixed field agglutination in ABO grouping test, thereby making crossmatching more difficult [12].

In this case, the 46,XX/46,XY karyotype was limited to the blood cells, which was consistent with the finding of no definitive abnormality relative to sexual development; however, repeat ultrasonography was necessary. The unusual discovery of a dichorionic placenta in this case should be noted since most previous studies reported cases of blood chimerism from monochorionic rather than dichorionic placentas [4, 10]. In cases in which a

monochorionic placenta occurs in a twin pregnancy, vascular anastomosis is well-described and can lead to blood chimerism as well as twin-twin transfusion syndrome. In contrast, interplacental vascular communications occur only with very rare exceptions in a dichorionic placenta, even though the 2 placentas are completely fused and appear macroscopically inseparable [13]. Phelan et al. reported a case of opposite-sex dizygotic dichorionic twins showing vascular anastomosis and blood chimerism confirmed by injection study [14]. The mechanism underlying blood chimerism was not fully investigated in this study, which can be a limitation of this study, although the most probable explanation is interplacental vascular anastomosis.

In summary, we report a case of 46,XX/46,XY chimerism in dizygotic dichorionic twins. Blood chimerism was confirmed by performing FISH on the buccal cells of the patient. Interestingly, this case is one of the very few cases in which blood chimerism developed from dichorionic and not monochorionic placentas. In addition, the case provided important viewpoints regarding the interpretation of cytogenetic analysis and laboratory investigation in case of blood chimerism in twins of the opposite sex.

## REFERENCES

1. Gencik A, Genciková A, Hrubisko M, Mergancová O. Chimerism 46,XX/46,XY in a phenotypic female. *Hum Genet* 1980;55:407-8.
2. Souter VL, Parisi MA, Nyholt DR, Kapur RP, Henders AK, Opheim KE, et al. A case of true hermaphroditism reveals an unusual mechanism of twinning. *Hum Genet* 2007;121:179-85.
3. Schoenle E, Schmid W, Schinzel A, Mahler M, Ritter M, Schenker T, et al. 46,XX/46,XY chimerism in a phenotypically normal man. *Hum Genet* 1983;64:86-9.
4. Williams CA, Wallace MR, Drury KC, Kipersztok S, Edwards RK, Williams RS, et al. Blood lymphocyte chimerism associated with IVF and monochorionic dizygous twinning: case report. *Hum Reprod* 2004;19:2816-21.
5. Souter VL, Kapur RP, Nyholt DR, Skogerboe K, Myerson D, Ton CC, et al. A report of dizygous monochorionic twins. *N Engl J Med*

- 2003;349:154-8.
6. Sudik R, Jakubiczka S, Nawroth F, Gilberg E, Wieacker PF. Chimerism in a fertile woman with 46,XY karyotype and female phenotype. *Hum Reprod* 2001;16:56-8.
  7. van Dijk BA, Boomsma DI, de Man AJ. Blood group chimerism in human multiple births is not rare. *Am J Med Genet* 1996;61:264-8.
  8. Chown B, Lewis M, Bowman JM. A pair of newborn human blood chimeric twins. *Transfusion* 1963;3:494-5.
  9. Kühl-Burmeister R, Simeoni E, Weber-Matthiesen K, Milde A, Herwartz C, Neppert J, et al. Equal distribution of congenital blood cell chimerism in dizygotic triplets after in-vitro fertilization. *Hum Reprod* 2000;15:1200-4.
  10. Ekelund CK, Skibsted L, Søgaard K, Main KM, Dziegiel MH, Schwartz M, et al. Dizygotic monochorionic twin pregnancy conceived following intracytoplasmic sperm injection treatment and complicated by twin-twin transfusion syndrome and blood chimerism. *Ultrasound Obstet Gynecol* 2008;32:832-4.
  11. Johannsen TH, Lundsteen C, Visfeldt J, Schwartz M, Petersen BL, Byskov AG, et al. Erroneous genetic sex determination of a newborn twin girl due to chimerism caused by foetal blood transfusion. A case report. *Horm Res* 2003;60:148-51.
  12. Walker SP, Meagher S, White SM. Confined blood chimerism in monochorionic dizygous (MCDZ) twins. *Prenat Diagn* 2007;27:369-72.
  13. Robertson EG and Neer KJ. Placental injection studies in twin gestation. *Am J Obstet Gynecol* 1983;147:170-4.
  14. Phelan MC, Geer JS, Blackburn WR. Vascular anastomoses leading to amelia and cutis aplasia in a dizygotic twin pregnancy. *Clin Genet* 1998;53:126-30.