

Maternal Death due to Acute Fatty Liver of Pregnancy

Jeong-Hwa Kwon¹, Misun Choi²,
Hongil Ha², Sohyung Park²

¹*Department of Pathology, Asan Medical Center, Ulsan University School of Medicine, Seoul, Korea,*
²*Medical Examiner's Office, National Forensic Service, Wonju, Korea*

Received: October 29, 2017
Revised: November 21, 2017
Accepted: November 28, 2017

Correspondence to
Sohyung Park
Medical Examiner's Office, National Forensic Service, 10 Ipchun-ro, Wonju 26460, Korea
Tel: +82-33-902-2505
Fax: +82-33-902-5911
E-mail: zzeva@korea.kr

Acute fatty liver of pregnancy (AFLP) is one of the sudden unexpected causes in pregnancy and maternal deaths. It has been considered as a potential fatal disease in pregnancy, but the postmortem findings of AFLP is not well known. Because an unexpected maternal death may lead to a legal dispute, forensic pathologists should be aware of clinical presentations and postmortem findings of AFLP. Therefore, we presented our case and reviewed with literatures.

Key Words: Acute fatty liver of pregnancy; Maternal death; Forensic pathology; Autopsy

Introduction

A pregnant woman has to adapt to various physiologic changes which follows growing and delivering a baby. In other words, a serious complication can occur in physiologic changes that may give a rise to maternal or fetal mortality if these physiologic changes are maladjusted. Maternal mortality can be an important issue in forensic pathology as well as in public health because, if an unexpected maternal death occurs despite prenatal care having been performed, it may be embroiled in a medicolegal dispute.

Acute fatty liver of pregnancy (AFLP) is a characteristic

liver disease associated with pregnancy that can cause death in both mother and fetus [1]. The diagnosis of AFLP usually should be based on clinical presentation with consistent laboratory results and imaging studies. However, if the mother doesn't show any significant symptoms related to AFLP, or if AFLP is not clinically suspicious and as a result no further evaluation are performed, the diagnosis is not easy to make. In addition, the maternal mortality of AFLP was reported as approximately 18% [1] but lethal cases of AFLP are not well known. In this case report, we illustrated a sudden death case of maternal death of AFLP and we reviewed postmortem findings with literature.

Case Report

1. Case history

The deceased was a 33-year-old primipara woman at 40 weeks of pregnancy, 152.5 cm in height and 89 kg in weight. She had spontaneous abortion with retained placenta on the obstetric history, and she also received a tonsillectomy and a surgery for lumbar disc herniation in the past. She was admitted to a hospital for delivery (40 weeks). At admission, she had a headache and blood pressure was 134/80 mm Hg and the heart rate, 104/min. On the next day (40 week and 1 day), labor induction failed because of cephalopelvic disproportion, so she had undergone cesarean section and gave birth to a healthy baby. Then total hysterectomy was performed because of placenta accreta. During she was in a recovery room after surgery, she complained of chest tightness and became irritable. The vital signs became unstable and oliguria was noted. Then cardiac arrest occurred and she was expired.

2. Postmortem findings

On external examination, a 14.5-cm transverse surgical scar was observed on her lower abdomen. Signs of therapeutic procedure were identified in the chest due to cardiopulmonary resuscitation and injection marks on the neck and upper abdomen.

On internal examination, serosanguinous fluid of approximately 100 mL was observed in the pleural cavity, and serosanguinous fluid of approximately 600 mL in the abdominal cavity. Extensive hemorrhage was observed in the lower retroperitoneum and pelvic cavity. Approximately 100 mL of blood clots were observed around the sutured site in the pelvic cavity after hysterectomy. The uterus was separately submitted, and it weighs 785 g. A sutured surgical site was identified on the anterior lower wall of the uterus. Uterine arteries with major branches were sutured. The placenta was already removed in the uterus, but a piece of the placenta was identified, involving two thirds of the uterine wall of the fundus. The placenta was also separately submitted, and it showed no abnormal findings other than parenchymal hematoma. Internal

organs were pale. The cut surface of the liver was yellow tan and pale (Fig. 1). On histology, macrovesicular and microvesicular fatty changes were identified around central vein, focal necrosis of hepatocytes with infiltration of a few inflammatory cells, and collection of leukocytes in blood vessels (Fig. 2). Thromboembolism was not identified in pulmonary vessels and superficial and deep veins of the lower extremities.

3. Ancillary testing

Analgesics and local anesthetics were detected within the therapeutic concentration range from the blood and gastric contents on the toxicological test.

AFLP was suggested as a possible cause of death because major postmortem finding was macrovesicular and microvesicular steatosis in the liver, and there were

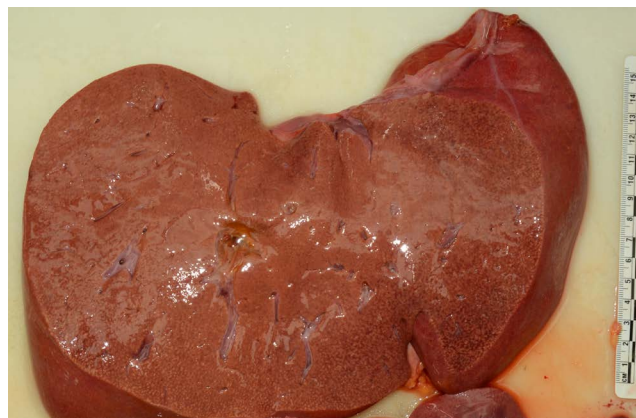

Fig. 1. The cut surface of the liver reveals yellow tan.

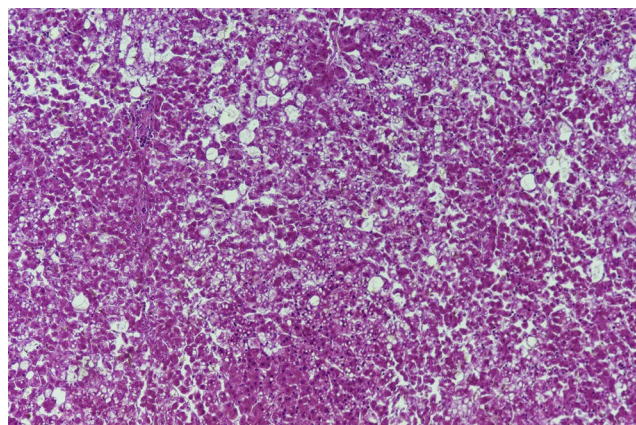


Fig. 2. Macrovesicular and microvesicular fatty changes are identified in liver (H&E, $\times 200$).

no other pathologic findings identified.

Discussion

AFLP is a characteristic liver disease associated with pregnancy [1–3]. “Acute yellow atrophy of the liver,” a rare and fatal complication of pregnancy, was first described by Stander and Cadden in 1934, later it is termed as AFLP [3]. It is a maternal acute liver disease that can lead to death due to microvesicular fatty invasion of hepatocytes causing acute liver dysfunction and coagulopathy and encephalopathy [1–3]. The incidence is about 1:7,000 to 1:15,000 in pregnant women. Most cases occur in the third trimester of pregnancy. Multiple pregnancies and fetal abortions are also common [2]. The maternal mortality rate of 70% and perinatal mortality rate of 85% in the past, was recently reduced to 18% and 23%, respectively [1]. AFLP cases in literatures revealed favorable prognosis [1–3]; however, to our knowledge, there are few literatures which describe lethal cases due to AFLP.

Fatal complications including sudden unexpected death which can occur in peripartum period, was considered. The most common complications are pulmonary artery thromboembolism and amniotic fluid embolism. For other fatal complications of pregnancy, there are peripartum cardiomyopathy, vascular dissections, intracerebral hemorrhage, uterine rupture, various types of thrombotic microangiopathy, and preeclampsia/eclampsia/HELLP syndrome. In our case, her clinical presentation was chest tightness after delivery, so a possibility of cardiomyopathy, thromboembolism, or amniotic fluid embolism was considered. But the postmortem examination with histologic findings revealed no explicit pathologic findings related to those diseases. She also complained of headache and edema of the feet, but these were nonspecific. Vital signs were stable for some time even after she was transferred to a recovery room. Hemorrhagic shock was also unlikely because the clinical presentation and the postmortem findings were not consistent with it.

In addition, other causes to give rise to fatty change in liver should be considered such as drugs, alcohol, virus, ischemic necrosis, vascular, metabolic, autoimmune, Wilson’s disease, Budd-Chiari, posthepatic surgery, sepsis, and so on [4]. The most common cause

of fulminant hepatitis in pregnancy is hepatitis E viral infection [5]. The major postmortem findings were macrovesicular and microvesicular steatosis in liver which are the characteristic findings of AFLP. Despite the fact that various types of hepatitis can be confirmed by laboratory findings, the histologic findings didn’t reveal any pathognomic findings such as lobular activity, interphase hepatitis, and so on.

The deceased visited the hospital regularly for checkup during peripartum period. But during the third trimester, no laboratory tests (including a liver function test) appear to have been done, nor at admission for delivery, according to the medical records. However, the deceased didn’t complain of any symptoms; even a nonspecific symptom including nausea, vomiting, and malaise, as well as severe symptoms suggesting of liver dysfunction or liver failure such as jaundice, often seen in AFLP or hepatitis. Given that the diagnosis of AFLP can be made clinically based on the clinical manifestations, elevated serum aminotransferases and serum bilirubin, it is presumed that the diagnosis of AFLP is not easy to be done clinically in this case.

It has been known that fatty acid oxidation defects (FAOD) may be associated with AFLP in some cases suggesting genetic associations [6–10]. FAOD increases the demand for fatty acids due to changes in physiological metabolism during pregnancy and affects the mother [6–10]. Long-chain 3-hydroxyacyl CoA dehydrogenase (LCHAD) is a well-known risk factor of AFLP [6–10]. The maternal hormone-sensitive lipase (in adipose tissue, adrenal gland, gonads, heart, and skeletal muscle) with insulin resistance, and lipoprotein lipase in the placenta increases the level of triglycerides and finally the level of free fatty acids in maternal blood [7]. Then the accumulation of these fatty acids and their toxic metabolic intermediates lead to activation of reactive oxygen species, inflammatory pathways and cellular necrosis, which have adverse effects to hepatocytes [6–10]. FAOD in a mother or/and a fetus can induce AFLP [6–10]. This pathogenesis would be consistent with the histologic findings identified in our case, and it is presumed that the metabolic abnormality or stress might give rise to sudden death. Her baby was survived at delivery but the information of follow up was not presented. And there was no history of a

metabolic disease in her past history.

Herein we illustrated a case of AFLP. The postmortem examination only could give the definite evidence for the diagnosis of AFLP, because the deceased didn't reveal any typical clinical presentation of liver dysfunction or failure, despite any laboratory test wasn't performed in the third trimester for prenatal care. And there was no other pathologic findings on the postmortem examination which may be encountered in maternal deaths. We hope that this case would be helpful in the practice of forensic pathology.

Conflicts of Interest

No potential conflict of interest relevant to this article was reported.

References

1. Ko H, Yoshida EM. Acute fatty liver of pregnancy. *Can J Gastroenterol* 2006;20:25-30.
2. Rolfes DB, Ishak KG. Acute fatty liver of pregnancy: a clinicopathologic study of 35 cases. *Hepatology* 1985;5:1149-58.
3. Sherlock S. Acute fatty liver of pregnancy and the microvesicular fat diseases. *Gut* 1983;24:265-9.
4. Bernal W, Wendon J. Acute liver failure. *N Engl J Med* 2013;369:2525-34.
5. Hamid SS, Jafri SM, Khan H, et al. Fulminant hepatic failure in pregnant women: acute fatty liver or acute viral hepatitis? *J Hepatol* 1996;25:20-7.
6. Browning MF, Levy HL, Wilkins-Haug LE, et al. Fetal fatty acid oxidation defects and maternal liver disease in pregnancy. *Obstet Gynecol* 2006;107:115-20.
7. Liu J, Ghaziani TT, Wolf JL. Acute fatty liver disease of pregnancy: updates in pathogenesis, diagnosis, and management. *Am J Gastroenterol* 2017;112:838-46.
8. Lindner M, Hoffmann GF, Matern D. Newborn screening for disorders of fatty-acid oxidation: experience and recommendations from an expert meeting. *J Inher Metab Dis* 2010;33:521-6.
9. Han WS, Seo YS, Im SY. Acute fatty liver of pregnancy with fetal microvesicular hepatic steatosis. *Korean J Obstet Gynecol* 2012;55:649-54.
10. Wilcken B, Leung KC, Hammond J, et al. Pregnancy and fetal long-chain 3-hydroxyacyl coenzyme A dehydrogenase deficiency. *Lancet* 1993;341:407-8.