

All-*trans* Retinoic Acid-induced Nephrotic-range Proteinuria in a Patient with Acute Promyelocytic Leukemia

Seong Uk Lim, Se Ryeon Lee, Seong Rye Seo, Jae Sook Ahn, Yeo Kyeoung Kim, Deok Hwan Yang, Je Jung Lee and Hyeoung Joon Kim

Department of Internal Medicine, Chonnam National University Medical School, Gwangju, Korea

All-*trans* retinoic acid (ATRA) is a potent differentiating agent for the treatment of acute promyelocytic leukemia (APL). Although ATRA is generally well-tolerated, some patients develop side effects, the most severe of which is ATRA syndrome. We report on a patient with APL who developed isolated nephrotic-range proteinuria during ATRA therapy for remission-induction. ATRA was discontinued and the proteinuria decreased significantly 5 days after dexamethasone treatment. The occurrence of isolated proteinuria during ATRA treatment is a rare adverse event. (*Korean J Hematol* 2008;43:166-169.)

Key Words: Proteinuria, Acute promyelocytic leukemia, All-*trans* retinoic acid

INTRODUCTION

Differentiation therapy with all-*trans* retinoic acid (ATRA) is currently the first-line treatment for acute promyelocytic leukemia (APL).¹⁾ The administration of ATRA for patients with newly diagnosed APL, either alone or combined with induction chemotherapy, has improved prognosis; specifically, the 2-year event-free survival (EFS) is 79% and the overall survival (OS) is 97%.²⁾ In addition, ATRA alone or in combination with low-dose chemotherapy given together with ATRA as maintenance therapy appears to have beneficial effects.³⁻⁵⁾ ATRA is usually well-tolerated by most patients, but a few major side effects have been observed. The most serious known side effect is the ATRA syndrome. The relatively rare side effects of ATRA treatment in-

clude Sweet's syndrome, scrotal ulcers, myositis, and myocarditis.⁶⁻⁸⁾ We report the case of a patient with APL who developed isolated nephrotic-range proteinuria during ATRA treatment.

CASE REPORT

A 24-year-old man was admitted to our hospital in March 2007 for evaluation of uncontrolled gingival bleeding and fever occurring after a dental procedure. His medical history was significant only for a right inguinal herniorrhaphy 4 years ago. Laboratory examination on admission revealed a leukocytosis ($22.4 \times 10^9/L$), anemia (6.7 g/dL), thrombocytopenia ($30 \times 10^9/L$), a coagulopathy with hypofibrinogenemia (44mg/dL), and elevated fibrin degradation products ($29.4 \mu g/dL$). The initial blood urea nitrogen and creatinine concentrations were 15.4 and 1.0mg/dL,

접수 : 2008년 5월 19일, 수정 : 2008년 8월 26일

승인 : 2008년 8월 30일

교신저자 : 김형준, 전남 화순군 일심리 160

☎ 519-809, 화순전남대학교병원 혈액종양내과

Tel: 061-379-7637, Fax: 061-379-7628

E-mail: drydh1685@hotmail.com

Correspondence to : Hyeoung Joon Kim, M.D., Ph.D.

Department of Hematology/Oncology, Chonnam National University Hwasun Hospital

160, Ilsimri, Hwasun 519-809, Korea

Tel: +82-61-379-7637, Fax: +82-61-379-7628

E-mail: drydh1685@hotmail.com

respectively. There was no proteinuria in the initial urinalysis. Bone marrow (BM) examination revealed a hypercellular marrow; the results confirmed APL with a microgranular variant [AML-M3v (WHO classification)]. Cytogenetic analysis showed a t(15;17)(q22;q24) in all metaphases examined. This translocation was also detected in 94% of the BM cells by dual color fluorescence *in situ* hybridization (FISH) analysis (Fig. 1). A diagnosis of APL was made and treatment was started with oral ATRA at a dose 45mg/m²/day divided into 2 doses, and chemotherapy consisting of intravenous idarubicin (12mg/m²) on days 2, 4, and 6. The patient received empiric antibiotics (cefpiramide, an aminoglycoside, and met-

ronidazole) from the day of admission because of an oral lesion and the fever. Because the fever persisted, the antibiotics were changed to meropenem and teicoplanin on day 4 of hospitalization and the fever subsided.

On day 14 of ATRA therapy, the spot urine showed >300mg/dL of protein. Therefore, we performed a 24-hour urinalysis that revealed a nephrotic-range proteinuria (nephrotic-range: >3.5g/day; patient value: 19.24g/day). Despite the presence of nephrotic-range proteinuria, he had no sign or symptoms of the nephrotic syndrome. At that time, the blood urea nitrogen and creatinine concentrations were 18.0 and 1.0mg/dL, respectively. Viral markers (HIV and hepatitis),

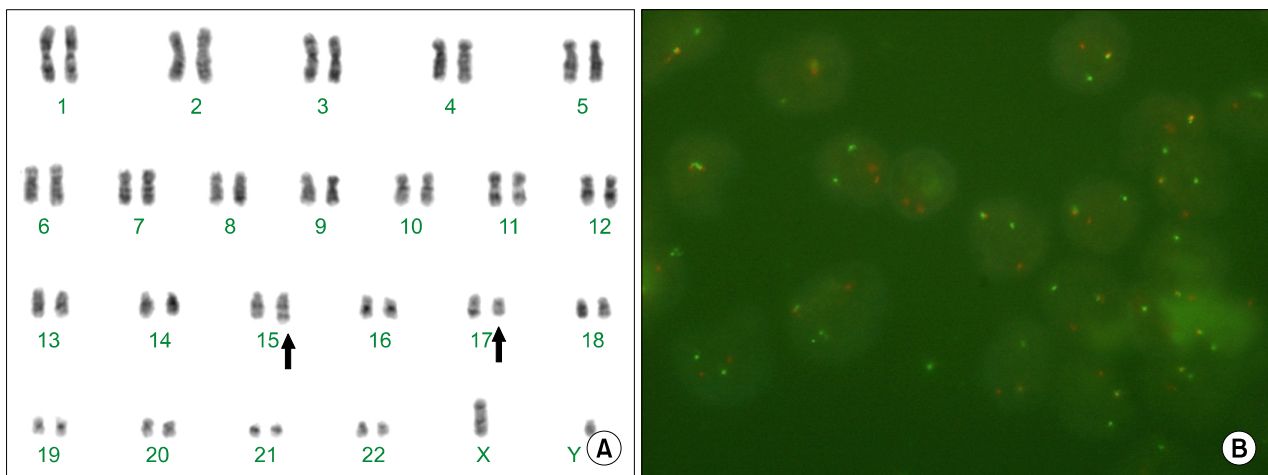


Fig. 1. Cytogenetic and dual color fluorescence in situ hybridization (FISH) analysis. (A) Cytogenetic analysis of the bone marrow showed a t(15;17)(q22;q24) in all metaphases. (B) This translocation between chromosomes 15 and 17 was also detected in 94% of the bone marrow cells by dual color, single fusion method of FISH analysis.

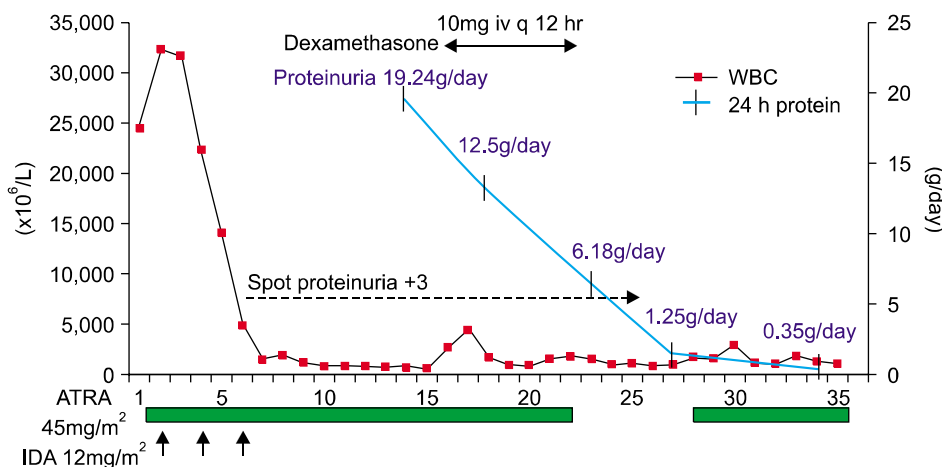


Fig. 2. Time sequence of clinical features. Dexamethasone was started on day 15; the 24-hour proteinuria then decreased to 12.5g/day. However, the spot urine protein remained >300mg/dL and the ATRA was subsequently discontinued on day 22. The concentration of the 24-hour protein decreased gradually. Dexamethasone was discontinued on day 23.

syphilis screening, anti-streptolysin O, immunologic markers (immunoglobulin, anti-nuclear antibody, anti-neutrophil cytoplasmic antibody, anti-double strain DNA, C3, and C4), renal imaging of the kidneys, and an abdominal CT were performed, all of which were negative or normal. Although proteinuria is associated with many medications (e.g., non-steroidal anti-inflammatory drugs and rifampin), these medications were not given to this patient. In spite of thorough testing for proteinuria, other clinical evidences of nephritic syndrome were not identified. In addition, there was no increase in the peripheral blood leukocyte count ($0.8 \times 10^9/L$), and no dyspnea, fever, weight gain, pulmonary infiltration, or pleural and pericardial effusions, which are frequently associated with ATRA syndrome.

Although proteinuria is not a typical presentation of the ATRA syndrome, treatment with dexamethasone (10mg i.v. q 12 hours) was started on day 15; the 24-hour proteinuria decreased to 12.5g/day. However, the spot urine protein remained $>300\text{mg/dL}$ and the ATRA was subsequently discontinued on day 22. The amount of the 24-hour protein decreased gradually and the spot urine protein became negative on day 25, allowing for the re-introduction of ATRA as part of induction therapy on day 27. Dexamethasone was discontinued on day 23 (Fig. 2). Approximately two months later, the BM examination revealed a complete remission. After the third cycle of ATRA combined consolidation chemotherapy, the patient has remained in complete remission with an urinalysis within normal limits.

DISCUSSION

The ATRA syndrome, also known as retinoic acid syndrome, results from the serious side effects of ATRA-based therapy. Frankel et al. reported the first description of this syndrome in 9 of 35 (25%) newly diagnosed APL patients treated with ATRA.⁹⁾ In the absence of strict criteria, the diagnosis of the ATRA syndrome is

based on a constellation of findings. It has been suggested that the diagnosis of the ATRA syndrome should be based on the presence of at least three of the following signs and/or symptoms in the absence of alternative explanations: fever, weight gain, respiratory distress, pulmonary infiltrates, pleural or pericardial effusions, hypotension, and renal failure. The ATRA syndrome occurs in 6~27% of APL patients within 2~47 days after the initiation of treatment with ATRA and the median time of onset is 7 days after initiation of treatment.^{9,10)}

Renal dysfunction occurs frequently in patients with APL during ATRA therapy. Renal failure has been reported in 39% of cases of the ATRA syndrome.¹⁰⁾ Renal involvement in the ATRA syndrome may be caused by several mechanisms: endothelial damage-induced hypotension with capillary leakage syndrome and microcirculation obstruction, tissue infiltration by mature lymphocytes that escape from the BM and capillaries due to overexpression of integrins.¹¹⁾ Cases of isolated acute renal failure have also been described with the ATRA syndrome. The most frequent renal lesion identified is tubular necrosis and renal infiltration by lymphocytes.¹²⁾ There have also been cases reported with granulomatous interstitial nephritis and cortical necrosis.^{13,14)} However, this is the first report of isolated, massive proteinuria in an APL patient during ATRA treatment, although a case with transitory proteinuria was reported by Miró et al.¹⁵⁾ We did not perform a renal biopsy due to the bleeding and infectious risks; a renal biopsy is a valuable tool in patients with nephrotic-range proteinuria for establishing a definitive diagnosis, guiding therapy, and assessing prognosis. This case was limited to exclude various renal diseases causing nephrotic syndrome, such as minimal change disease, focal segmental glomerulonephritis, membranous proliferative glomerulonephritis which could be alleviated by glucocorticoid treatment.

In conclusion, we could not identify any other cause of the proteinuria in the patient described

herein and therefore, concluded that it would be related to the ATRA treatment, albeit no recurrence of proteinuria after restarting ATRA. Although not the typical ATRA syndrome, the 24-hour proteinuria gradually decreased and was easily reversed with no recurrence after treatment with dexamethasone.

요 약

전골수성 백혈병에서 아트라(all-trans retinoic acid)는 백혈병 세포의 분화를 촉진시켜 치료효과를 보여온 우수한 약제이다. 아트라는 전골수성 백혈병에서 획기적인 약제로 수년간 널리 사용되어 왔으나 일부 환자에서는 경미한 부작용에서부터 아트라 증후군에 이르기까지 다양한 증상이 보고되었다. 저자들은 전골수성 백혈병 치료 중에 아트라로 인해 발생한 부작용으로 이제까지 보고된 바가 없는 신증후군 범위의 과량의 고립성 단백뇨증을 보인 사례를 경험하였으며 아트라 중단과 텍사메사손을 이용하여 성공적으로 치료된 증례가 있어 보고하는 바이다.

REFERENCES

- 1) Warrell RP Jr, de Thé H, Wang ZY, Degos L. Acute promyelocytic leukemia. *N Engl J Med* 1993;329:177-89.
- 2) Lengfelder E, Reichert A, Schoch C, et al. Double induction strategy including high dose cytarabine in combination with all-trans retinoic acid: effects in patients with newly diagnosed acute promyelocytic leukemia. German AML Cooperative Group. *Leukemia* 2000;14:1362-70.
- 3) Tallman MS, Andersen JW, Schiffer CA, et al. All-trans-retinoic acid in acute promyelocytic leukemia. *N Engl J Med* 1997;337:1021-8.
- 4) Sanz MA, Martín G, Rayón C, et al. A modified AIDA protocol with anthracycline-based consolidation results in high antileukemic efficacy and reduced toxicity in newly diagnosed PML/RARα-positive acute promyelocytic leukemia. *PETHEMA* group. *Blood* 1999;94:3015-21.
- 5) Fenaux P, Chastang C, Chevret S, et al. A randomized comparison of all transretinoic acid (ATRA) followed by chemotherapy and ATRA plus chemotherapy and the role of maintenance therapy in newly diagnosed acute promyelocytic leukemia. The European APL Group. *Blood* 1999;94:1192-200.
- 6) Astudillo L, Loche F, Reynish W, Rigal-Huguet F, Lamant L, Pris J. Sweet's syndrome associated with retinoic acid syndrome in a patient with promyelocytic leukemia. *Ann Hematol* 2002;81:111-4.
- 7) Charles KS, Kanaa M, Winfield DA, Reilly JT. Scrotal ulceration during all-trans retinoic (ATRA) therapy for acute promyelocytic leukaemia. *Clin Lab Haematol* 2000;22:171-4.
- 8) Martínez-Chamorro C, Martínez E, Gil-Fernández JJ, Alonso A, Escudero A, Fernández-Rañada JM. ATRA-induced myositis in induction therapy of acute promyelocytic leukemia. *Haematologica* 2002;87:ECR08.
- 9) Frankel SR, Eardley A, Lauwers G, Weiss M, Warrell RP Jr. The "retinoic acid syndrome" in acute promyelocytic leukemia. *Ann Intern Med* 1992;117:292-6.
- 10) De Botton S, Dombret H, Sanz M, et al. Incidence, clinical features, and outcome of all trans-retinoic acid syndrome in 413 cases of newly diagnosed acute promyelocytic leukemia. The European APL Group. *Blood* 1998;92:2712-8.
- 11) Larson RS, Tallman MS. Retinoic acid syndrome: manifestations, pathogenesis, and treatment. *Best Pract Res Clin Haematol* 2003;16:453-61.
- 12) Flombaum CD, Isaacs M, Reich L, Berman E, Warrell RP. Acute renal failure associated with the retinoic acid syndrome in acute promyelocytic leukemia. *Am J Kidney Dis* 1996;27:134-7.
- 13) Tomita N, Kanamori H, Fujita H, et al. Granulomatous tubulointerstitial nephritis induced by all-trans retinoic acid. *Anticancer Drugs* 2001;12:677-80.
- 14) Sastre A, Gago E, Baños M, Gómez E. Acute renal failure in the transretinoic syndrome. *Nefrologia* 2007;27:184-90.
- 15) Miró O, Nadal P, Nomdedeu B, Sacanella E. Transitory proteinuria during treatment with tretinoin. *Med Clin (Barc)* 1995;104:439.