

A Case of Chronic Neutrophilic Leukemia with Multiple Myeloma and an Increased Function of Her Neutrophils

Sollip Kim, M.D., Chan-Jeong Park, M.D., Kyoo Hyung Lee, M.D.¹,
Seongsoo Jang, M.D., Hyun Sook Chi, M.D. and Eul-Ju Seo, M.D.

Departments of Laboratory Medicine and ¹Internal Medicine, Asan Medical Center,
University of Ulsan College of Medicine, Seoul, Korea

We describe here a 64-year-old woman who simultaneously presented with chronic neutrophilic leukemia (CNL) and multiple myeloma (MM). The patient presented with mature neutrophilic leukocytosis, hepatosplenomegaly, the absence of Philadelphia chromosome and the *BCR-ABL* fusion gene, along with IgG kappa type monoclonal gammopathy in her serum and urine. The bone marrow aspirates showed hypercellularity with marked granulocytic hyperplasia and an increase in immature plasma cells. The neutrophil function tests showed increased phagocytosis, chemotaxis and respiratory burst activity, but there was normal microbial killing activity. The patient was treated with dexamethasone and pamidronate for MM and with hydroxyurea for CNL, and she was discharged from the hospital in an improved condition. (*Korean J Hematol* 2007;42:151-156.)

Key Words: Chronic neutrophilic leukemia, Multiple myeloma, Neutrophil function test

INTRODUCTION

Chronic neutrophilic leukemia (CNL) is a rare myeloproliferative syndrome of elderly patients. Its diagnostic criteria include peripheral blood leukocytosis due to an increase in the number of mature neutrophils; hypercellularity on bone marrow biopsy; hepatosplenomegaly; no identifiable cause of physiologic neutrophilia; the absence of a Philadelphia chromosome or the *BCR/ABL*

fusion gene; and no evidence of another myeloproliferative disease, a myelodysplastic syndrome or a myelodysplastic/myeloproliferative disorder.¹⁾ CNL is occasionally associated with multiple myeloma (MM). Neutrophil functions in CNL cases have been reported to vary, and they may be important in maintaining the function of the patient's immune system and in understanding the pathophysiology of CNL associated with MM. In this report, we describe a patient presenting with simultaneous IgG kappa type MM and CNL

접수 : 2007년 2월 5일, 수정 : 2007년 4월 24일

승인 : 2007년 5월 2일

교신저자 : 박찬정, 서울시 송파구 풍납2동 388-1

☎ 138-736, 울산대학교 의과대학 서울아산병원
진단검사의학과

Tel: 02-3010-4508, Fax: 02-478-0884

E-mail: cjpark@amc.seoul.kr

Correspondence to : Chan-Jeoung Park, M.D.

Department of Laboratory Medicine, Asan Medical Center, University of Ulsan College of Medicine

388-1, Pungnap 2-dong, Songpa-gu, Seoul 138-736, Korea

Tel: +82-2-3010-4508, Fax: +82-02-478-0884

E-mail: cjpark@amc.seoul.kr

with increased neutrophil functions.

CASE REPORT

A 64-year-old woman was admitted to our hospital with an 8 month history of cough, sputum and aggravated dyspnea on exertion. She was transferred to our hospital for evaluation of marked neutrophilia. She had been on medication for hypertension for 5 years, and had taken thyroxine for hypothyroidism. Vital signs were blood pressure 162/82mmHg, temperature 35.9°C, pulse rate 81/min and respiration rate 24/min. She appeared chronically ill. Physical examination revealed hepatosplenomegaly, the liver extending 2FB and the spleen 5FB below the costal margins. Pitting

edema was present on both legs.

One month earlier, hemoglobin was 8.9g/dL, platelet count was 105,000/ μ L and leukocyte count was 59,770/ μ L. On admission, hemoglobin 9.1g/dL, platelet count was 73,000/ μ L and leukocyte count was 93,000/ μ L, with the latter consisting of 93% segmented neutrophils, 2% lymphocytes, 4% monocytes, and 1% eosinophils. The neutrophils were of mature appearance with toxic changes and the rouleaux formation was observed. A bone marrow (BM) aspirate from the iliac crest was hypercellular, with marked granulocytic hyperplasia and predominant mature neutrophilic expansion, along with 12.2% plasmablasts and 30.6% plasma cells. The ratio of myeloid to erythroid cells was 25.9 : 1. A BM biopsy revealed

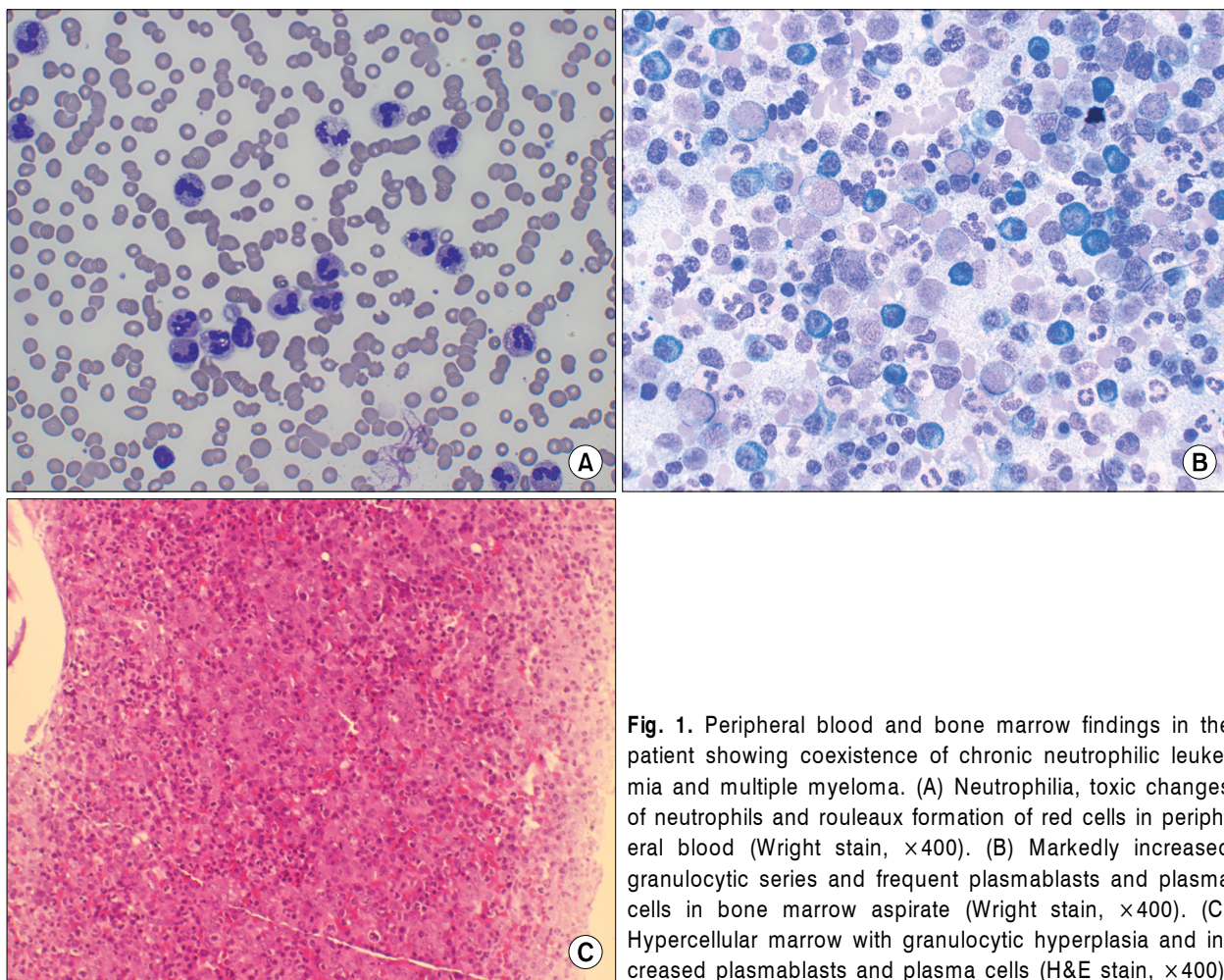


Fig. 1. Peripheral blood and bone marrow findings in the patient showing coexistence of chronic neutrophilic leukemia and multiple myeloma. (A) Neutrophilia, toxic changes of neutrophils and rouleaux formation of red cells in peripheral blood (Wright stain, $\times 400$). (B) Markedly increased granulocytic series and frequent plasmablasts and plasma cells in bone marrow aspirate (Wright stain, $\times 400$). (C) Hypercellular marrow with granulocytic hyperplasia and increased plasmablasts and plasma cells (H&E stain, $\times 400$).

packed marrow with marked mature granulocytic hyperplasia. Plasmablasts and plasma cells were present in the intertrabecular space (Fig. 1).

Serum protein concentration was 9.6g/dL and albumin concentration was 2.3g/dL. Serum M-protein was 4.0g/dL. Serum and urine immunofixation electrophoresis showed IgG kappa monoclonality (Fig. 2). A skeletal x-ray showed no lytic lesions. Cytogenetic analysis of the BM aspirate showed normal karyotype with no evidence of Philadelphia chromosome by the G banding technique. Molecular genetic analysis by reverse transcriptase-polymerase chain reaction failed to reveal fusion of the chimeric bcr-abl messenger RNA. From these results, the patient was diagnosed as having CNL associated with MM.

Neutrophil function tests^{2,3)} showed increased chemotaxis, as measured by the modified Boyden chamber method; and phagocytosis, as deter-

mined by flow cytometry after incubation of neutrophils with FITC-conjugated *Candida albicans*. In addition, respiratory burst activity was increased, as shown by flow cytometry using the DCF-DA method; and respiratory burst activity in the absence of stimulation (spontaneous respiratory burst activity) was markedly increased, whereas microbial killing activity was normal, as shown by flow cytometry of propidium iodide stained neutrophils that had been incubated with *Candida albicans* (Table 1).

The patient was treated with dexamethasone and pamidronate for MM and with hydroxyurea for CNL. She was discharged from the hospital with clinical improvement and has been followed up until now.

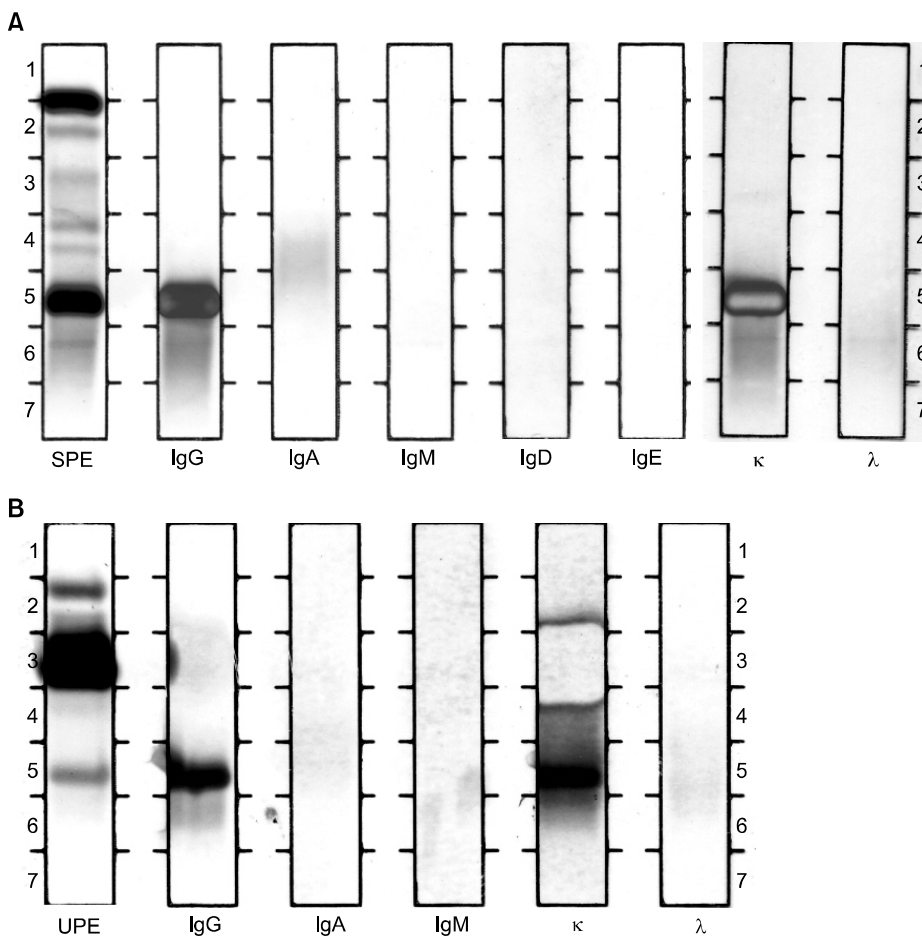


Fig. 2. Immunofixation electrophoresis shows IgG kappa type monoclonal gammopathy in serum (A) and IgG kappa and free kappa type Bence-Jones proteinuria in urine (B). SPE, serum protein electrophoresis; UPE, concentrated urine electrophoresis.

Table 1. Neutrophil function in the patient with coexisting chronic neutrophilic leukemia and multiple myeloma

Chemotaxis		Neutrophil No./Boyden chamber well (8mm ²)		
Stimulants	Patient	Normal control	Ratio (Patient/Normal control)	
Phosphate buffered saline (random motility)	46,080	16,896	2.73	
FMLP* 10 ⁻⁸ M/L	83,968	52,224	1.61	
Heat-inactivated normal plasma	73,728	35,840	2.06	
Zymosan activated normal plasma	100,352	72,704	1.38	
Phagocytosis	<i>Candida albicans</i>	Patient	Normal control	Ratio (Patient/Normal control)
Median channel of fluorescence	178	1,863	440	4.23
Respiratory burst activity		Mean channel of fluorescence (H ₂ O ₂ production)		
Stimulants	Patient	Normal control	Ratio (Patient/Normal control)	
Rest (no stimulant)	1,106	166	6.66	
PMA [†] 200ng/mL	7,032	3,020	2.33	
Microbial killing		Patient	Normal control	
% of <i>C. albicans</i> killing by neutrophils		40.8%	43.1%	

*Formyl-methionyl-leucyl-phenylalanine, [†]Phorbol myristate acetate. Compared with the normal control neutrophils, the patient neutrophils show increased chemotaxis, phagocytosis and respiratory burst activity, especially increased in no stimulation state, but normal microbial killing activity.

DISCUSSION

The clinical and laboratory findings of this patient satisfied the criteria required for the diagnosis of CNL. The diagnosis of MM was based on IgG kappa monoclonal hypergammaglobulinemia and increased plasmablasts and plasma cells in BM aspirates.

Although light and electron microscopy studies of neutrophils from a CNL patient do not reveal any differences from normal mature neutrophils, functional characterization shows marked differences. For example, neutrophils from a CNL patient are less viable.⁴⁾ In this case, phagocytosis, chemotaxis and respiratory burst activity (superoxide production) were increased, especially in the absence of stimulation (spontaneous respiratory burst activity), whereas microbial killing activity

was similar to that of normal control neutrophils. Normal or elevated phagocytosis and respiratory burst activity⁵⁻⁸⁾ and decreased bactericidal activity of neutrophils^{4,6,7)} have been reported in patients with CNL. Differences in neutrophil function may be due to differences in the pathophysiology of each patient or to technical differences in the assessment of neutrophil function.⁵⁾

To our knowledge, 22 patients, including ours, have been reported to have CNL associated with monoclonal gammopathy.⁹⁻¹²⁾ The clonality types were IgG-lambda in 9 patients, IgA-lambda in 5 patients, IgG-kappa in 3 patients, IgA-kappa in 2 patients, kappa light chain in 2 patients and lambda light chain in 1 patient. 1 patient showed biclonal gammopathy.⁹⁻¹²⁾ As previously reported by Ito et al.¹¹⁾, disproportionate association with lambda light chain rather than kappa chain was documented ($\kappa : \lambda = 7 : 15$).⁹⁻¹²⁾ In 16 cases, in-

cluding the present case, CNL and monoclonal gammopathy presented simultaneously. However, in 5 cases, CNL was seen to occur before the appearance of monoclonal gammopathy. There were 2 cases in which CNL was preceded by monoclonal gammopathy.⁹⁻¹²⁾ Although CNL is generally regarded as a myeloproliferative disorder and has shown evidence of clonality,¹³⁾ myeloma-associated CNL can be caused by reactive myeloid proliferation.¹⁴⁾ In this situation, the myeloid expansion might represent a leukemoid response induced by the plasma cell population.¹⁴⁾ Plausible mechanisms could include enhanced release of stimulatory factors, for example, G-CSF or interleukin-3, and decreased production of putative inhibitory mediators which normally function to suppress granulocyte production.¹⁴⁾ Recently, Kohmura et al.¹⁵⁾ demonstrated that CD138 positive plasma cells purified from bone marrow of MM associated with neutrophilia expressed G-CSF mRNA. By immunohistochemical stain, Kusaba et al.¹⁶⁾ demonstrated that G-CSF-producing myeloma with clinical manifestations mimicking chronic neutrophilic leukemia. In their case, atypical plasma cells were positive for anti G-CSF antibody.¹⁶⁾ Therefore, it is possible that the production of G-CSF by plasma cells is involved in the development of chronic neutrophilic leukemia. If clonal neoplastic neutrophils proliferate, they may show decreased neutrophil functions. In contrast, the granulocytic expansion in CNL associated with MM may represent a polyclonal reactive response to the plasma cell clone rather than a co-existent myeloproliferative disorder.¹⁴⁾ Elevated levels of IL-6 in patients with MM may stimulate granulopoiesis, resulting in expanding granulocytosis as in CNL¹⁷⁾, which could explain our case, where marked neutrophilia, along with toxic changes and increased neutrophil functions, especially the markedly increased spontaneous respiratory burst activity of neutrophils.

We report a case of MM associated with a CNL and increased neutrophil function with review of

the literatures. We agree that the so-called "CNL" is a syndrome of heterogeneous disorders, some of which are apparently clonal myeloid proliferation and others which may be leukemoid reactions.¹¹⁾ Especially in cases associated with monoclonal gammopathy, the evidence of clonality of neutrophils by molecular method and an evidence of no role of growth factors might be demonstrated to rule out a polyclonal reactive response to the plasma cell clone.

요 약

저자들은 면역글로불린 G 카파형(IgG kappa) 다발성골수종과 동반된 만성호중구성백혈병 1예를 경험하였기에 보고하는 바이다. 64세 여자 환자가 말초 혈액에서의 성숙백혈구 증가, 간비종대, 필라델피아 염색체와 *bcr-abl* 융합유전자 부재, 혈청과 소변에서 IgG kappa형의 단클론 감마글로불린혈증을 나타내었다. 골수도말검사상 종양성 형질모세포, 형질세포와 함께 성숙한 형태의 골수계 세포가 증가되었고 골수조직 소견상 100%의 세포충실도를 보였다. 호중구 기능검사상 탐식능, 주화성 및 산화물형성능이 현저히 증가되었다. 다발성골수종에 대하여 dexamethasone과 pamidronate로, 만성호중구성백혈병에 대하여 hydroxyurea로 치료한 후 호전되어 퇴원하였다.

REFERENCES

- 1) Imbert M, Bain B, Pierre R, Vardiman JW, Brunning RD, Flandrin G. Chronic neutrophilic leukaemia. In: Jaffe E, Harris N, Stein H, Vardiman J, eds. World health organization classification of tumour: Pathology and genetics of tumours of haematopoietic and lymphoid tissue. Lyon, France: IARC Press, 2001:27-8.
- 2) Campbell DE, Douglas SD. Phagocytic cell functions. I. Oxidation and chemotaxis. In: Rose NR, de Macario EC, Folds JD, Lane HC, Nakamura RM, eds. Manual of clinical laboratory immunology. 5th ed. Washington, D.C.: ASM Press, 1997:320-8.
- 3) O'Gorman MR. Phagocytic cell functions. Ii. Adhesion and phagocytosis. In: Rose NR, de Macario EC, Folds JD, Lane HC, Nakamura RM, eds. Manual of clinical laboratory immunology. 5th ed. Washington, D.C.:

- ASM Press, 1997:329-33.
- 4) Krishnan Y, Sreedharan P, Ramanan S, Sagar T. Chronic neutrophilic leukemia: a case report and review of literature. *Indian J Med Paediatr Oncol* 2004;25:46-8.
- 5) Ohtsuki T, Katsura Y, Mizukami H, et al. Elevated neutrophil function in chronic neutrophilic leukemia. *Am J Hematol* 1992;41:50-6.
- 6) Mehrotra PK, Winfield DA, Fergusson LH. Cellular abnormalities and reduced colony-forming cells in chronic neutrophilic leukaemia. *Acta Haematol* 1985;73:47-50.
- 7) Dotten DA, Pruzanski W, Wong D. Functional characterization of the cells in chronic neutrophilic leukemia. *Am J Hematol* 1982;12:157-65.
- 8) Oogushi K, Shimamoto Y, Hamasaki Y, et al. The discrepancy between chemotaxis and leukotriene B4 production in a patient with chronic neutrophilic leukemia. *Jpn J Med* 1989;28:717-21.
- 9) Kim KH, Kim OY, Jo CH, et al. A case of chronic neutrophilic leukemia with multiple myeloma. *Korean J Hematol* 1998;33:454-9.
- 10) You ST, Lee TH, Shun DJ, Lee KS, Cho HC. A case of multiple myeloma detected from long term follow up of chronic neutrophilic leukemia. *Korean J Hematol* 1990;25:597-603.
- 11) Ito T, Kojima H, Otani K, et al. Chronic neutrophilic leukemia associated with monoclonal gammopathy of undetermined significance. *Acta Haematol* 1996;95:140-3.
- 12) Dinçol G, Nalçacı M, Doğan O, et al. Coexistence of chronic neutrophilic leukemia with multiple myeloma. *Leuk Lymphoma* 2002;43:649-51.
- 13) Böhm J, Kock S, Schaefer HE, Fisch P. Evidence of clonality in chronic neutrophilic leukaemia. *J Clin Pathol* 2003;56:292-5.
- 14) Standen GR, Jasani B, Wagstaff M, Wardrop CA. Chronic neutrophilic leukemia and multiple myeloma. An association with lambda light chain expression. *Cancer* 1990;66:162-6.
- 15) Kohmura K, Miyakawa Y, Kameyama K, Kizaki M, Ikeda Y. Granulocyte colony stimulating factor-producing multiple myeloma associated with neutrophilia. *Leuk Lymphoma* 2004;45:1475-9.
- 16) Kusaba N, Yoshida H, Ohkubo F, et al. Granulocyte-colony stimulating factor-producing myeloma with clinical manifestations mimicking chronic neutrophilic leukemia. *Rinsho Ketsueki* 2004;45:228-32.
- 17) Cehreli C, Undar B, Akkoc N, Onvural B, Altungoz O. Coexistence of chronic neutrophilic leukemia with light chain myeloma. *Acta Haematol* 1994;91:32-4.