

## 적극적인 다방법병합요법을 이용한 뇌전이성 용모상피암의 치료

연세대학교 의과대학 산부인과학교실, 신경외과학교실<sup>1</sup>  
권자영 · 김재욱 · 김동규 · 김영태 · 허승곤<sup>1</sup>

### A Case of Cerebral Metastatic Choriocarcinoma Successfully Treated with a Vigorous Multimodality Approach

Ja-Young Kwon, Jae-Wook Kim, Dong-Kyu Kim, Young-Tae Kim, <sup>1</sup>Seung-Kon Huh

Department of Obstetrics and Gynecology and <sup>1</sup>Neurosurgery,  
Yonsei University College of Medicine, Seoul, Korea

**Abstract :** Choriocarcinoma is a gynecologic malignancy of a child-bearing age which is widely known for its highly chemo-sensitive nature. Early detection and proper management according to the risk scoring system have resulted in an excellent outcome that now exceeds 90%. Because of the outstanding efficacy of chemotherapy alone in treating choriocarcinoma, adjuvant radiotherapy and surgery have been discouraged unless in cases of intractable hemorrhage or drug-resistant tumor. However, as high as 25% of high-risk patients show incomplete response or relapse following remission, and those with disseminated disease with lung or brain metastases have disappointing outcome when treated by chemotherapy alone. In light of this, multimodality therapy that includes early aggressive surgical extirpation, irradiation, and combination chemotherapy to improve therapeutic success should be highly considered and emphasized in high-risk patients. We report a 27-year-old woman who initially complained of headache and subsequently underwent craniotomy due to intracerebral hemorrhage. She was diagnosed of cerebral metastasis of choriocarcinoma. She was aggressively treated by multimodality therapy including combination chemotherapy, cranial irradiation, and craniotomy, and successfully gained complete remission.

**Key Words:** Choriocarcinoma, cerebral metastases, multimodality therapy.

### Introduction

Cerebral metastasis rarely occurs in most gynecologic malignancy, however, choriocarcinoma that arises in the fetal chorion of the placenta frequently involves the central nervous system(CNS). The reported incidence of patients with disseminated gestational trophoblastic neoplasia presenting with CNS metastases varies

ranging from 3% to 30%.<sup>1,2,3,4</sup> Although choriocarcinoma is highly curable with modern chemotherapy, presence of CNS metastases places patients at very high risk of treatment failure.<sup>5,6</sup> Poor response has been attributed to delayed diagnosis since the initial symptoms in intracerebral choriocarcinoma are nongynecological ones, decreased responsiveness due to the location of tumor, and abrupt event of fatal intracranial

책임저자 : 김재욱

hemorrhage.<sup>5,7</sup>

In effort to improve the outcomes in treating patients with CNS metastases, following two key factors should be acquired. Firstly, a promptly initiated treatment based on early diagnosis is precious.<sup>6,9,10</sup> Since many women with metastatic choriocarcinoma have no tumor in the uterus, their only presenting symptoms are seizure, headache, or mental change.<sup>13</sup> Therefore, serum beta human chorionic gonadotropin (bHCG) titer should be checked in any patient of reproductive age presenting with neurologic symptoms accompanying metastatic lesion in the brain.<sup>4,7,13</sup>

The second key factor is a correctly selected treatment strategies that are aggressive enough to obtain successful outcome.<sup>2,6,9,13</sup> Since the discovery of the efficacy of chemotherapy in treating metastatic gestational trophoblastic disease by Hertz and colleagues in the late 1950s, the cure rate has steadily increased to 80-90%.<sup>6,14</sup> But in case of cerebral metastases, this favorable prognosis is not shared. Thus, incessant endeavor to increase the survival of patients with CNS metastases has led to development of new treatment modalities, a multimodality therapy with combination chemotherapy including etoposide, methotrexate, actinomycin D, cyclophosphamide and vincristine (EMA-CO), accompanied by cranial irradiation and surgery.<sup>4,6,15</sup> It has been reported that in overall, 50-80% of patients with CNS metastases can be cured by using multimodality therapy.<sup>6</sup> However, craniotomy has only been considered in patients with hemorrhage or in need of acute decompression,<sup>9,16</sup> thus only a small number of patients with CNS metastases eradicated by surgery-included treatment modalities have previously been reported. In light of this, with a brief review of literatures, we report a 27-year-old woman presented with cerebral metastatic choriocarcinoma who had been immediately started on an aggressive surgical

management with combined chemotherapy and concurrent irradiation that resulted in a satisfactory outcome. We hope it to be of additional information and experience in the establishment of management guide in choriocarcinoma with brain metastases.

## Case Report

A 27-year-old married woman with parity history of 1-1-0-1 was transferred to the emergency room from the local clinic complaining of intractable headache for 12 days. Her first delivery 11 months ago had been a normal spontaneous vaginal delivery and second delivery 2 weeks prior to the admission, which resulted in intrauterine fetal death at 26 weeks' gestation. The placenta had not been examined. Subsequent to the last delivery, she did well without an irregular vaginal bleeding until the patient complained of a sudden headache 2 days later, which grew worse despite conservative management. She was admitted to the local clinic where a computed tomography(CT) of the brain was performed(Fig. 1). It revealed about 5x4x3 cm-



Fig 1. Computed tomography of the brain demonstrating acute hemorrhage located in the left parietal lobe(left) and subdural space(right).

sized lesion in the posterior portion of the left parietal lobe with subdural hemorrhage involving the fronto-parietal part of the left hemisphere. At the time of referral, no neurologic deficit was noted. Pregnancy test and serum bHCG level had not been checked initially. Left internal carotid angiogram (Fig. 2) demonstrated multiple small vascular

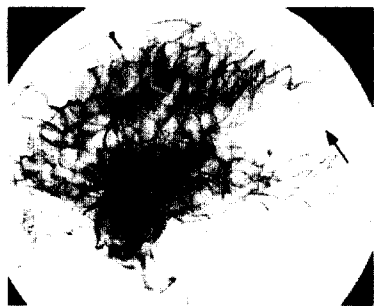



Fig. 2. Left internal carotid angiogram demonstrating small vascular malformation (arrow) mimicking nidus of arterio-venous malformation in the left parietal region supplied by angular branch of left middle cerebral artery draining to superior sagittal sinus.

malformations in the left parietal lobe that were supplied by angular branch of left middle cerebral artery. Considering the patient's young age, the CT brain scan demonstrating intracerebral hemorrhage in an unusual site (subcortical), and the angiographic finding which suggested nidus of arterio-venous malformation (AVM), the patient was referred to the neurosurgery department for surgery under the presumptive diagnosis of AVM. Craniotomy with total removal of left parietal mass was done on. After histopathologic examination of the mass, the



Fig. 3. Microscopic examination of the left parietal section shows large syncytial anaplastic pleomorphic cells surrounding cords of cytotrophoblast (H&E,  $\times 200$ : A). The tumor cells reveals positive reaction for HCG immunohistochemical staining ( $\times 400$ : B).



diagnosis was metastatic choriocarcinoma (Fig. 3). Then she was referred to the department of obstetrics and gynecology for further work-up.

Postoperatively, serum bHCG titer reached 195288 IU/L. A thorough search for additional

tumors was done. CT of the thorax depicted multiple variable sized metastatic nodules scattered in the lungs. Gynecologic ultrasound demonstrated about 1.9x1.6 cm sized heterogenous echogenic mass with high blood flow in the uterine fundus. Consistent with the sonographic finding, abdominal pelvic magnetic resonance imaging (MRI) showed an increased signal intensity in the uterine fundus (Fig.



Fig. 4. Sagittal T2 weighted image of pelvic MRI revealing infiltrating mass lesion with high signal intensity in the uterine fundus.

4). According to the FIGO anatomical staging system and WHO scoring system, she was diagnosed with choriocarcinoma stage IVb with total risk score of 11 placing her into high-risk category (Table 1).

	Score			
	0	1	2	3
Age (years)	$\leq 39$	$\leq 39$		
Antecedent pregnancy	Hydatidiform mole	Abortion	Term	Term
Interval between end of antecedent pregnancy and start of chemotherapy (months)	$< 4$	4-6	7-12	$> 12$
Human chorionic gonadotropin (IU/liter)	$< 10^3$	$10^3-10^4$	$10^4-10^5$	$> 10^5$
ABO groups		O or A	B or AB	
Largest tumor, including uterine (cm)	$< 3$	3-5	$> 5$	
Size of metastases		Spleen, Kidney	Gastrointestinal tract, liver	Brain
Number of metastases		1-3	4-8	$> 8$
Prior chemotherapy			1 drug	$\geq 2$ drug

□ Our patient's score is indicated in a box

Table 1. The patient's risk score according to WHO Scoring System.

Following her full recovery from the surgery, weekly alternating chemotherapy courses with EMA-CO regimen were started. Concurrently, she received cranial irradiation (2500 cGy in 250 cGy fractions to the whole brain and 1000 cGy in 200 cGy fractions to the tumor bed). After two courses of alternate weeks of chemotherapy, serum HCG level decreased exponentially to 80 IU/L.

She was readmitted for her 3<sup>rd</sup> course of chemotherapy when fever developed accompanied by severe headache and vomiting. White blood cell count was 7830/ul and culture studies were normal. Brain MRI demonstrated about 3.6-cm lesion with surrounding edema in previously operated site. During the next 7 days under antibiotics coverage and conservative management to relieve of cerebral swelling, fever gradually subsided but leukocytosis developed. Under the impression of brain abscess, she underwent single burr hole drainage and catheter insertion to the lesion as a first step for decompression. About 10cc of bloody fluid having gelatinous consistency was drained. Fluid culture was negative for bacteria and the pathologist confirmed negative for malignancy. Left parietal craniotomy and total removal of tumor were performed. Pathologic examination revealed the presence of coagulative necrosis, consistent with radiation necrosis. No malignant cells were seen.

Postoperatively, she showed no signs of intellectual or neurologic deterioration. She was restarted on chemotherapy. Normal serum  $\beta$ HCG level of below 2 IU/L was obtained following the 2nd course chemotherapy. The fall of serum  $\beta$ HCG levels throughout the course of therapy is demonstrated in Fig. 5. Latest chest radiogram and

follow-up CT brain scan showed complete disappearance of the metastatic lesions.

Following normalization of serum  $\beta$ HCG titer, total of 4 courses of chemotherapy were administered without any devastating complication and currently, she is being followed up on out-patient clinic.

## Discussion

Choriocarcinoma is a rare but curable disease. It is widely known for unique characteristics of its incidence in young reproductive women, its tendency for early dissemination, its prediction of a reliable tumor marker  $\beta$ HCG, and its extreme response to chemotherapy.<sup>2,13</sup> It is being recognized more frequently and considered importantly because of its high curability with correctly chosen management.<sup>17</sup>

Beginning with Hertz and his colleges reporting of a complete response to chemotherapy in patients with metastatic gestational trophoblastic disease in 1956<sup>18</sup>, many have continued to establish more effective chemotherapeutic regimens to achieve complete remission. Owing to the improvements, the cure rate has steadily increased from 50% to over 90%.<sup>6,13</sup> Surely, the development of newer chemotherapeutic program has played an important role in increasing the cure rate, however, recognition of certain prognostic factors that categorizes patients into 'high-risk' groups has also made large contribution. A 100% cure is expected in patients with nonmetastatic and low-risk metastatic disease, whereas about 20% of high-risk metastatic disease experience treatment failure and die.<sup>6</sup> Thus importance of recognizing the risk factors that predict the likelihood of a disease to respond to chemotherapy is stressed and treating the patients individually and vigorously in accord to the risk

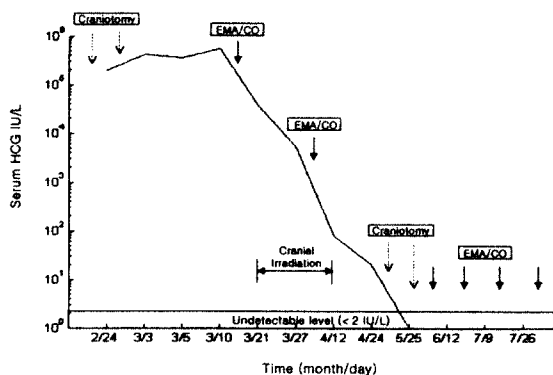


Fig. 5. Serum HCG titers throughout therapy.

score must be emphasized.

The WHO scoring system based on prognostic factors includes 9 parameters in which a numeric value is assigned to patients that adds up to a total score which gives information on the likelihood of the patient achieving complete response to chemotherapy. Gordon et al with 61 patients with high-risk disease, they showed that treatment outcome was significantly poorer for patients present with longer intervals of disease, cerebral or hepatic metastases, and full-term pregnancy.<sup>10</sup> Bagshawe presented initial  $\beta$ HCG level reflecting the tumor burden and the interval between the end of antecedent pregnancy and the start of chemotherapy as two factors affecting the treatment failure.<sup>17</sup> Our patient was placed at high-risk group with initially high  $\beta$ HCG titer, a brain metastases, antecedent pregnancy of preterm delivery but a short duration of disease less than 4 months.

During early 1980s, EMA-CO regimens has been formulated by Newlands et al<sup>4</sup> and since then numerous reports showing complete response rates and long-term survival rates of over 80% in high-risk patients have been made.<sup>4,6,20,21</sup> The EMA-CO protocol is the current initial treatment of choice for high-risk patients.

Metastases to CNS is a factor that increases risk of treatment failure. The poor outcome may be due to failure of chemotherapeutic agents to enter brain and cerebrospinal fluid to reach adequate therapeutic level.<sup>1</sup> Besides methotrexate that readily penetrates blood-brain barrier, no clear information is available concerning other agents. To overcome the barrier, intrathecal methotrexate infusion and cranial irradiation have been considered. Brace as a start, many reports have appeared to confirm the therapeutic role of irradiation. Yordan et al reported that 6 of 25 patients survived in the chemotherapy-alone group whereas 9 of 18 survived treated by chemotherapy and radiotherapy. Interestingly, they

observed among autopsies, 16 of 19 patients who had chemotherapy alone but revealed persistent disease in the CNS died of trophoblastic disease.<sup>1</sup> Evans et al reported the survival rate in patients who had received adjuvant radiation to be 75%.<sup>24</sup> Also Weed and Hammond reported their favorable experiences with radiation.<sup>9</sup> To the contrary, Hongzhao et al reported similar survival rate in patients with CNS lesion receiving chemotherapy without radiation.<sup>1</sup> Bagshawe et al did not consider radiotherapy advantageous in their review of 69 patients with CNS metastases.<sup>3,17</sup> Let aside the controversies, whole brain irradiation is usually given concurrently with combination chemotherapy when CNS involvement is present.<sup>6</sup>

The exact action mechanism of radiation has not been clear but it have been speculated that radiation may prevent hemorrhage by attenuating vasculo-invasiveness and exert tumoricidal effect by itself or together with chemotherapy.<sup>1,5</sup> What should be remembered when treating patients with chemotherapy in adjunction to radiation, is that radiation necrosis may be intensified causing neurologic deficit or signs of increased intracranial pressure.<sup>25</sup> As in our case, early detection and surgical extirpation may be life-saving.

As mentioned earlier, early diagnosis and aggressive therapy cannot be overemphasized in obtaining successful outcome. Surgery as a part of multimodality therapy should never be neglected in treating cerebral metastases. Reasons necessitating an early craniotomy to remove CNS lesion can be laid out. Evident development of imaging by CT or MRI has lead to enable a precise localization of the cerebral lesion.<sup>2,16</sup> Early removal of the tumor burden that is likely to become drug-resistant may contribute to better result and also reduce total duration of treatment. And most important of all, early craniotomy may prevent early sudden death attributed to fatal intracranial hemorrhage before

chemotherapy can be effective.<sup>4,9,26</sup> In a study by Athanassiou et al at Charing Cross Hospital, out of 33 patients presenting with CNS disease prior to treatment 8(24%) died of intracerebral bleeding within 15 days of presentation.<sup>3</sup> Rustin et al experienced 3 early deaths (17%) out of 25 patients with CNS metastases and they pointed out the rationale for early surgery to prevent hemorrhage and early deaths.<sup>4</sup>

Our patient presented with high-risk gestational trophoblastic disease with metastatic lesions in lung and brain and she was aggressively managed. The treatment included combined chemotherapy according to EMA-CO protocol, cranial irradiation, and craniotomies, twice for complete tumor removal. And subsequent to vigorous surgery, our patient is doing well without any neurologic complication. Again, we would like to propose the need for early surgical extirpation and aggressive multimodality therapy in treating patients with CNS metastases.

## References

1. Yordan EL Jr, Schlaerth J, Gaddis O, Morrow P. Radiation therapy in the management of gestational choriocarcinoma metastatic to the central nervous system. *Obstet Gynecol* 1987;69:627-30.
2. Weed JC Jr, Woodward KT, Hammond CB. Choriocarcinoma metastatic to the brain:therapy and prognosis. *Seminars in Oncology* 1982;9:208-12.
3. Athanassiou A, Begent RJ, Newlands ES, Parker D, Rustin GJS, Bagshawe KD. Central nervous system metastases of choriocarcinoma:23 years experience at Charing Cross Hospital. *Cancer* 1983;52:1728-35.
4. Rustin GJS, Newlands ES, Begent RHJ, Dent J, Bagshawe KD. Weekly alternating etoposide, methotrexate, and actinomycin/vincristine and cyclophosphamide chemotherapy for the treatment of CNS metastases of choriocarcinoma. *J Clin Oncol* 1989;7:900-3.
5. Jones WB, Wagner-Reiss KM, Lewis JL. Intracerebral choriocarcinoma. *Gynecol Oncol* 1990;38:234-43.
6. Lurain JR. Management of high-risk gestational trophoblastic disease. *J Reprod Med* 1998;43:44-52.
7. Flam F, Holtz A. Case report:choriocarcinoma presenting with brain metastases. *Neurol Res* 1994;16:403-4.
8. Weed JC Jr, Hammond CB. Cerebral metastatic choriocarcinoma: intensive therapy and prognosis. *Obstet Gynecol* 1980;55:89-94.
9. Gordon AN, Gershenson DM, Copeland LJ, Saul PB, Davanagh JJ, Edwards CL. High-risk metastatic gestational trophoblastic disease. *Obstet Gynecol* 1985;65:550-6.
10. Lewis JL Jr. Diagnosis and management of gestational trophoblastic disease. *Cancer* 1993;71:1639-47.
11. DuBeshter B, Berkowitz RS, Goldstein DP, Cramer DW, Bernstein MR. Metastatic gestational trophoblastic disease:experience at the New England Trophoblastic Disease Center, 1965 to 1985. *Obstet Gynecol* 1987;69:390-5.
12. Pihl K, Malmstrom H, Simonsen E. Choriocarcinoma presenting with cerebral metastases after full-term pregnancy. *Acta Obstet Gynecol Scand* 1990;69:433-5.
13. Smith DB, O Reilly SM, Newlands ES. Current approaches to diagnosis and treatment of gestational trophoblastic disease. *Curr Opin Obstet Gynecol* 1993;5:84-91.
14. Bagshawe KD. Treatment of high-risk choriocarcinoma. *J Reprod Med* 1984;29:813-20.
15. Li MC, Hertz R, Spencer DB. Effects of methotrexate therapy upon choriocarcinoma and chorioadenoma. *Proc Soc Exp Biol Med* 1956;93:361-6.
16. Newlands ES, Bagshawe KD, Begent RHJ, Rustin GJS, Holden L. Results with EMA/CO(etoposide, methotrexate, actinomycin D, cyclophosphamide, vincristine) regimen in high risk gestational trophoblastic tumors, 1979-1989. *Br J Obstet Gynaecol* 1991;98:550-7.
17. Bower M, Newlands ES, Holden L. EMA/CO for high-risk gestational trophoblastic tumors:results from a cohort of 272 patients. *J Clin Oncol* 1997;15:2636-2643.
18. Evans AC Jr, Soper JT, Clarke-Pearson DL. Gestational trophoblastic disease metastatic to the central nervous system. *Gynecol Oncol* 1995;59:226-30.
19. Pratt RA, Chiro GD, Weed JC. Cerebral necrosis following irradiation and chemotherapy for metastatic choriocarcinoma. *Surg Neurol* 1977;7:117-21.

20. Wilkinson AG, Sellar RJ. Case report: cerebral metastases from choriocarcinoma in the absence of detectable extracranial disease. Clin Radiol 1991;43:278-9.

## ■ 국문 초록 ■

음모상피암은 가임여성에서 발생하는 부인암으로 항암화학요법만으로도 치료효과가 탁월한 특징을 갖고며 질병의 조기진단과 예후점수제(Risk scoring system)을 바탕으로한 적절한 치료로 인해 그 치료률은 90%에 달한다. 음모상피암은 항암화학요법만으로도 높은 치료성적을 보이기 때문에 보조적 방사선요법이나 수술적요법은 조절되지 않는 출혈이나 약물내성을 보이는 암종의 경우가 아니면 점차 기피되어지고 있는 것이 사실이다. 그러나 최고 25%정도의 고위험군은 항암화학요법에 부분관해를 보이거나 재발하며, 폐 또는 뇌전이를 갖는 환자에서는 치료률이 매우 떨어진다. 따라서 고위험 음모상피암의 치료성적의 향상을 위해서는 적극적인 수술적치료와 방사선요법의 조기 병합의 필요성이 강조되어야 한다. 이에 저자들은 본원에서 뇌전이를 갖는 고위험 음모상피암 환자에서 먼저 수술적으로 병변을 제거한뒤 방사선요법과 복합항암화학요법을 시행하여 성공적으로 완전관해를 경험하였기에 문헌고찰과 함께 증례보고하는 바이다.

**중심단어 :** 음모상피암, 뇌전이, 다방법병합요법.