

CASE REPORT

# 만성 C형간염에 관한 직접작용항바이러스 치료 후 호전된 난치성 간성 흉수

김명희<sup>1</sup>, 김덕기<sup>1</sup>, 은혁수<sup>1,2</sup>, 류우선<sup>1,2</sup>, 김석현<sup>1,2</sup>, 이병석<sup>1,2</sup>

충남대학교병원 소화기내과<sup>1</sup>, 충남대학교 의과대학 내과학교실<sup>2</sup>

## Refractory Hepatic Hydrothorax in Chronic Hepatitis C Controlled by Direct-acting Antivirals

Myung Hee Kim<sup>1</sup>, Duk Ki Kim<sup>1</sup>, Hyuk Soo Eun<sup>1,2</sup>, Woo Sun Rou<sup>1,2</sup>, Seok Hyun Kim<sup>1,2</sup> and Byung Seok Lee<sup>1,2</sup>

Division of Gastroenterology, Department of Internal Medicine, Chungnam National University Hospital<sup>1</sup>; Department of Internal Medicine, Chungnam National University College of Medicine<sup>2</sup>, Daejeon, Korea

Hepatic hydrothorax is a transudative pleural effusion that complicates advanced liver cirrhosis. Patients refractory to medical treatment plus salt restriction and diuretics are considered to have refractory hepatic hydrothorax and may require transjugular intrahepatic portosystemic shunt (TIPS) or liver transplant. Successful antiviral therapy reduces the incidence of some complications of cirrhosis secondary to HCV infection. We report a case of hepatic hydrothorax in a 55-year-old female patient with HCV cirrhosis, which exhibited a spontaneous decrease in pleural effusion after direct antiviral agent (DAA) therapy. In cases of HCV cirrhosis, DAAs are worth administering before treatment by TIPS or liver transplantation. (*Korean J Gastroenterol* 2020;75:98-102)

**Key Words:** Hydrothorax; Liver cirrhosis; Hepacivirus; Pleural effusion

## INTRODUCTION

Hepatic hydrothorax is a rare complication of liver cirrhosis (LC), with a reported prevalence of approximately 4-12%.<sup>1</sup> The treatment option for hepatic hydrothorax is the same as that for ascites. Initially, patients are prescribed a low-salt diet, and the diuretic dose is adjusted. However, only 20-50% of patients are responsive to this treatment. Hence, additional treatment options such as chest catheter drainage, transjugular intrahepatic portosystemic shunt (TIPS), and liver transplantation should be considered in non-responsive patients.<sup>2</sup> Nonetheless, despite various treatment options, the only complete cure for hepatic hydrothorax is liver transplantation.

## CASE REPORT

A 55-year-old female patient was hospitalized for dyspnea at rest and on exertion of 2 months duration, which aggravated 2 weeks prior to admission. The patient also had HCV-related LC (Child-Pugh class B) and type 2 diabetes mellitus.

She had been diagnosed with chronic hepatitis C genotype 2b in 2002, and had a history of treatment failure for peg-interferon and ribavirin. In 2008, cirrhotic change was detected for the first time by ultrasonography, and in 2013, she started taking diuretics for ascites, but experienced difficulty tolerating diuretics at sufficient doses (furosemide >40 mg and spi-

Received August 17, 2019. Revised October 25, 2019. Accepted October 27, 2019.

© This is an open access article distributed under the terms of the Creative Commons Attribution Non-Commercial License (<http://creativecommons.org/licenses/by-nc/4.0>) which permits unrestricted non-commercial use, distribution, and reproduction in any medium, provided the original work is properly cited.

Copyright © 2020. Korean Society of Gastroenterology.

교신저자: 이병석, 35015, 대전시 중구 문화로 282, 충남대학교병원 소화기내과

Correspondence to: Byung Seok Lee, Division of Gastroenterology, Department of Internal Medicine, Chungnam National University Hospital, 282 Munhwa-ro, Jung-gu, Daejeon 35015, Korea. Tel: +82-42-280-7164, Fax: +82-42-280-7402, E-mail: gie001@cnuh.co.kr, ORCID: <https://orcid.org/0000-0002-4669-8892>

Financial support: None. Conflict of interest: None.

ronolactone >100 mg daily).

In 2016, she was found to have decompensated LC (Child-Pugh class C, Child-Turcotte-Pugh score 10) (Fig. 1), and as a result, direct antiviral agent (DAA) therapy (sofosbuvir 400 mg, daclatasvir 60 mg, and ribavirin 800 mg daily) was started. Four weeks later HCV RNA was not detected.

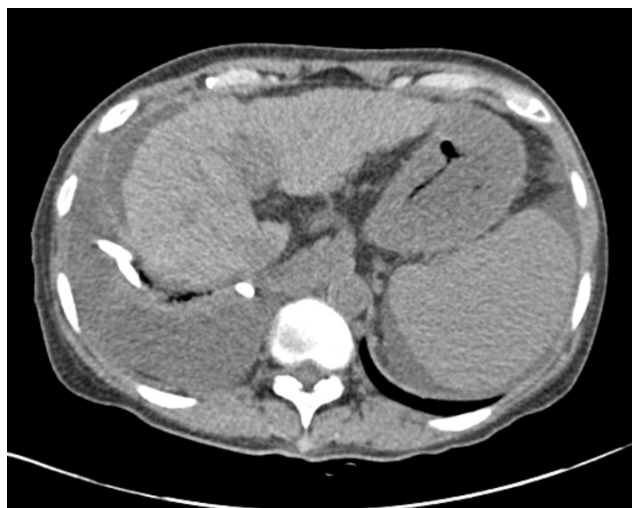After 1 month of DAA treatment, she complained of dyspnea on exertion, and right pleural effusion was noted (Fig. 2A). Pleural fluid analysis revealed the following: total protein 1.3 g/dL, albumin 0.7 g/dL, white blood cell count 55/mm<sup>3</sup>, and adenosine deaminase level 6.1 U/L. At this time, tuberculosis PCR and cytology were negative. Hepatic hydrothorax was diagnosed and she underwent therapeutic thoracentesis fortnightly. However, symptoms aggravated despite intermittent

thoracentesis, and she was admitted for management of hydrothorax after 2 months of DAA treatment.

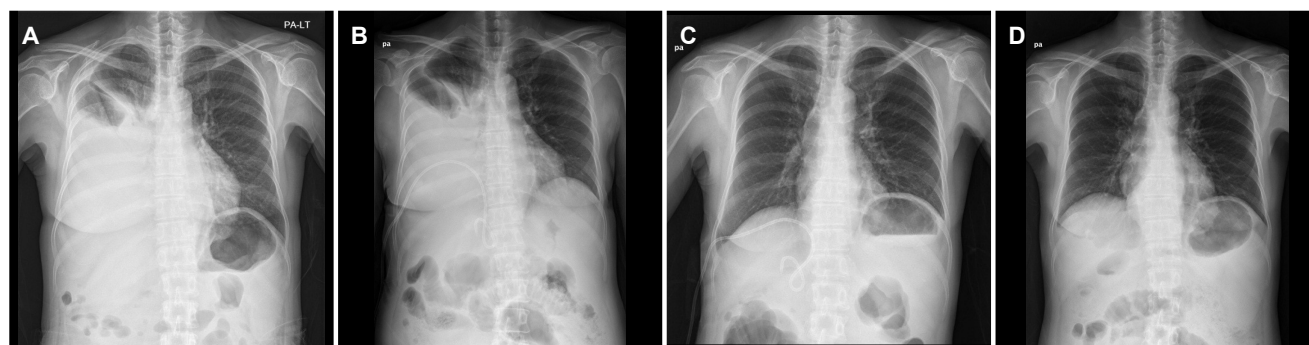
At admission, blood tests showed the following: AST 28 U/L, ALT 20 U/L, total bilirubin 3.53 mg/dL, albumin 2.9 g/dL, INR 1.33, Na<sup>+</sup> 134 mEq/L, and HCV RNA <41 copies/mL. A strict low-salt diet was started and an effort was made to increase diuretic dosage, but this proved ineffective at controlling hydrothorax and resulted in hyponatremia (Na<sup>+</sup> 119 mEq/L).

To control the refractory hepatic hydrothorax, a percutaneous pig-tail catheter was inserted into the right pleural cavity (Fig. 2B). About 500-1,000 mL of fluid was drained daily and the pleural fluid disappeared (Fig. 2C). Next, pleurodesis was tried with Abnoba viscum, but it failed to achieve pleural adhesion or enable catheter removal. Liver transplantation could not be considered because of the absence of a living donor and economic problems. The patient was reluctant to undergo TIPS due to concerns about hepatic encephalopathy.

Finally, she chose to be discharged and to maintain the pig-tail catheter for persistent pleural effusion drainage. The amount of drained fluid reduced to 100 mL/day and catheter removal was possible at 40 days after insertion. DAA was maintained during the planned treatment period (12 weeks), and persistent viral suppression was accomplished at the end of the treatment period when liver function improved to Child-Pugh class B (Child-Turcotte-Pugh score 8). She underwent regular check-ups for liver function without recurrence of pleural effusion for 1 month after discharge (Fig. 2D), and after 24 weeks of therapy achieved sustained virologic response (SVR). HCV-RNA was at 8,470 IU/mL before the initiation of antiviral therapy and became undetectable at 12



**Fig. 1.** Abdomen computed tomography finding at admission. The liver was shrunken and showed surface nodularity, and a moderate amount of ascites was noted near the liver. Right massive pleural effusion post pig-tail catheter drainage.



**Fig. 2.** Serial chest X-ray findings of hepatic hydrothorax. (A) A large amount of fluid had collected in the right pleural cavity at admission. (B) Insertion of a pig-tail catheter in the right pleural cavity (C) resulted in complete effusion drainage. (D) At 1 month after discharge, no residual effusion was noted. PA, posteroanterior.

and 24 weeks post-treatment, which confirmed the maintenance of SVR.

## DISCUSSION

The symptoms of hepatic hydrothorax vary. As the pleural cavity is smaller than the peritoneal cavity, symptoms occur when >500-1,000 mL of fluid accumulates in the pleural cavity, which is smaller than the amount of ascites required to induce symptoms.<sup>3</sup> The pathophysiology of hepatic hydrothorax has not been clearly described, but two theories have been proposed to explain its development. The first traditional theory is that hepatic hydrothorax results from hypoalbuminemia and portal hypertension and fluid shifts in the pleural space with/without passage to the diaphragm.<sup>4</sup> However, this theory cannot explain why pleural effusion in cirrhosis is predominantly right-sided. The second or fine diaphragmatic hole theory posits that ascites flow into the pleural cavity occurs via diaphragmatic defects due to the effect of abdominal pressure.<sup>5</sup> This process has been demonstrated by peritoneal scintigraphy many times. The defects concerned are usually small (<1 cm), more prevalent on the tendinous portion of the diaphragm, and more common in the right hemidiaphragm (right to left ratio ~4:1).

Initially, thoracentesis can be repeatedly performed when a patient has pleural fluid and symptom control is needed. Drainage of ≤500-1,000 mL per one time is recommended. As is the case for ascites, diuretic therapy can be attempted in addition to a low-salt diet. However, only approximately 20-50% of patients respond to medical therapy, and most of those that respond experience the side effects of high-dose diuretics, which include electrolyte imbalance and renal dysfunction.<sup>3</sup> If medical therapy with thoracentesis fails, non-medical therapy such as chest catheter or tube drainage with pleurodesis, TIPS, liver transplantation, or surgical intervention should be considered. TIPS is a treatment modality in which a shunt is placed between the inflowing portal vein and the outflowing hepatic vein. Generally, 50-70% of hepatic hydrothorax cases improve when a TIPS is inserted,<sup>6</sup> but it has been reported that about 30% of patients that undergo this procedure experience an acute episode of hepatic encephalopathy. In one report, a total of 20 episodes occurred in 15 patients with acute precipitated hepatic encephalopathy and 14 episodes occurred during the first 3 months

of follow-up.<sup>7</sup> Liver transplantation is a treatment option that must be considered in refractory hepatic hydrothorax,<sup>4</sup> because the median survival rate of patients with hepatic hydrothorax is only 1 year. However, the problem is that most patients with hepatic hydrothorax are not immediately viewed as transplant recipients. Currently, Model for End-Stage Liver Disease scores are used as the organ allocation criterion for liver transplantation, and many hepatic hydrothorax patients achieve scores sufficient to justify urgent liver transplantation. Hence, study is required to evaluate whether the liver transplantation allocation system should be revised so as to allocate additional points for refractory hydrothorax uncontrolled by repeated thoracentesis or TIPS. Pleurodesis is a medical procedure in which the pleural space is artificially obliterated by causing adhesion between pleurae. Reportedly, the procedure is effective in around 50% patients but has a high complication rate.<sup>8</sup>

Prior to the release of DAAs, SVRs of genotypes 2 and 3 chronic hepatitis C treated with peginterferon and ribavirin are observed in 80-90% of cases. However, side effects such as leukopenia and thrombocytopenia caused by interferon act as barriers to hepatitis C treatment.<sup>9,10</sup> DAAs are relatively safe and effective and can be expected to cure >90% of hepatitis C patients.<sup>11</sup> However, patients with advanced LC are at high risk of death due to the development of several hepatic decompensation situations, including ascites, spontaneous bacterial peritonitis, hepatic encephalopathy, and variceal bleeding. Recently, DAAs have been shown to reduce HCV viral load in patients with decompensated LC and improve liver fibrosis, and thus, DAAs are recommended even in cases of decompensated LC.<sup>12,13</sup> However, some patients with advanced LC do not respond to DAA treatment and in such patients liver function may be aggravated. Therefore, liver transplantation rather than DAA treatment should be recommended to patients not expected to recover liver function by antiviral treatment. DAA treatment was initiated in our patient in April 2016, that is, before DAA regimen studies had been completed. At the time, according to the 2015 Korean Association for the Study of the Liver clinical practice guideline, sofosbuvir and ribavirin for 16-24 weeks, sofosbuvir/dacatasvir with ribavirin for 12 weeks, or sofosbuvir/dacatasvir for 24 weeks were recommended for decompensated LC with genotype 2 HCV infection.<sup>14</sup> Studies on the efficacy of DAA therapy for decompensated LC were limited before

a clear guideline was issued. A small number of studies on HCV/human immunodeficiency virus coinfection demonstrated the effects of sofosbuvir plus ribavirin or daclatasvir plus sofosbuvir regimens on compensated LC with genotype 2 HCV infection. Another study demonstrated the efficacy of daclatasvir, sofosbuvir, and ribavirin in six patients with Child-Pugh class B and C genotype 2 HCV infection.<sup>15,16</sup> Recent studies have reported the improvement in the severity of cirrhosis and portal hypertension-related symptoms after DAA therapy. For example, in a recent meta-analysis, eradication of HCV infection and significant decreases in liver stiffness were found in certain patients, particularly in those with a high baseline level of inflammation.<sup>17</sup> In addition, in a study by Afdhal et al.<sup>18</sup> on 33 cirrhotic patients with a hepatic venous pressure gradient (HVPG) of >6 mmHg who were treated with sofosbuvir and ribavirin for 48 weeks, 24% of patients achieved a 20% decrease in HVPG. The authors also reported that a higher baseline Model for End-Stage Liver Disease score was associated with higher HVPG response ( $p=0.04$ ).<sup>19</sup> Cases in which ascites or hydrothorax have improved after DAA treatment are rare. Maged reported two cases of improved hepatic hydrothorax in end-stage renal disease patients with genotype 1a or 4 HCV infections treated with DAAs and hemodialysis.<sup>20</sup> Romano et al.<sup>21</sup> reported decompensated HCV cirrhotic patients that achieved SVR on DAA showed significant reductions in the manifestations of hepatic decompensation that were sustained for up to 1 year after SVR, and reported ascites was resolved in 35% of patients ( $p<0.01$ ) and hepatic encephalopathy in 54% of patients ( $p<0.01$ ). Variceal bleeding was absent in 32% of the patients ( $p<0.01$ ). Both studies showed, as was observed in our case, DAAs improved the symptoms of decompensated LC in decompensated HCV-related LC.

In conclusion, the described case suggests that some patients with refractory hepatic hydrothorax in HCV-related LC might respond to DAAs without other treatment modalities like TIPS or liver transplantation. However, we emphasize the importance of excluding patients with advanced cirrhosis at the point of no return from before starting antiviral treatment.

## ACKNOWLEDGMENT

We thank Dr. Duk ki Kim for providing the original idea for this case report, although he could not complete this paper

because of personal circumstances.

## REFERENCES

1. Badillo R, Rockey DC. Hepatic hydrothorax: clinical features, management, and outcomes in 77 patients and review of the literature. *Medicine (Baltimore)* 2014;93:135-142.
2. Porcel JM. Management of refractory hepatic hydrothorax. *Curr Opin Pulm Med* 2014;20:352-357.
3. Roussos A, Philippou N, Mantzaris GJ, Gourgoulisannis KI. Hepatic hydrothorax: pathophysiology diagnosis and management. *J Gastroenterol Hepatol* 2007;22:1388-1393.
4. Al-Zoubi RK, Abu Ghanimeh M, Gohar A, Salzman GA, Yousef O. Hepatic hydrothorax: clinical review and update on consensus guidelines. *Hosp Pract (1995)* 2016;44:213-223.
5. Huang PM, Chang YL, Yang CY, Lee YC. The morphology of diaphragmatic defects in hepatic hydrothorax: thoracoscopic finding. *J Thorac Cardiovasc Surg* 2005;130:141-145.
6. Ditch IC, Al Bawardy BF, Saberi B, Ditch C, Kamath PS. Transjugular intrahepatic portosystemic stent shunt for medically refractory hepatic hydrothorax: a systematic review and cumulative meta-analysis. *World J Hepatol* 2015;7:1797-1806.
7. Riggio O, Merlli M, Pedretti G, et al. Hepatic encephalopathy after transjugular intrahepatic portosystemic shunt. Incidence and risk factors. *Dig Dis Sci* 1996;41:578-584.
8. Hou F, Qi X, Guo X. Effectiveness and safety of pleurodesis for hepatic hydrothorax: a systematic review and meta-analysis. *Dig Dis Sci* 2016;61:3321-3334.
9. Jin YJ, Lee JW, Lee JI, et al. Efficacy and tolerability of peginterferon alpha plus ribavirin in the routine daily treatment of chronic hepatitis C patients in Korea: a multi-center, retrospective observational study. *Gut Liver* 2012;6:98-106.
10. Jin YJ, Lee JW, Lee JI, et al. Multicenter comparison of PEG-IFN  $\alpha 2a$  or  $\alpha 2b$  plus ribavirin for treatment-naïve HCV patient in Korean population. *BMC Gastroenterol* 2013;13:74.
11. Dusheiko G. The impact of antiviral therapy for hepatitis C on the quality of life: a perspective. *Liver Int* 2017;37 Suppl 1:7-12.
12. HCV guidance: recommendations for testing, managing, and treating hepatitis C. [Internet]. Alexandria (VA): American Association for the Study of Liver Diseases; 2017 Sep 21 [cited 2019 Jul 25]. Available from: <https://www.hcvguidelines.org/unique-populations/decompensated-cirrhosis>
13. El-Sherif O, Jiang ZG, Tapper EB, et al. Baseline factors associated with improvements in decompensated cirrhosis after direct-acting antiviral therapy for hepatitis C virus infection. *Gastroenterology* 2018;154:2111-2121.e8.
14. Kim YS. Updated treatment of chronic hepatitis C. *Korean J Med* 2017;92:24-35.
15. Wyles DL, Ruane PJ, Sulkowski MS, et al. Daclatasvir plus sofosbuvir for HCV in patients coinfecting with HIV-1. *N Engl J Med* 2015;373:714-725.
16. Sulkowski MS, Naggie S, Lalezari J, et al. Sofosbuvir and ribavirin for hepatitis C in patients with HIV coinfection. *JAMA* 2014;312:353-361.
17. Singh S, Facciorusso A, Loomba R, Falck-Ytter YT. Magnitude and

- kinetics of decrease in liver stiffness after antiviral therapy in patients with chronic hepatitis C: a systematic review and meta-analysis. *Clin Gastroenterol Hepatol* 2018;16:27-38.e4.
18. Afdhal N, Zeuzem S, Kwo P, et al. Ledipasvir and sofosbuvir for untreated HCV genotype 1 infection. *N Engl J Med* 2014;370:1889-1898.
19. Libânio D, Marinho RT. Impact of hepatitis C oral therapy in portal hypertension. *World J Gastroenterol* 2017;23:4669-4674.
20. Hussein MH, Peedikayil MC, Zamir ZA, Alfadda A. Resolution of refractory hepatic hydrothorax in patients with hepatitis C virus cirrhosis after treatment with direct-acting antiviral agents. *Ann Thorac Med* 2018;13:117-121.
21. Romano J, Sims OT, Richman J, et al. Resolution of ascites and hepatic encephalopathy and absence of variceal bleeding in decompensated hepatitis C virus cirrhosis patients. *JGH Open* 2018;317-321.