

CASE REPORT

위장관기질종양으로 오인된 공장 동정맥 기형

공은정, 김도훈, 정훈용, 최기돈, 송호준, 이진혁, 김진호, 박호섭¹

울산대학교 의과대학 서울아산병원 소화기내과학교실, 병리학교실¹

An Arteriovenous Malformation in the Jejunum Mimicking a Gastrointestinal Stromal Tumor

Eun Jeong Gong, Do Hoon Kim, Hwoon-Yong Jung, Kee Don Choi, Ho June Song, Gin Hyug Lee, Jin Ho Kim and Ho-Seop Park¹

Departments of Gastroenterology and Pathology¹, Asan Medical Center, University of Ulsan College of Medicine, Seoul, Korea

A 51-year-old man visited the tertiary-care hospital with a 2-week history of dizziness and dyspnea on exertion. The initial hemoglobin level was 5.8 g/dL, without any history of hematochezia or melena. The esophagogastroduodenoscopy (EGD) was normal. During colonoscopic preparation, the patient experienced hematochezia and became hypotensive. On angiography, no extravasation of contrast media was observed. A CT scan with angiography showed a small high-density area in the jejunal lumen, suggesting extravasation of the contrast media. Capsule endoscopy was performed, and oozing bleeding was suspected in the proximal to mid jejunum. The patient was referred to our hospital. Repeated EGD and CT enterography did not reveal any significant bleeding. An antegrade double balloon endoscopy was performed, and an approximately 2-cm-sized submucosal tumor with ulceration and a non-bleeding exposed vessel was observed in the mid jejunum. The presumed diagnosis was jejunal gastrointestinal stromal tumor. The mass was surgically resected, and the final histopathological diagnosis was arteriovenous malformation. (*Korean J Gastroenterol* 2014;63:42-46)

Key Words: Arteriovenous malformations; Jejunum; Gastrointestinal hemorrhage

INTRODUCTION

Vascular malformation is one of the causes of gastrointestinal (GI) bleeding. The most common type of intestinal vascular malformation is vascular ectasia or angiodysplasia, which typically affects the right colon in individuals older than 50 years.¹ Arteriovenous malformation (AVM) of the small intestine is a relatively uncommon cause of GI bleeding. Moreover, tumorous or polypoid AVM is extremely rare, and there are few reported cases of polypoid AVM presenting intestinal obstruction or intussusceptions.^{2,3} We here report a case of jejunal AVM misdiagnosed as a subepithelial tumor.

CASE REPORT

A 51-year-old man visited the tertiary care hospital with a 2-week history of dizziness and dyspnea on exertion. He was otherwise in good health with no history of GI bleeding. The hemoglobin level at the time of admission was 5.8 g/dL. Esophagogastroduodenoscopy (EGD) disclosed no abnormalities. During colonoscopic preparation, the patient exhibited hematochezia and became hypotensive. During urgent angiography, no extravasation of the contrast media or vascular abnormality was observed. Vital signs were stabilized after fluid resuscitation and transfusion. Colonoscopic examination revealed melena from proximal bowel, there-

Received April 13, 2013. Revised May 18, 2013. Accepted May 22, 2013.

© This is an open access article distributed under the terms of the Creative Commons Attribution Non-Commercial License (<http://creativecommons.org/licenses/by-nc/3.0>) which permits unrestricted non-commercial use, distribution, and reproduction in any medium, provided the original work is properly cited.

교신저자: 김도훈, 138-736, 서울시 송파구 올림픽로 43길 88, 울산대학교 의과대학 서울아산병원 소화기내과, 아산소화기병연구소

Correspondence to: Do Hoon Kim, Asan Digestive Disease Research Institute, Department of Gastroenterology, Asan Medical Center, University of Ulsan College of Medicine, 88 Olympic-ro 43-gil, Songpa-gu, Seoul 138-736, Korea. Tel: +82-2-3010-3193, Fax: +82-2-3010-6517, E-mail: dohoon.md@gmail.com

Financial support: None. Conflict of interest: None.

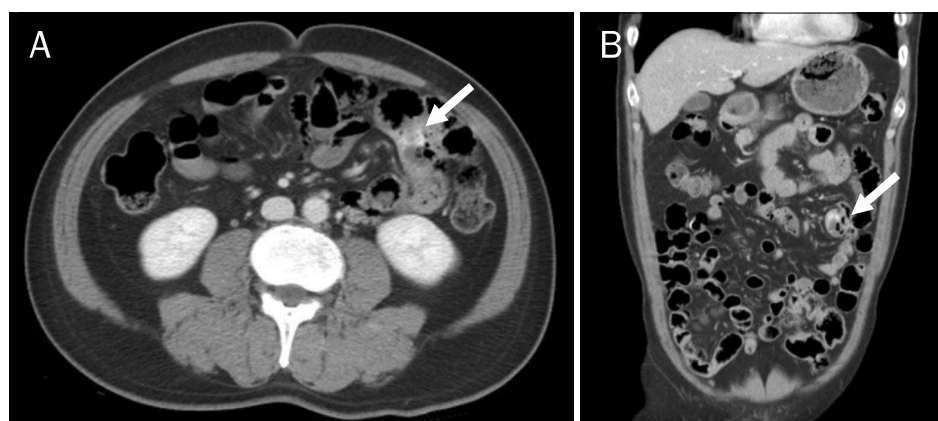


Fig. 1. Computed tomography scan with angiography performed at the referral hospital. (A) Axial scan revealed a small high-density area in the jejunal lumen (arrow). (B) A coronal view reconstruction revealed a small high-density area in the jejunal lumen (arrow).

fore small bowel bleeding was suspected. A subsequent CT scan with angiography showed a small high-density area in the jejunal lumen, suggesting extravasation of the contrast media (Fig. 1). Capsule endoscopy (CE) was performed to localize the site of bleeding, and oozing of blood in the proximal to mid jejunum was detected.

The patient was transferred to our institution for further investigation after a 5-day hospitalization. He had stable vital signs, and the hemoglobin level was 10.9 g/dL. Laboratory test results, including liver and renal function as well as the coagulation profile, were within normal limits. Repeated EGD and CT enterography performed on the next day did not reveal any significant bleeding. The patient remained stable, and there was no evidence of overt bleeding since the time of previous examination. On the 10th hospital day, an antegrade double balloon endoscopy (DBE) was performed, and an approximately 2-cm-sized submucosal tumor with surface ulceration and a non-bleeding exposed vessel was observed in the mid jejunum (Fig. 2). The presumed diagnosis was bleeding from a gastrointestinal stromal tumor (GIST) of the jejunum. We decided not to perform a biopsy because of the risk of massive and uncontrolled bleeding.

The patient underwent a small bowel resection. At laparotomy, the tumor mass approximately of 2 cm in diameter was palpated in the mid jejunum and successfully resected with the adjacent small bowel. The surgical specimen showed a well-demarcated protruding mass in the jejunum, which measured 1.8×1.0×1.0 cm. Histopathologic evaluation demonstrated mucosal necrosis with dilated submucosal vessels. The final histopathologic diagnosis was AVM (Fig. 3).

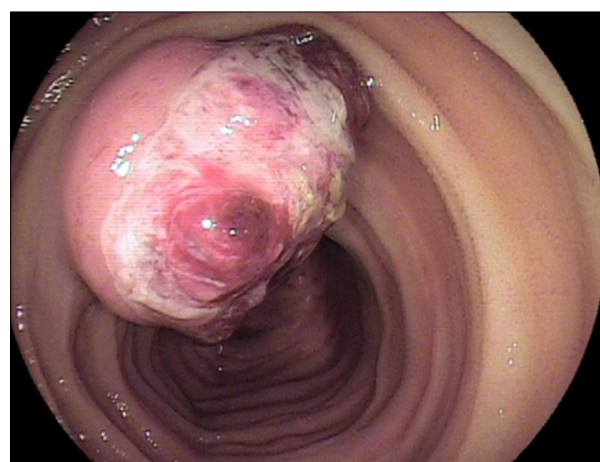


Fig. 2. During double balloon endoscopy, an approximately 2-cm-sized submucosal mass with an ulcer and a non-bleeding exposed vessel was observed in the mid jejunum. The presumed diagnosis was gastrointestinal stromal tumor with bleeding.

DISCUSSION

Although vascular malformations of the GI tract are common cause of GI bleeding, AVM of the small intestine is relatively rare. AVM can remain asymptomatic and is (usually/sometimes) noted during endoscopy resulting from examination for another indication. Otherwise, AVM may manifest itself with either chronic blood loss or recurrent bleeding or, more rarely, as an intestinal obstruction and intussusception.¹⁻³ Vascular malformations result in 2-5% increase in GI bleeding, and acute massive bleeding that leads to hemodynamic compromise is unusual.^{1,3,4}

Vascular malformations of the GI tract are abnormalities in the vascular architecture that usually affect arterial, venous, and capillary vessels, and sometimes affect lymphatic vessels. The most common type of intestinal vascular malfor-

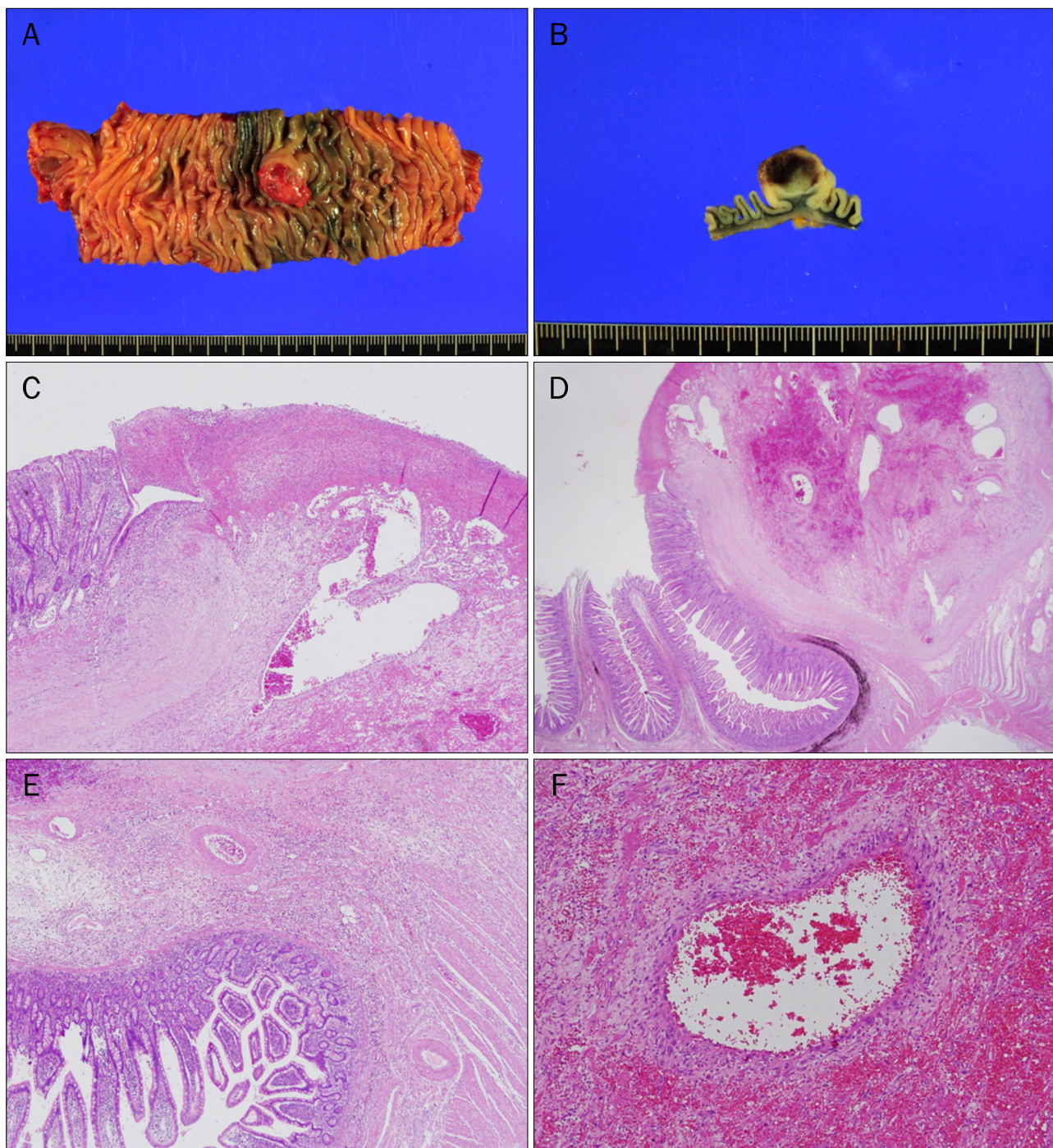


Fig. 3. Surgical specimens and pathologic findings. (A, B) The surgical specimen showed a well-demarcated protruding mass in the jejunum, which measured 1.8×1.0×1.0 cm. The cut surface was grayish brown colored with hemorrhagic change. (C-F) Histologic examination showed tangles of abnormal vessels in the submucosa. These various-sized vessels have characteristics of arteries and veins without intervening capillaries. The surface mucosa was severely eroded, involving the large vessel (H&E; C: ×40, D: ×12.5, E: ×40, F: ×100).

mation is vascular ectasia or angiodysplasia, which typically affects the cecum or right colon in people aged from 60 to over 80 years.^{1,5} AVM is clinically and histologically distinct from vascular ectasia and Dieulafoy's lesion. However, the

clinical differentiation of vascular malformations is difficult because these lesions have similar endoscopic appearance. Some reported instances of intestinal AVM have been described as flat or mildly elevated hemorrhagic spots or ero-

sions, whereas others appear as mass or polypoid lesions.⁶⁻⁸ AVMs of the small intestine that present a tumorous appearance, as in this case, are extremely rare.

Moore et al.⁹ classified vascular lesions into three types based on patient age, location, macroscopic appearance, and family history. Type 1 lesions, which usually occur in the elderly as small solitary lesions, typically affect the right colon. These lesions are thought to be acquired and are commonly referred to as angiodysplasia or vascular ectasia. Type 2 lesions, which occur in patients younger than 50 years, are most common in the small bowel and are often grossly visible as large submucosal vessels. These lesions are thought to be congenital. Type 3 lesions include hereditary hemorrhagic telangiectasia and are associated with respiratory and cutaneous lesions. According to the classification by Moore et al.,⁹ the present case corresponds to a type 2 lesion.

Recent efforts have aimed to classify vascular malformations based on pathologic findings.^{7,10} Angiodysplasia is primarily characterized by venous distension, and vascular ectasia is primarily characterized by dilated capillary vessels within the submucosa and often the mucosa. Dieulafoy's lesion is characterized by an abnormal, submucosal, caliber-persistent artery that typically protrudes through a mucosal defect.¹¹ In historical terms, AVMs appear as tangles of abnormal vessels of various sizes, that have characteristics of arteries and veins without intervening capillaries, and have clinical manifestations distinct from those characteristics of vascular ectasia or angiodysplasia.⁷

Yano et al.¹² classified vascular lesions in the small intestine into six groups, on the basis of endoscopic findings. Type 1a (punctuate erythema less than 1 mm) and 1b (patchy erythema) are venous or capillary lesions and are considered to be angioectasias. Type 2a (punctuate lesion less than 1 mm with pulsatile bleeding) and 2b (pulsatile red protrusion without surrounding venous dilatation) are arterial lesions and are considered to be Dieulafoy's lesions. Type 3 (pulsatile red protrusion with surrounding venous dilatation) are AVMs. Type 4 are vascular lesions with an unusual morphology and are unclassifiable. The presence or absence of arterial components provides important information in selecting the most appropriate endoscopic treatment. Angioectasia is a venous or capillary lesion that can be treated by endoscopic therapy. However, Dieulafoy's lesion and AVM may cause arterial bleeding.

The possibility of AVM should be considered in young patients with recurrent and obscure GI bleeding. The diagnosis of AVM is usually based on endoscopic findings, although angiography can be considered in a case of massive bleeding with hemodynamic instability. These two investigations are usually concordant. However, lesions that are inadequate for and do not permit rapid arterio-venous shunting or those with intermittent bleeding may not be detected angiographically.^{1,13} Given its nature of recurrent and intermittent bleeding, AVM of the small bowel can be overlooked despite a thorough examination, and multiple endoscopic sessions may be required. Endoscopic examination, and even CE, may not reveal the condition in patients with AVM of the small bowel.^{14,15} DBE, followed by CE, remains a mainstay in the diagnosis and treatment of small bowel lesions.¹⁵⁻¹⁷ The use of a CT scan may be an effective noninvasive method for detecting the site of bleeding.¹⁸ In the present case, CT angiography showed the contrast extravasation in the jejunum, and subsequent CE and DBE revealed subepithelial tumors with surface ulceration and exposed vessels in the jejunum.

Surgical excision has been the mainstay in the treatment of AVM, and some cases are diagnosed even after the resection.⁹ Moreover, some cases are likely to be managed via polypectomy before pathologic diagnosis since it is difficult to consider the possibility of a polypoid AVM relying on endoscopic appearance.^{2,15,19} With the introduction of DBE, endoscopic therapy has become another option for the treatment of certain AVM lesions.²⁰ Therapeutic endoscopy with a clip, thermocoagulation, polypectomy, or argon plasma coagulation may be the first-line treatment for small, discrete, and localized vascular lesions.^{1,15,19} However, these approaches are less likely to be successful for large submucosal vessels or lesions with arterial components. AVMs may result in life-threatening hemorrhage since they have persisting connections between arterial and venous components. Surgical resection is usually necessary as the definite treatment for type 2 vascular malformation, defined according to the classification by Moore et al.,⁹ and type 2 or 3 lesions, according to the classification by Yano et al.,¹² as was found in our case.

Although AVM of the small bowel rarely causes GI bleeding, it should be considered as a possible differential diagnosis in young patients with obscure GI bleeding. Endoscopic findings in cases of AVM can vary, and, especially, tumorous AVM

can be misdiagnosed as a GIST. The decision to perform a biopsy should be made with care because this procedure may lead to massive and uncontrolled bleeding. We experienced a rare case of jejunal AVM, which presented itself as a tumorous appearance with bleeding, and it was successfully treated by surgical resection.

REFERENCES

- Gordon FH, Watkinson A, Hodgson H. Vascular malformations of the gastrointestinal tract. *Best Pract Res Clin Gastroenterol* 2001;15:41-58.
- Rodríguez-Jurado R, Morales SS. Polypoid arteriovenous malformation in the jejunum of a child that mimics intussusception. *J Pediatr Surg* 2010;45:E9-E12.
- Yazbeck N, Mahfouz I, Majdalani M, Tawil A, Farra C, Akel S. Intestinal polypoid arteriovenous malformation: unusual presentation in a child and review of the literature. *Acta Paediatr* 2011;100:e141-e144.
- Kaler SG, Westman JA, Bernes SM, et al. Gastrointestinal hemorrhage associated with gastric polyps in Menkes disease. *J Pediatr* 1993;122:93-95.
- Meyer CT, Troncale FJ, Galloway S, Sheahan DG. Arteriovenous malformations of the bowel: an analysis of 22 cases and a review of the literature. *Medicine (Baltimore)* 1981;60:36-48.
- Cheon JH, Song HJ, Kim JS, et al. Recurrent lower gastrointestinal bleeding from congenital arteriovenous malformation in the terminal ileum mimicking intestinal varicosis: a case report. *J Korean Med Sci* 2007;22:746-749.
- Maeng L, Choi KY, Lee A, Kang CS, Kim KM. Polypoid arteriovenous malformation of colon mimicking inflammatory fibroid polyp. *J Gastroenterol* 2004;39:575-578.
- Krinsky ML, Robert ME, Garcia JC, Korzenik JR, Topazian M. Polypoid vascular malformations of the small intestine. *Gastrointest Endosc* 1998;48:530-533.
- Moore JD, Thompson NW, Appelman HD, Foley D. Arteriovenous malformations of the gastrointestinal tract. *Arch Surg* 1976;111:381-389.
- De Palma GD, Aprea G, Rega M, et al. Polypoid vascular malformation of the small intestine. *Gastrointest Endosc* 2007;65:328-329.
- Jain R, Chetty R. Dieulafoy disease of the colon. *Arch Pathol Lab Med* 2009;133:1865-1867.
- Yano T, Yamamoto H, Sunada K, et al. Endoscopic classification of vascular lesions of the small intestine (with videos). *Gastrointest Endosc* 2008;67:169-172.
- Leighton JA, Goldstein J, Hirota W, et al. Obscure gastrointestinal bleeding. *Gastrointest Endosc* 2003;58:650-655.
- Chong AK, Chin BW, Meredith CG. Clinically significant small-bowel pathology identified by double-balloon enteroscopy but missed by capsule endoscopy. *Gastrointest Endosc* 2006;64:445-449.
- Endo H, Matsushashi N, Inamori M, et al. Tumorous arteriovenous malformation in the jejunum missed by capsule endoscopy. *Gastrointest Endosc* 2008;68:773-774.
- Cui J, Huang LY, Wu CR. Small intestinal vascular malformation bleeding: diagnosis by double-balloon enteroscopy combined with abdominal contrast-enhanced CT examination. *Abdom Imaging* 2012;37:35-40.
- Hansel SL, Decker GA, Shiff AD. Thirty years of overt, obscure GI bleeding solved by modern technology. *Gastrointest Endosc* 2009;70:595-597.
- Nakabayashi T, Kudo M, Hirasawa T, Kuwano H. Arteriovenous malformation of the jejunum detected by arterial-phase enhanced helical CT, a case report. *Hepatogastroenterology* 2004;51:1066-1068.
- Ji JS, Choi KY, Lee BI, et al. A large polypoid arteriovenous malformation of the colon treated with a detachable snare: case report and review of literature. *Gastrointest Endosc* 2005;62:172-175.
- Liao Z, Gao R, Li ZS. Vascular malformation of the small intestine. *Endoscopy* 2007;39(Suppl 1):E319.