

CASE REPORT

대장내시경 검사 후에 발생한 결장간막 열상

최용준, 박진석, 김경은, 한지영, 나소연, 방병욱

인하대학교 의과대학 내과학교실

Mesocolon Laceration Following Colonoscopy

Yong-jun Choi, Jin-Seok Park, Gyung Eun Kim, Jee Young Han, So-Yun Nah and Byoung Wook Bang

Department of Internal Medicine, Inha University School of Medicine, Incheon, Korea

Colonoscopic examination is a safe procedure, however, unexpected complications can sometimes occur. Bleeding and perforation of the colon have been reported as the most common complications. Hemoperitoneum after colonoscopy is an unusual complication, but it may be catastrophic. We report on a 20-year-old man who experienced left low quadrant pain after undergoing colonoscopy. Hemoperitoneum was diagnosed using abdominal CT. A laparoscopic exploration was urgently performed, revealing a lacerated mesocolon of the descending colon. Bleeding of the injured site was controlled without complication. The patient recovered fully without signs of recurrent bleeding. This report implies that if the patient has persistent abdominal pain after undergoing colonoscopy, we should consider hemoperitoneum as one of the causes. To the best of our knowledge, no case of isolated laceration of the mesocolon of the descending colon after colonoscopy has been reported. (*Korean J Gastroenterol* 2014;63:313-315)

Key Words: Mesocolon; Colonoscopy; Hemoperitoneum

INTRODUCTION

Colonoscopy is widely used for diagnosis of colorectal disease and carries low risk of complication. Common complications include lower gastrointestinal bleeding and colonic perforation.¹ Extra-colonic or visceral injuries, including pneumothorax, pneumomediastinum, acute appendicitis, retroperitoneal abscess, and others, are far less common.² Hemoperitoneum is a rare complication of colonoscopy, and mostly associated with trauma of the spleen. We describe herein a patient having hemoperitoneum caused by a laceration of the mesocolon following a colonoscopy.

CASE REPORT

A 20-year-old male was experiencing intermittent hematochezia and constipation. He had a family history of colon cancer and wanted to undergo a colonoscopy. He had undergone an appendectomy with perforated appendicitis three years ago and a hemorrhoidectomy one year ago. A colonoscopy was performed in order to exclude colorectal cancer or other causes of bleeding. The scope was inserted up to the terminal ileum under conscious sedation. The cecal intubation time was approximately 20 minutes. Except for several manual compressions of the abdominal wall and complaints of mild abdominal discomfort, technically, approaching the cecum was not difficult. There was no specific lesion,

Received September 12, 2013. Revised October 31, 2013. Accepted November 5, 2013.

© This is an open access article distributed under the terms of the Creative Commons Attribution Non-Commercial License (<http://creativecommons.org/licenses/by-nc/3.0>) which permits unrestricted non-commercial use, distribution, and reproduction in any medium, provided the original work is properly cited.

교신저자: 방병욱, 400-711, 인천시 중구 인항로 27, 인하대학교 의과대학 내과학교실 소화기내과

Correspondence to: Byoung Wook Bang, Division of Gastroenterology, Department of Internal Medicine, Inha University School of Medicine, 27 Inhang-ro, Jung-gu, Incheon 400-711, Korea. Tel: +82-32-890-2548, Fax: +82-32-890-2549, E-mail: bangbyoung@naver.com

Financial support: None. Conflict of interest: None.

except for an internal hemorrhoid.

Eight hours after the examination, the patient complained of left lower quadrant abdominal pain. He was alert and pale in appearance. Blood pressure was 140/80 mmHg and his pulse rate was 110/min. There was a direct tenderness on the left lower quadrant, but rebound tenderness was not definite. Digital rectal examination was normal. Hemoglobin level was 14.4 g/dL and white blood cell count was $8.3 \times 10^6/\mu\text{L}$. Other laboratory findings were unremarkable. A colon perforation was clinically suspected because he complained of severe abdominal pain. Plain x-ray of the chest excluded pneumoperitoneum (Fig. 1). An abdominal CT scan showed moderate amounts of fluid collection in subhepatic space and pelvic cavity. The density level denoted blood, and there was no evidence of spleen injury (Fig. 2).

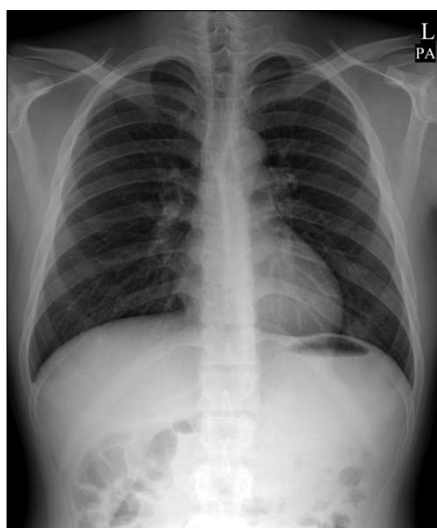


Fig. 1. Plain chest X-ray showed the absence of pneumoperitoneum.

Approximately 12 hours after the examination, the patient complained of severe abdominal pain, and there was definite tenderness and rebound tenderness on the left lower quadrant area. His hemoglobin level fell from 14.4 to 9.0 g/dL, his blood pressure fell to 93/60 mmHg, and his pulse rate was 130/min. Laparoscopic exploration was performed for discovery of the source of the bleeding. The laparoscopic examination revealed a moderate amount of blood in the abdominal cavity, and the source of bleeding was due to a lacerated mesocolon of the distal descending colon. Oozing bleeding was observed on the laceration site (Fig. 3). The colon, liver, and spleen were normal in appearance. Laparoscopic heat probe coagulation was performed for hemostasis. The postoperative course was uneventful, and the patient was discharged after seven days.

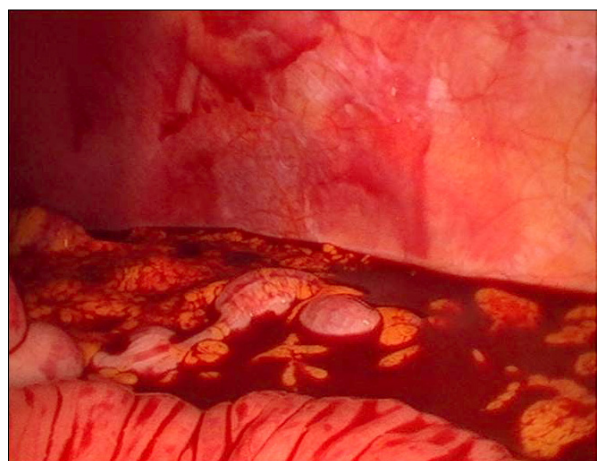


Fig. 3. Laparoscopic finding showed a moderate amount of blood in the pelvic cavity.

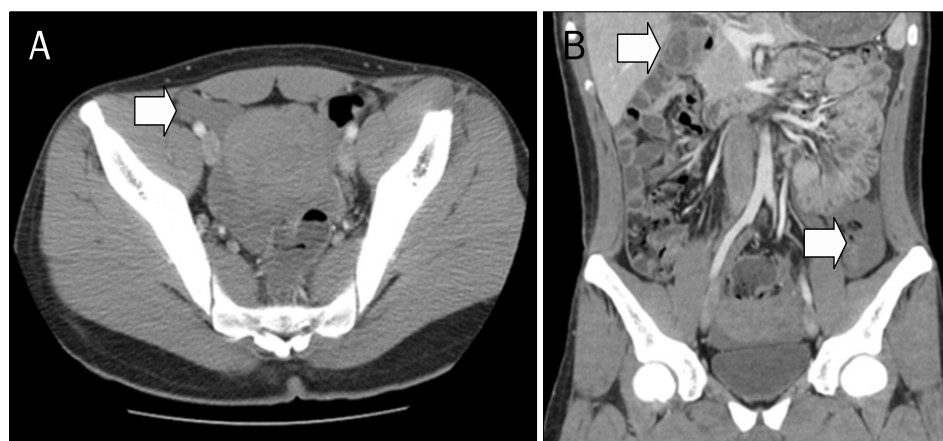

Fig. 2. Abdominal CT showed hyper-attenuated fluid collections (Hounsfield unit: 40-60) in the anterior aspect of the sigmoid colon of the pelvic cavity, both paracolic gutters and right subhepatic space, suggesting intraperitoneal hemorrhage (arrow: A, axial image; B, reformatted coronal image).

DISCUSSION

Nowadays, colonoscopy is an essential method for diagnosis and treatment of any colorectal pathology. In most cases, it is a safe, tolerated, and easily available procedure. Therefore, the use of colonoscopy has shown a gradual increase. In general, any complications after colonoscopy are rare. Among them, intra-luminal hemorrhage and colon perforation are the two most common complications, with an incidence of 1-2% and 0.1-0.2%, respectively.³ Intra-abdominal hemorrhage is a rare complication of colonoscopy, and most commonly results from injury to spleen or laceration of colonic mesentery.⁴ In previous series, other less common causes of hemoperitoneum include a ruptured epiploic appendix, a torn mesenteric vessel, and a necrosed intestinal leiomyosarcoma.⁵⁻⁷

Splenic laceration or rupture can develop by excessive traction on the splenocolic ligament with subsequent avulsion of the splenic capsule and by specific maneuvers that may apply additional strain on the splenocolic ligament.⁸ Colonic mesentery injury after colonoscopy can occur by similar previously described mechanisms causing splenic injury. The mechanism for this type of injury is presumed to result from excessive traction on the mesentery, which can occur in the setting of abdominal adhesions. Certain maneuvers such as the slide-by, alpha-maneuver, and straightening of the sigmoid loop can increase tension on the mesentery, with resultant hemorrhage.⁹

Few cases of laceration of mesocolon have been reported,¹⁰ and this is the first case of a laceration of the descending colon. The descending colon is usually fixed to retroperitoneum; however, when mesocolon of the descending colon exists, descending colon is not fixed but movable. As a result, performance of colonoscopy is difficult in patients with descending mesocolon because loops are easily developed. Furthermore, it may be reasonable to suggest that prior abdominal surgery might provoke adhesions with adjacent vessels. Vessels attached with mesocolon due to adhesion might be avulsed or torn with enforced insertion of colonoscopy. A CT scan provides valuable diagnostic information for detection of hemoperitoneum.¹¹ However, a more definitive diagnosis requires a laparotomy, and hemostasis can be achieved with a laparotomy. In this case, oozing bleeding was well controlled with a laparotomy.

Hemoperitoneum is frequently a catastrophic condition, which may quickly become fatal even when appropriate treatment is administered. Hypotension and decreasing hemoglobin level suggest the possibility of hemoperitoneum. However, as seen in this patient, it is not easy to diagnose clinically if a patient initially has normal blood pressure and hemoglobin level. CT is the imaging modality of choice for diagnosis of hemoperitoneum, and is useful for differential diagnosis. To the best of our knowledge, no previous report describing a case of hemoperitoneum by laceration of mesocolon around the descending colon has been reported. As colonoscopies are performed widely, physicians need to consider hemoperitoneum as a potential cause of abdominal pain after colonoscopy.

REFERENCES

1. Oh JE, Shim SG. Colonoscopic perforation; a 10-year experience in single general hospital. *Korean J Gastroenterol* 2009;54:371-376.
2. Schwesinger WH, Levine BA, Ramos R. Complications in colonoscopy. *Surg Gynecol Obstet* 1979;148:270-281.
3. Wexner SD, Garbus JE, Singh JJ; SAGES Colonoscopy Study Outcomes Group. A prospective analysis of 13,580 colonoscopies. Reevaluation of credentialing guidelines. *Surg Endosc* 2001;15:251-261.
4. Doctor NM, Monteleone F, Zarmakoupis C, Khalife M. Splenic injury as a complication of colonoscopy and polypectomy. Report of a case and review of the literature. *Dis Colon Rectum* 1987;30:967-968.
5. Sorrentino M, Terrosu G, Risaliti A, et al. Hemoperitoneum caused by lesions to the appendix epiploica. An unusual complication of colonoscopy. *Minerva Chir* 1996;51:835-837.
6. Salvador Milian E, Lorente Perez S, Arroyo Villarino MT, Sainz Samitier R. Hemoperitoneum as a complication of diagnostic colonoscopy. *Gastroenterol Hepatol* 1999;22:377.
7. González-Rodríguez JF, Tarquis-Alonso P, Castano-Pascual A, González-Lera S. Hemoperitoneum due to necrosis of a small intestinal leiomyosarcoma following colonoscopy. *Endoscopy* 1993;25:253-254.
8. Levine E, Wetzel LH. Splenic trauma during colonoscopy. *AJR Am J Roentgenol* 1987;149:939-940.
9. Dominitz JA, Eisen GM, Baron TH, et al. Complications of colonoscopy. *Gastrointest Endosc* 2003;57:441-445.
10. Hernandez EJ, Ellington RT, Harford WV. Isolated transverse mesocolon laceration during routine colonoscopy. *J Clin Gastroenterol* 1999;28:46-48.
11. Federle MP, Goldberg HI, Kaiser JA, Moss AA, Jeffrey RB Jr, Mall JC. Evaluation of abdominal trauma by computed tomography. *Radiology* 1981;138:637-644.