

CASE REPORT

간암 고주파 열 치료술 후에 발생한 횡경막 탈장 1예

김종선, 김형상, 명대성, 이기훈, 박강진, 조성범, 주영은, 최성규
전남대학교 의과대학 내과학교실

A Case of Diaphragmatic Hernia Induced by Radiofrequency Ablation for Hepatocellular Carcinoma

Jong Sun Kim, Hyung Sang Kim, Dae Sung Myung, Gi Hoon Lee, Kang Jin Park, Sung Bum Cho, Young Eun Joo and Sung Kyu Choi
Department of Internal Medicine, Chonnam National University Medical School, Gwangju, Korea

Because of its safety and treatment effectiveness, the popularity of radiofrequency ablation (RFA) for the treatment of hepatocellular carcinoma (HCC) has gradually increased. However, some serious complications of RFA such as hepatic infarction, bowel perforation, and tumor seeding have been reported. Recently, we experienced a case of diaphragmatic hernia after RFA for HCC. A 61-year-old man with alcoholic cirrhosis was diagnosed with a 1.0 cm sized HCC in segment (S) 5 and a 1.3 cm sized HCC in S 8 of the liver. He was treated by transarterial chemoembolization and RFA. After RFA, an abdominal CT revealed a diaphragmatic defect with herniating mesentery. Twenty-two months after the RFA, the chest CT showed the diaphragmatic defect with herniating colon and mesentery. Because he had no symptoms, and surgical repair for the diaphragmatic hernia would be a high risk operation for him, we decided to treat the patient conservatively. For its great rarity, we report this case with a review of the literature. (*Korean J Gastroenterol* 2013;62:174-178)

Key Words: Hepatocellular carcinoma; Catheter ablation; Diaphragmatic hernia

INTRODUCTION

Percutaneous radiofrequency ablation (RFA) is a thermal ablation technique for achieving coagulative necrosis of liver tumors.¹ Because of its safety and treatment effectiveness,² the popularity of RFA for the treatment of hepatocellular carcinoma (HCC) has gradually increased. Even though RFA is considered to be a relatively safe and a low invasive treatment for HCC, some serious complications of RFA such as hepatic infarction, hepatic abscess, perforation of the gastrointestinal wall, tumor seeding, biliary-duodenal fistula and abscesso-colonic fistula have been reported.³⁻⁵ Recently, we experienced a case of diaphragmatic hernia 9 months after

RFA for HCC. Rarely, diaphragmatic hernia has been reported as a delayed complication of RFA for HCC. This is presumably the first case of a patient with diaphragmatic hernia after RFA in Korea. For its great rarity, we report this case with a review of the literature.

CASE REPORT

A 61-year-old man with alcoholic liver cirrhosis was admitted to our institution for the treatment of two HCCs, measuring 1.3 cm and 1.0 cm in diameter in segments (S) 5 and 8 of the liver, that were detected on dynamic liver MRI. He had a diabetes mellitus for 3 years treated by insulin. His family

Received January 8, 2013. Revised March 19, 2013. Accepted March 20, 2013.

© This is an open access article distributed under the terms of the Creative Commons Attribution Non-Commercial License (<http://creativecommons.org/licenses/by-nc/3.0>) which permits unrestricted non-commercial use, distribution, and reproduction in any medium, provided the original work is properly cited.

교신저자: 조성범, 501-757, 광주시 동구 백석로 160, 전남대학교 의과대학 내과학교실

Correspondence to: Sung Bum Cho, Department of Internal Medicine, Chonnam National University Medical School, 160 Baekseok-ro, Dong-gu, Gwangju 501-757, Korea. Tel: +82-62-220-4000, Fax: +82-62-232-9708, E-mail: portalvein@naver.com

Financial support: None. Conflict of interest: None.

history was noncontributory. The patient was treated by transarterial chemoembolization (TACE) and percutaneous RFA. Eleven months after the RFA and TACE, a lesion measuring 0.9 cm in the right hepatic dome (S 8) was identified as an HCC on dynamic liver MRI (Fig. 1). These findings were consistent with the findings on dynamic abdomen CT. Laboratory testing showed the following levels: white blood cell, 6,700/mm³; hemoglobin, 15.8 g/dL; platelet, 110,000/mm³; AST, 26 IU/L; ALT, 24 IU/L; ALP, 151 IU/L; GGT, 89 IU/L; albumin, 3.9 g/dL; total bilirubin, 0.9 mg/dL; prothrombin time, 13.6 sec; and AFP, 23.54 IU/mL. His hepatic function was classified as Child-Pugh Class A. After discussions with the hepatobiliary oncology team in our hospital, percutaneous RFA was performed to treat the HCC. RFA for the HCC, using a generator (Cool-Tip Radiofrequency System, Radionics®; Cosman Medical, Burlington, MA, USA) and internally cooled

electrodes (7.0-cm length 17-gauge 1.0-cm active-tip, Well-Point Radiofrequency Electrodes; Taewoong Medical, Gimpo, Korea), was done under ultrasonographic (US) guidance. US showed a 1.1×0.9 cm mass in S 8 that was adjacent to the diaphragm. After the RFA needle was positioned in the HCC by the short trans-hepatic route, three RFA ablations were performed, each lasting 20 minutes, under general anesthesia of the right dome. During the treatment, the area of tissue ablation was monitored sonographically to determine the zone of increased echogenicity. It was found to measure 7.6×3.0 cm, which corresponded to the area of tissue ablation. He has not expressed any complaint both during and after the procedure. Three days after the RFA, he was discharged. We checked the follow-up dynamic abdominal CT at 3 and 6 months after the RFA. Those showed gradual involution of the ablation zone and demonstrated no evi-

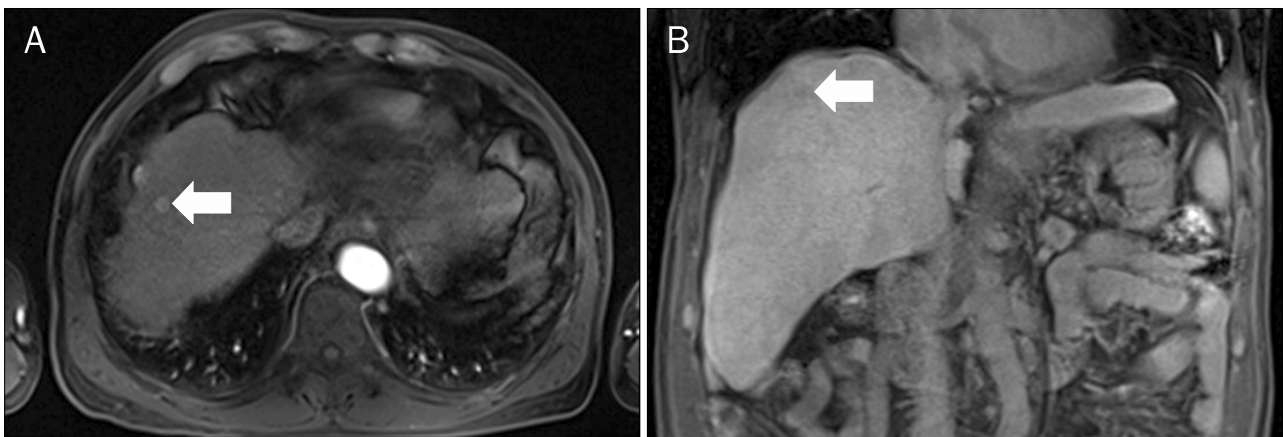


Fig. 1. Hepatocellular carcinoma in hepatic dome (segment 8). (A) Axial MRI section showing a slightly enhanced nodule in the hepatic dome (arrow) during the arterial phase. (B) Coronal T1 weighted image showing a hypointense nodule in the hepatic dome (arrow).

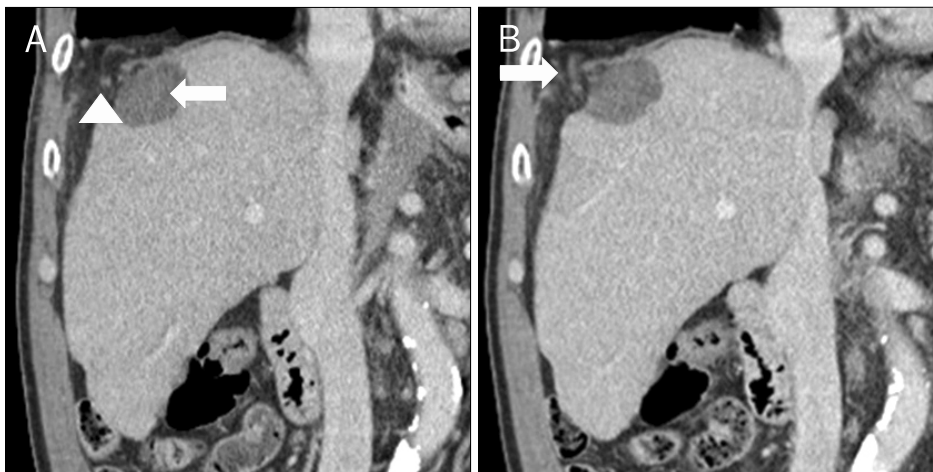


Fig. 2. Abdomen CT findings. (A) Coronal abdomen CT revealed about a 2.0 cm sized defect (arrowhead) of the diaphragm adjacent to the lesion (arrow) that was ablated. (B) Coronal abdomen CT showed herniation of mesenteric fat and blood vessels (arrow).

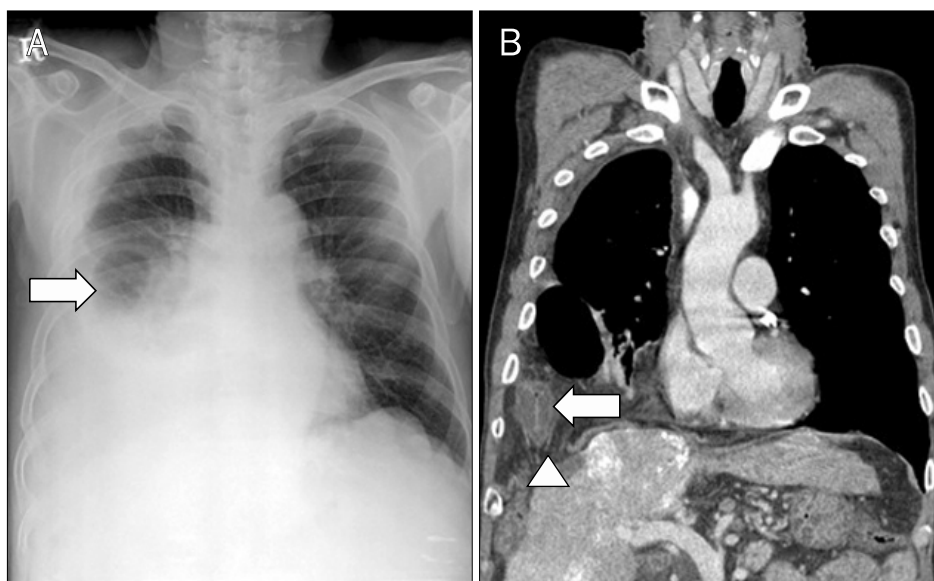


Fig. 3. Twenty-two months after radio-frequency ablation. (A) Chest X-ray showing a large amount of pleural fluid and loops of bowel (arrow) in the right pleural cavity. (B) Coronal chest CT image showing about a 4.0 cm sized defect of the diaphragm (arrow-head) and herniation of the large intestine (arrow) in the right pleural cavity.

dence of recurrent lesions nor any sign of complication.

Nine months after the RFA, a dynamic abdominal CT revealed about a 2.0 cm sized defect in the right diaphragm and herniation of the mesenteric fat and blood vessels into the right pleural cavity (Fig. 2). The defect of the diaphragm was adjacent to the HCC lesion that had been treated by RFA. He had no history of abdominal or chest injury. Because he did not complain of any symptoms, his vital signs were stable, and blood tests were within normal limits, we decided to treat the patient conservatively.

Twenty-two months after the RFA, a follow-up chest X-ray revealed loops of bowel and a pleural effusion in the right pleural cavity (Fig. 3A). A subsequent chest CT showed about a 4.0 cm sized hole in the diaphragm with herniating colon and mesentery (Fig. 3B). We recommended him to undergo surgery to close the hole in the diaphragm. However, he refused to have the surgery because he had no symptoms associated with herniation, and surgical repair for diaphragmatic hernia was a high risk operation for him. He received diuretics and albumin preparations to control the pleural effusion. A follow-up chest X-ray showed a gradual reduction in the amount of pleural fluid. During the follow-up examinations, he has remained asymptomatic.

DISCUSSION

HCC is the second most common cause of cancer related deaths and is one of the leading causes of cancer-related

morbidity in Korea. Although surgical resection has been accepted as a first line treatment for HCC, recently many clinical studies reported that RFA could be accepted as a potential alternative to surgery for small HCCs.^{6,7} However, several other studies reported that RFA rarely may induce major complications and death.³⁻⁵ Major complications were defined as those that delayed hospital discharge, threatened the patient's life, or led to substantial morbidity and disability.⁸ In a multicenter study, reported rates of mortality and major complications of RFA for HCC were about 0.15% and 4.0%.³

Complications arising from RFA can be divided into two general categories: those related to imaging guided electrode placement, and those related to thermal transmission.⁹ Even though the most common major complication due to thermal transmission was hepatic abscess in the multicenter study,³ RFA may cause thermal injury to extrahepatic structures. In our case, thermal damage due to RFA for HCC beneath the diaphragm seems to have had a major effect on the diaphragm; it can cause perforation of the diaphragm resulting in a hepatic abscess.

Since diaphragmatic hernia following RFA was first reported in 2003,⁹ four cases have been reported in the English literature (Table 1).⁹⁻¹³ All of cases had a history of liver cirrhosis, making it difficult for ablation to be performed due to the worsening poor sonic window; these patients were diagnosed by chest X-ray and CT more than 9 months after the RFA (in our patient: 9 months after the RFA).

Complications after RFA are divided into 3 types: immedi-

Table 1. Summary of the Literature of Diaphragmatic Injury Following Radiofrequency Ablation for Hepatocellular Carcinoma

Reference	Age (yr)/sex	Onset of defect (month)	CP class	Symptom	Treatment	Outcome
Koda et al. ⁹	61/F	13	B	Dyspnea	Surgery	Died 1 month after surgery
Shibuya et al. ¹⁰	72/M	18	A	Abdominal pain, dyspnea	Surgery	Alive
di Francesco et al. ¹¹	49/M	15	Unknown	Vomiting	Surgery	Alive
Yamagami et al. ¹²	71/F	9	B	No symptom	No surgery	Alive
Singh et al. ¹³	46/F	11	A	Chest pain, vomiting	Surgery	Alive

M, male; F, female; CP, Child-Pugh.

ate complications (≤ 24 hours after the procedure), peri-procedural complications (within 30 days), and delayed complications (more than 30 days).⁸ In most cases of thermal injury to the organs adjacent to the HCC, significant symptoms occurred and the diagnosis of thermal injury causing complications such as hepatic abscess and colonic perforation was made within 30 days after the procedure.¹⁴ However, our case was one of the delayed thermal complications of RFA. One case report suggested that partial thermal injury can cause an inflammatory response resulting in delayed thermal complications such as a defect in tissues.¹³ We think that this injury caused by RFA led to the diaphragmatic hernia in our case. Moreover, diabetes mellitus might have exacerbated the problem by preventing the healing process in the injured diaphragm. Another case report proposed that the poor liver function of the patient had a bad effect on the healing process in the injured diaphragm.⁹ But we thought that this was unrelated to the incidence of hernia of the diaphragm, because the Child-Pugh grading of these patients varied considerably. This is consistent with a study that showed that there was no marked difference in the incidence of complications after RFA between the Child-Pugh grade A and B groups.¹⁵ The patient reported by Yamagami et al.¹² did not complain of any symptoms related to the diaphragmatic hernia and the patient received conservative treatment as in our case. Two months after he was diagnosed with hernia of the diaphragm, he did not show any symptoms. It is thought that the severity of symptoms is the most important factor in the prognosis and treatment of this disease at the time of diagnosis.

Recently, several techniques to reduce thermal injury after percutaneous RFA for HCC adjacent to the diaphragm have been reported in recent clinical trials. Artificial pleural effusion, artificial ascites, and carbon dioxide insufflation are regarded as techniques to minimize RFA induced thermal com-

plications including diaphragmatic injury.^{16,17} Also, laparoscopic RFA could be considered to be a better and more safe treatment when percutaneous RFA is not indicated due to the tumor's relative location to adjacent structures.¹⁸ One study suggested that the placement of artificial devices should differ depending on the location of the tumor: for artificial pleural effusion, dorsal aspect of the liver surface in the right lobe, and for artificial ascites; 1) ventral aspect of the liver surface in the right lobe, 2) tumors located on the liver surface and attached to surrounding organs.¹⁹ In our case, because the lesion was located on the ventral side of the liver surface, we assumed that he should be treated by using artificial ascites to decrease the thermal damage at that time.

In summary, if percutaneous RFA to the lesion adjacent to the diaphragm is to be performed, clinicians should consider several techniques to reduce thermal injury and pay attention to the possibility of thermal induced complications arising at any point over a long period of time, and which may cause patients to undergo major surgery or even death suddenly after a long period of quiescence, in spite of its rarity.

REFERENCES

1. Rossi S, Di Stasi M, Buscarini E, et al. Percutaneous RF interstitial thermal ablation in the treatment of hepatic cancer. *AJR Am J Roentgenol* 1996;167:759-768.
2. Yan K, Chen MH, Yang W, et al. Radiofrequency ablation of hepatocellular carcinoma: long-term outcome and prognostic factors. *Eur J Radiol* 2008;67:336-347.
3. Bertot LC, Sato M, Tateishi R, Yoshida H, Koike K. Mortality and complication rates of percutaneous ablative techniques for the treatment of liver tumors: a systematic review. *Eur Radiol* 2011;21:2584-2596.
4. Park SG, Park SJ, Koo HS, et al. Biliary-duodenal fistula following radiofrequency ablation therapy for hepatocellular carcinoma. *Korean J Gastroenterol* 2008;51:199-203.
5. Kim JY, Kwon YH, Lee SJ, et al. Abscesso-colonic fistula following radiofrequency ablation therapy for hepatocellular carcinoma;

- a case successfully treated with histoacryl embolization. *Korean J Gastroenterol* 2011;58:270-274.
6. Liu JG, Wang YJ, Du Z. Radiofrequency ablation in the treatment of small hepatocellular carcinoma: a meta analysis. *World J Gastroenterol* 2010;16:3450-3456.
7. Guglielmi A, Ruzzenente A, Valdegamberi A, et al. Radiofrequency ablation versus surgical resection for the treatment of hepatocellular carcinoma in cirrhosis. *J Gastrointest Surg* 2008;12:192-198.
8. Goldberg SN, Charboneau JW, Dodd GD 3rd, et al; International Working Group on Image-Guided Tumor Ablation. Image-guided tumor ablation: proposal for standardization of terms and reporting criteria. *Radiology* 2003;228:335-345.
9. Koda M, Ueki M, Maeda N, Murawaki Y. Diaphragmatic perforation and hernia after hepatic radiofrequency ablation. *AJR Am J Roentgenol* 2003;180:1561-1562.
10. Shibuya A, Nakazawa T, Saigenji K, Furuta K, Matsunaga K. Diaphragmatic hernia after radiofrequency ablation therapy for hepatocellular carcinoma. *AJR Am J Roentgenol* 2006;186(5 Suppl):S241-S243.
11. di Francesco F, di Sandro S, Doria C, et al. Diaphragmatic hernia occurring 15 months after percutaneous radiofrequency ablation of a hepatocellular cancer. *Am Surg* 2008;74:129-132.
12. Yamagami T, Yoshimatsu R, Matsushima S, Tanaka O, Miura H, Nishimura T. Diaphragmatic hernia after radiofrequency ablation for hepatocellular carcinoma. *Cardiovasc Intervent Radiol* 2011;34(Suppl 2):S175-S177.
13. Singh M, Singh G, Pandey A, Cha CH, Kulkarni S. Laparoscopic repair of iatrogenic diaphragmatic hernia following radiofrequency ablation for hepatocellular carcinoma. *Hepatol Res* 2011;41:1132-1136.
14. Tateishi R, Shiina S, Teratani T, et al. Percutaneous radiofrequency ablation for hepatocellular carcinoma. An analysis of 1000 cases. *Cancer* 2005;103:1201-1209.
15. Curley SA, Izzo F, Ellis LM, Nicolas Vauthey J, Vallone P. Radiofrequency ablation of hepatocellular cancer in 110 patients with cirrhosis. *Ann Surg* 2000;232:381-391.
16. Uehara T, Hirooka M, Ishida K, et al. Percutaneous ultrasound-guided radiofrequency ablation of hepatocellular carcinoma with artificially induced pleural effusion and ascites. *J Gastroenterol* 2007;42:306-311.
17. Raman SS, Aziz D, Chang X, Sayre J, Lassman C, Lu D. Minimizing diaphragmatic injury during radiofrequency ablation: efficacy of intraabdominal carbon dioxide insufflation. *AJR Am J Roentgenol* 2004;183:197-200.
18. Lee SD, Han HS, Cho JY, et al. Safety and efficacy of laparoscopic radiofrequency ablation for hepatic malignancies. *J Korean Surg Soc* 2012;83:36-42.
19. Iwai S, Sakaguchi H, Fujii H, et al. Benefits of artificially induced pleural effusion and/or ascites for percutaneous radiofrequency ablation of hepatocellular carcinoma located on the liver surface and in the hepatic dome. *Hepatogastroenterology* 2012;59:546-550.