

CASE REPORT

잭해머식도를 경구내시경 근절개술로 치료한 1예

고원진, 이병무, 박원영, 김진녕, 조준형, 이태희, 홍수진¹, 조주영

순천향대학교 서울병원 소화기병센터, 순천향대학교 부천병원 소화기병센터¹

Jackhammer Esophagus Treated by a Peroral Endoscopic Myotomy

Weon Jin Ko, Byoung Moo Lee, Won Young Park, Jin Nyoung Kim, Jun-Hyung Cho, Tae Hee Lee, Su Jin Hong¹ and Joo Young Cho

Digestive Disease Center, Soonchunhyang University Hospital Seoul, Seoul, Digestive Disease Center, Soonchunhyang University Hospital Bucheon, Bucheon¹, Korea

A 49-year-old woman visited our hospital with dysphagia and chest pain. In another hospital, she was diagnosed as reflux esophagitis. Although she had taken proton pump inhibitor and prokinetics drugs for a long time, she was not relieved of any symptoms. On the basis of high resolution manometry and endoscopic ultrasonography findings, Jackhammer esophagus was diagnosed. In this patient, peroral endoscopic myotomy (POEM) was performed for long myotomy of thickened circular muscle. During the procedure, there were no significant complications and she was discharged uneventfully. Symptoms were completely improved during three months after POEM. Here, we report on a case of Jackhammer esophagus treated by POEM. (Korean J Gastroenterol 2014;64:370-374)

Key Words: Jackhammer esophagus; Peroral endoscopic myotomy; High resolution manometry; Endoscopic ultrasonography

INTRODUCTION

Esophageal hypertensive peristaltic disorder is a disease cluster of esophageal motility with increased pressure of single or multiple parts of the organ.¹ It involves many well-known esophageal disorders, like achalasia, diffuse esophageal spasm (DES), and nutcracker esophagus. It was initially hypothesized that nutcracker esophagus might represent a causal explanation for unexplained chest pain or dysphagia. However, subsequent analyses concluded that, most often, this was not the case.² A major recent advancement in clinical manometry has been the adoption of high resolution manometry (HRM).³ The Chicago Classification of esophageal motility was developed to facilitate the interpretation of clinical HRM.⁴ Jackhammer esophagus is a new

concept of disorder which can only be diagnosed by HRM. Jackhammer may be related to esophagogastric junction outflow obstruction, which may be associated with hypercontractile swallows.⁵ Meanwhile, the management of these spastic esophageal disorders is challenging, as demonstrated by the fact that pharmacologic and endoscopic therapy fail in as many as 74% of patients.⁶ As with pneumatic dilation, even a lower response rate has been observed in patients with spastic achalasia.^{7,8} Peroral endoscopic myotomy (POEM) has recently been performed for treatment of achalasia.⁹⁻¹¹ Several studies have reported on the successful treatment of patients with spastic esophageal disorder by POEM.¹²⁻¹⁴ The authors experienced a case of Jackhammer esophagus that was treated with POEM and achieved a great short-term outcome.

Received June 12, 2014. Revised July 3, 2014. Accepted July 4, 2014.

© This is an open access article distributed under the terms of the Creative Commons Attribution Non-Commercial License (<http://creativecommons.org/licenses/by-nc/3.0>) which permits unrestricted non-commercial use, distribution, and reproduction in any medium, provided the original work is properly cited.

교신저자: 조주영, 140-743, 서울시 용산구 대사관로 59, 순천향대학교 서울병원 소화기병센터 소화기연구소

Correspondence to: Joo Young Cho, Institute for Digestive Research, Digestive Disease Center, Soonchunhyang University Hospital Seoul, 59 Daesagwan-ro, Yongsan-gu, Seoul 140-743, Korea. Tel: +82-2-709-9210, Fax: +82-2-709-9696, E-mail: cjoy6695@dreamwiz.com

Financial support: None. Conflict of interest: None.

CASE REPORT

A 49-year old woman visited Soonchunhyang University Hospital Seoul for dysphagia and chest pain from which she had suffered for 10 years. In another hospital, esophagogastroduodenoscopy (EGD) and cardiologic examination showed unremarkable findings. On the diagnosis of non-erosive reflux esophagitis, she had taken a proton pump inhibitor and prokinetics drugs for a long time. However, she was not relieved of any symptoms. Chest pain characterized by burning sensation occurred intermittently, followed by dysphagia. The symptoms were prolonged for 1-4 days and relieved spontaneously. She suffered from these symptoms for more than three months per year and their frequency increased gradually. An EGD was performed and only minimal reflux

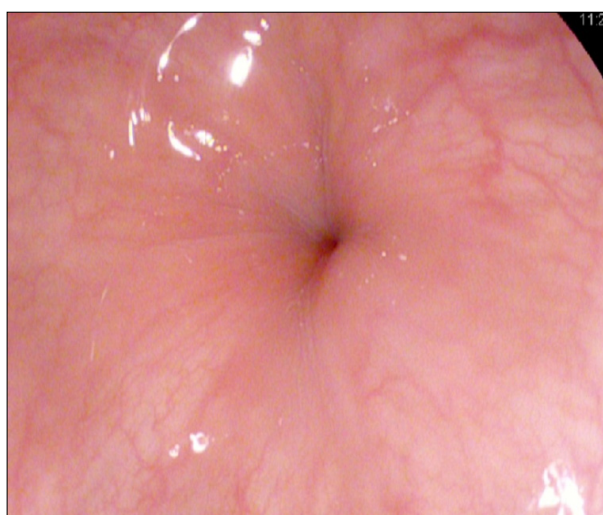


Fig. 1. The initial esophagogastroduodenoscopy. Severe esophageal contraction during the insertion is noted.

esophagitis was noted. However, a powerful contraction of the esophagus occurred abruptly, so that the scope could not be advanced or retreated (Fig. 1).

In HRM, there was an abnormal increase of mid-to-lower esophageal pressure. Upper esophageal sphincter and pharynx showed that contraction was coordinated. The resting pressure of the lower esophageal sphincter was normal with incomplete relaxation. The integrated relaxation pressure was 16.9 mmHg, whereas the normal range was less than 15 mmHg. And the esophageal body showed spastic contraction with prolonged durations and high amplitude. The distal latency was 6.0 sec, which fit within the normal range of more than 4.5 sec of contractile propagation in the distal esophagus. However, the mean distal contractile integral (DCI) was 28,449 mmHg-s-cm, whereas the normal range was 500-5,000 (Fig. 2). From the definition of Jackhammer esophagus, it was compatible with the criteria of the disease. We performed EUS and thickened inner circular muscle layer by 6 mm was noted on the same part of abnormally increased pressure in HRM at mid-to-lower esophagus (Fig. 3).

After the diagnosis, she took 2 months of per oral calcium channel blocker at the outpatient clinic. The patient experienced only minimal symptom relief but severe malaise, so that she stopped the medication by herself. For this patient, POEM was performed for long myotomy of thickened circular muscle. POEM was performed by an expert with experience of more than 30 cases of successful POEM with achalasia. The procedure was performed under general anesthesia and insufflations with carbon dioxide. Intravenous antibiotic was administered shortly before the procedure. The endoscopic procedure was performed. A mixture of sodium hyaluronate and indigo carmine was injected into the submucosa at the

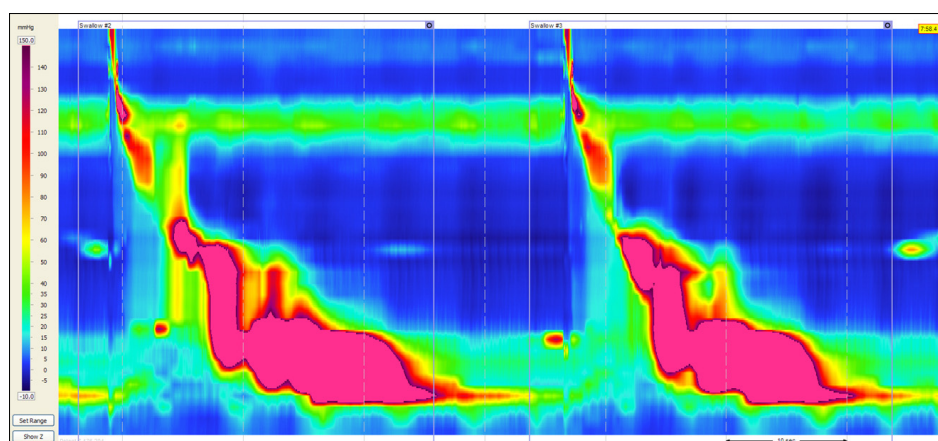


Fig. 2. The initial high resolution manometry. Abnormal pressure increase is noted below the mid-esophagus in several swallows. Mean distal contractile integral: 28,449 mmHg-s-cm, normal range: 500-5,000 mmHg-s-cm. Distal esophageal contraction pressure: 406 mmHg, normal range: 43-152 mmHg.

mid-esophagus (28 cm from the upper incisor). An approximately 2 cm longitudinal mucosal incision was made on the mucosal surface with a Dual knife (KD-650L; Olympus, Tokyo, Japan) using endo cut Q mode on effect 3 (VIO 300D; ERBE Elektromedizin GmbH, Tübingen, Germany) for creation of a mucosal entry to the submucosal space. Then, the Dual knife (spray coagulation mode at 40 W on effect 2, VIO 300D) was used to create a submucosal tunnel downwards, passing the esophagogastric junction and approximately 3 cm into the proximal stomach. Subsequently, myotomy of the circular muscle bundle using the hook knife (spray coagulation mode at 40 W on effect 2, VIO 300D) was performed from 2 cm distal site of the mucosal entry to the esophago-gastric junction. The total length of the myotomy was 15 cm (Fig. 4).

The procedure was ended with a conventional closure technique using endo-clipping. Successful closure of the mu-

cosal entry was confirmed by the endoscopic appearance. The total procedure time was 90 minutes, and there was no evidence of acute complications such as esophageal perforation or excessive bleeding. The patient recovered without any major complications and was discharged without any medications for symptom relief like calcium channel blockers. Three months after the procedure, a follow-up endoscopy and HRM was performed. An EGD showed a normal-looking esophagus, and the scope could easily be inserted and re-treated without any abnormal resistance by the contraction of the esophagus. In HRM, the mean DCI was 1,658 mmHg-s-cm, and it was within the normal range (500-5,000 mmHg-s-cm) (Fig. 5). She no longer experienced any symptoms like dysphagia and chest pain after the POEM.

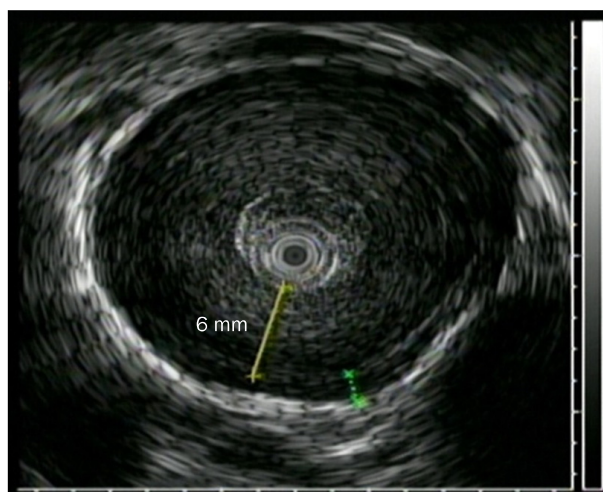


Fig. 3. The initial endoscopic ultrasonography. Esophageal inner circular muscle is thickened by 6 mm at mid to lower esophagus level.

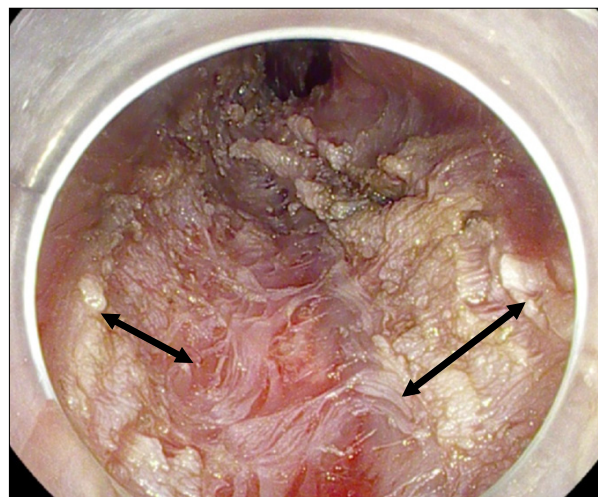


Fig. 4. Peroral endoscopic myotomy of 15-cm length is performed on the part with thickened esophageal circular muscle indicated by endoscopic ultrasonography and increased pressure by high resolution manometry. Black arrows with double heads indicate the area with myotomy.

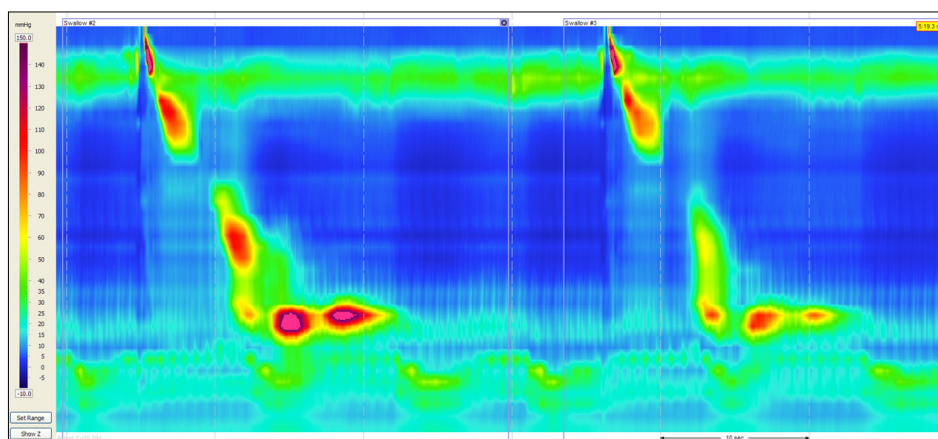


Fig. 5. Follow up high resolution manometry. Normal pattern is noted. Mean distal contractile integral after peroral endoscopic myotomy: 1,658 mmHg-s-cm, normal range: 500-5,000 mmHg-s-cm. Distal esophageal contraction pressure: 64.8 mmHg, normal range: 43-152 mmHg.

DISCUSSION

The current concept of spastic esophageal disorders has evolved to encompass spastic achalasia, DES, and jackhammer esophagus.⁴ In the era of high-resolution manometry, a new metric (DCI) is used to assess contractile vigor, and many notable advantages have been achieved in this field. The flow diagram which leads to the diagnosis of Jackhammer esophagus is as follows: esophageal hypertensive peristaltic disorders with normal lower esophageal sphincter function are divided according to two categories of DES (with premature contraction) and nutcracker esophagus (without premature contraction). If the patient's mean DCI > 5,000 mmHg-s-cm or DCI > 8,000 mmHg-s-cm without any contraction, it can be diagnosed as a nutcracker esophagus. But, if there was at least one swallow with over 8,000 mmHg-s-cm, the patient is diagnosed with Jackhammer esophagus.¹⁵ Although the definition of the disease suggests that Jackhammer esophagus could be considered as a severe form of the nutcracker esophagus, some theories attempt to separate the two categories into hypertensive peristalsis (nutcracker esophagus) and hypercontractile esophagus (Jackhammer esophagus). The pathophysiology and efficient treatment options with long term evidence are not yet clear. Many pharmacologic treatments, including nitrates, sildenafil, and tricyclic antidepressants, have been reported in the literature.⁵ However, pharmacologic and endoscopic therapy failed in as many as 74% of patients.⁶ Endoscopic botulinum toxin injection and surgical myotomy are regarded as other treatment options. However these therapies have shown a lower response rate in patients with spastic achalasia.^{7,16}

POEM has recently been performed for treatment of achalasia.⁹⁻¹¹ POEM is regarded as a potentially ideal endoscopic therapy for spastic esophageal disorders because it allows myotomy not only of the lower esophageal sphincter but also of the esophageal body, where hypertensive contractions occur. Several cases of successful treatment of patients with other spastic esophageal esophagus such as DES and nutcracker esophagus by POEM have already been reported.^{12,13} However, POEM has not been a widely chosen option yet in the treatment of Jackhammer esophagus. The reason is that this disease is a motility disorder which can affect a wide range of esophageal muscles, and the distribution could also be random. In a recent case which used POEM for

treatment of Jackhammer disease,¹⁷ a small remnant spastic segment remained, so that additional balloon dilatation was performed to relieve mild symptoms due to the segment. However, in this case, although the follow up period was shorter, the symptoms were completely resolved with POEM alone. Likewise in the treatment of achalasia or other esophageal motility disorders, an appropriate length of the myotomy is a key factor affecting the clinical response.^{12,18} By the definition of disease criteria, HRM is essential for the diagnosis of the definition of the Jackhammer esophagus, preprocedural HRM is surely the most important step. In addition, we think that the EUS also plays an important role in selection of patients who would be appropriate for POEM. Already, increased esophageal muscle thickness is likely to be an important marker of esophageal motor dysfunction.¹⁹ With the proper combination of HRM and EUS, a gastroenterologist can define the affected hypercontractile segment with more accuracy. This case is the first report mentioning the significance of EUS in Jackhammer esophagus before treatment with POEM. We hope that with these diagnostic tools, indications for POEM in Jackhammer esophagus can be expanded.

REFERENCES

1. Roman S, Tutuian R. Esophageal hypertensive peristaltic disorders. *Neurogastroenterol Motil* 2012;24(Suppl 1):32-39.
2. Agrawal A, Hila A, Tutuian R, Mainie I, Castell DO. Clinical relevance of the nutcracker esophagus: suggested revision of criteria for diagnosis. *J Clin Gastroenterol* 2006;40:504-509.
3. Fox MR, Bredenoord AJ. Esophageal high-resolution manometry: moving from research into clinical practice. *Gut* 2008;57:405-423.
4. Bredenoord AJ, Fox M, Kahrilas PJ, Pandolfino JE, Schwizer W, Smout AJ; International High Resolution Manometry Working Group. Chicago classification criteria of esophageal motility disorders defined in high resolution esophageal pressure topography. *Neurogastroenterol Motil* 2012;24(Suppl 1):57-65.
5. Roman S, Kahrilas PJ. Management of spastic disorders of the esophagus. *Gastroenterol Clin North Am* 2013;42:27-43.
6. Patti MG, Pellegrini CA, Arcerito M, Tong J, Mulvihill SJ, Way LW. Comparison of medical and minimally invasive surgical therapy for primary esophageal motility disorders. *Arch Surg* 1995;130:609-615.
7. Pandolfino JE, Kwiatek MA, Nealis T, Bulsiewicz W, Post J, Kahrilas PJ. Achalasia: a new clinically relevant classification by high-resolution manometry. *Gastroenterology* 2008;135:1526-1533.
8. Rohof WO, Salvador R, Annese V, et al. Outcomes of treatment for achalasia depend on manometric subtype. *Gastroenterology*

- 2013;144:718-725.
9. Inoue H, Minami H, Kobayashi Y, et al. Peroral endoscopic myotomy (POEM) for esophageal achalasia. *Endoscopy* 2010;42: 265-271.
10. Costamagna G, Marchese M, Familiari P, Tringali A, Inoue H, Perri V. Peroral endoscopic myotomy (POEM) for oesophageal achalasia: preliminary results in humans. *Dig Liver Dis* 2012;44: 827-832.
11. Lee BH, Shim KY, Hong SJ, et al. Peroral endoscopic myotomy for treatment of achalasia: initial results of a korean study. *Clin Endosc* 2013;46:161-167.
12. Shiwaaku H, Inoue H, Beppu R, et al. Successful treatment of diffuse esophageal spasm by peroral endoscopic myotomy. *Gastrointest Endosc* 2013;77:149-150.
13. Sharata A, Kurian AA, Dunst CM, Bhayani NH, Reavis KM, Swanstrom LL. Peroral endoscopic myotomy (POEM) is safe and effective in the setting of prior endoscopic intervention. *J Gastrointest Surg* 2013;17:1188-1192.
14. Khashab MA, Saxena P, Kumbhari V, et al. Peroral endoscopic myotomy as a platform for the treatment of spastic esophageal disorders refractory to medical therapy (with video). *Gastrointest Endosc* 2014;79:136-139.
15. Roman S, Pandolfino JE, Chen J, Boris L, Luger D, Kahrilas PJ. Phenotypes and clinical context of hypercontractility in high-resolution esophageal pressure topography (EPT). *Am J Gastroenterol* 2012;107:37-45.
16. Vanuytsel T, Bisschops R, Farre R, et al. Botulinum toxin reduces dysphagia in patients with nonachalasia primary esophageal motility disorders. *Clin Gastroenterol Hepatol* 2013;11:1115-1121.e2.
17. Kandulski A, Fuchs KH, Weigt J, Malfertheiner P. Jackhammer esophagus: high-resolution manometry and therapeutic approach using peroral endoscopic myotomy (POEM). *Dis Esophagus* 2014. doi: 10.1111/dote.12182. [Epub ahead of print]
18. Louis H, Covas A, Coppens E, Deviere J. Distal esophageal spasm treated by peroral endoscopic myotomy. *Am J Gastroenterol* 2012;107:1926-1927.
19. Dogan I, Puckett JL, Padda BS, Mittal RK. Prevalence of increased esophageal muscle thickness in patients with esophageal symptoms. *Am J Gastroenterol* 2007;102:137-145.