

New Trends in Radioiodine Treatment for the Advanced Differentiated Thyroid Cancer

Gi Jeong Cheon, M.D., Ph.D.

Department of Nuclear Medicine, Korea University Medical Center, Seoul, Korea

Iodine-131 (I-131) has been used in the therapy of well-differentiated thyroid cancer for over 60 years and has been an important component in the management of well-differentiated thyroid cancer. Differentiated thyroid carcinoma (DTC) is one of the most curable cancers, associated with a 10-year survival rate of 80~95%. Total (or near-total) thyroidectomy followed by radioiodine ablation is considered to be the ideal treatment for the high risk tumors. The selective use of radioactive iodine on the basis of clinicopathologic features that define the risk of recurrence and disease specific mortality is generally recommended in many kinds of international or institutional guidelines. However, recurrence in the thyroid bed or cervical lymph nodes develops in 5~20% of patients with DTC and some patients develop distant metastatic disease decreasing the 10-year survival of patients by 50%. Unfortunately, many of these patients ultimately die from advanced disease and other therapeutic approaches are needed. The goals of therapy for those patients should be to improve survival, relieve symptoms, and decrease the morbidity of disease progression and limit the morbidity associated with therapy. Safe practice of radioiodine treatment should be balanced with the benefit and the risk. This review will address the results of the radioiodine treatments in patients with the advanced thyroid cancer with the recent clinical trials. (*Korean J Endocrine Surg* 2011;11:139-145)

Key Words: Advanced differentiated thyroid cancer, Radioiodine treatment

INTRODUCTION

Differentiated thyroid carcinoma (DTC) is one of the most cur-

able cancers, associated with a 10-year survival rate of 80~95%.^(1,2) Total (or near-total) thyroidectomy followed by radioiodine ablation is considered to be the ideal treatment for the high risk tumors.⁽³⁾ Most patients with thyroid cancer confined to the thyroid gland or cervical lymph node metastases do very well with standard therapy including surgery, long-term levothyroxine therapy, and radioiodine remnant ablation in selected individuals.⁽⁴⁾

Iodine-131 (I-131) has been used in the therapy of well-differentiated thyroid cancer for over 60 years and has been an important component in the management of well-differentiated thyroid cancer since.^(5,6) However, recurrence in the thyroid bed or cervical lymph nodes develops in 5~20% of patients with DTC and some patients develop distant metastatic disease decreasing the 10-year survival of patients by 50%.^(3,7)

The most common sites of distant metastases from DTC are the lungs and bones followed by the brain, liver, kidneys, and muscles.⁽⁸⁻¹⁰⁾ Older patients (>45 years old) with distant metastatic thyroid cancer are classified as stage IVC by the American Joint Committee on Cancer (AJCC) criteria (sixth edition). These patients have a much more limited 5-yr survival of approximately 30~40%.^(11,12) There is good evidence that aggressive surgery, radioiodine therapy, and levothyroxine suppression therapy can improve the overall survival and disease-specific survival in this subgroup of patients.⁽¹³⁾ The therapeutic options for locally advanced or metastatic thyroid cancer not responsive to radioiodine are limited. Unfortunately, many of these patients ultimately die from advanced disease and other therapeutic approaches are needed. The goals of therapy for patients with extracervical metastases should be to improve survival, relieve symptoms, and decrease the morbidity of disease progression and limit the morbidity associated with therapy.⁽⁴⁾

ROLE OF POSTOPERATIVE RADIOACTIVE REMNANT ABLATION

Postoperative radioiodine ablation following the thyroidectomy is performed for the several theoretical reasons. Firstly, radioiodine

Correspondence: Gi Jeong Cheon, Department of Nuclear Medicine, Korea University Medical Center, 126-1 Anam-dong 5-ga, Seongbuk-gu, Seoul 136-705, Korea
Tel: +82-2-920-6607, Fax: +82-2-921-2971
E-mail: larrycheon@gmail.com

Received September 19, 2010, Revised September 23, 2011,
Accepted September 26, 2011

is used to ablate any residual remnant thyroid tissues after surgical resections, which will increase the sensitivity of the following test based on the serum thyroglobulin (Tg) measurement and radioiodine whole body scan. Secondly, the use of radioiodine may detect the unrecognized metastases and therefore help to decide the final staging of in patients with differentiated thyroid cancer.(3,6) Thirdly, it also serves as adjuvant treatment of thyroid cancer for the possibly remained residual tumors. The benefits of I-131 include the followings: [1] facilitating the interpretation of subsequent serum thyroglobulin levels, [2] increasing the sensitivity of metastatic disease detection on subsequent RAI whole-body scans, [3] maximizing therapeutic effect of subsequent therapies, [4] decreasing recurrence and disease specific mortality for unknown and known locoregional and distant metastatic disease, and [5] palliating complications of metastatic disease.(3)

RADIOACTIVE IODINE THERAPY OF METASTATIC DISEASE

The benefit of I-131 in the treatment of distant metastases has been extensively reviewed.(6,14) The following represents a summary of that review. The objectives of I-131 treatment of distant metastases are cure, control of recurrence, or palliation.(14)

Unfortunately, the literature on the effectiveness of I-131 to achieve these objectives is problematic for two reasons. First, there are no prospective studies that prove that radioiodine therapy (RAI) treatment for organ-specific distant metastases increases survival, reduces recurrence, or has significant palliative effect. This is unfortunate but is due to many reasons, including low volume of patients, difficulty in controlling the many prognostic factors (e.g., variable patterns of pulmonary metastases of single lesion to diffuse uptake to multiple bone metastases), and the long time required to follow these patients. Second, although many good retrospective studies are available, these studies have many limiting factors and are frequently contradictory.(6)

1) Lung

Several characteristics of lung metastases may predict benefits of I-131 when there is metastatic pulmonary disease (Table 1). The most prominent characteristics are as follows: presence or absence of RAI uptake of I-131, pattern on RAI uptake on whole-body scan (e.g., micronodular, macronodular, diffuse, and/or focal), size of metastases on computed tomography (CT) and chest X-ray (CXR), and uptake on F-18 fluoro-deoxyglucose (FDG) positron emission tomography (PET) (Fig. 1).(6)

The benefit of I-131 is greater if the lung metastases are RAI

Table 1. Benefit of I-131 treatment for lung metastases

	Good	←	Benefit	→	Poor
Radioiodine uptake	Yes	Yes	Yes	Yes	No
Pattern on radioiodine whole-body scan	Focal, micronodular	Diffuse, micronodular	Focal, macronodular	Diffuse, macronodular	Negative
Presence on noncontrast chest CT	Negative	Negative	Yes	Yes	Yes, large, and multiple
Presence on chest X-ray	Negative	Negative	Negative	Yes	Yes, large, and multiple
FDG uptake on PET scan	Negative	Negative	Negative	Negative	Positive

Table from Van Nostrand D. Thyroid 2009;12:1384.

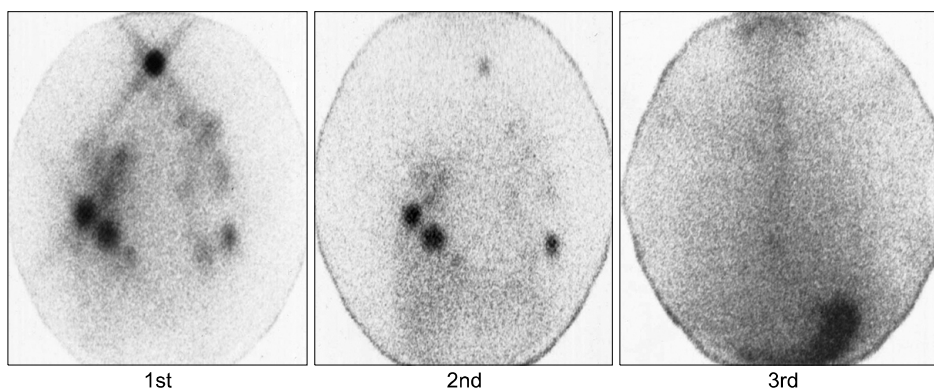


Fig. 1. Radioiodine treatment for the lung metastases. At initial radioiodine ablation therapy, numerous functioning metastatic nodules are detected on the I-131 whole body scan. After the following I-131 treatments, those metastatic lung nodules show interval decrease in number and activity.

avid than if they are not RAI avid. However, it is difficult to determine if observed benefits are due to I-131, simply because patients with iodine avid pulmonary metastases have a better prognosis even without I-131 treatment. It is known, for example, that age is an important prognostic factor, and pediatric patients with RAI-avid pulmonary metastases have an excellent prognosis, even without I-131 treatment.(15)

The pattern and size of RAI uptake may be important in regard to response to I-131. If there is a fine, diffuse pattern on RAI whole-body scan, there may be a greater benefit from I-131 administration than if the pattern is focal or coarse.(16) This may be related, at least in part, to size. Again, the difference in outcome between the two types of pulmonary metastasis may be related to their inherent prognosis, not to their response to RAI. Smaller metastases have a better response to I-131 than larger metastases are complicated by the various methods to determine size and definitions relating to size. Size has been determined by RAI whole-body scans, noncontrast CTs, chest X-rays, and even FDG PET scans. In addition to size as a factor that determines the response to I-131 there is the finding of whether the metastasis concentrates 18-FDG on PET. Thus it has been noted that uptake of 18-FDG within metastases on PET is associated with a worse prognosis and reduced response to I-131.(17,18)

In summary, the response and benefit of I-131 treatment of pulmonary metastases is variable and at least partially dependent on the degree of RAI uptake in metastases and the pattern of metastases as determined by RAI whole-body scan, size on CXR and CT, and also on the degree of uptake on F-18 FDG PET

scan.(6)

2) Bone

I-131 therapy can benefit selected patients with bone metastases. The benefit of I-131 treatment appears to be better if the bone metastases are RAI positive, fewer in number, smaller in size, and negative on X-ray. However, for a patient with a single bone metastasis, other therapies such as surgical excision, external radiotherapy, radiofrequency ablation, cryotherapy, and/or arterial embolization should be considered.(14) Little data are available comparing the benefit of I-131 treatment with standard empiric prescribed activity (e.g., 100~300 mCi [3.7~111 GBq]) as compared with the potentially higher dosimetrically determined prescribed activity of I-131. If there are multiple, extensive, RAI-negative bone metastases, I-131 treatment is not beneficial for survival or palliation.(14)

3) Brain and Rare Distant Metastasis

Although I-131 treatment of a brain metastasis may have benefit as adjuvant or palliative treatment, the probability of any significant effect is very low, and surgical excision or external radiotherapy such as g-knife should be considered first.(19,20) No significant data are available regarding the benefit or lack of benefit of I-131 therapy in patients with less frequent sites of distant metastases such as kidney, skin, muscle, liver, pancreas, and/or ovary.(6)

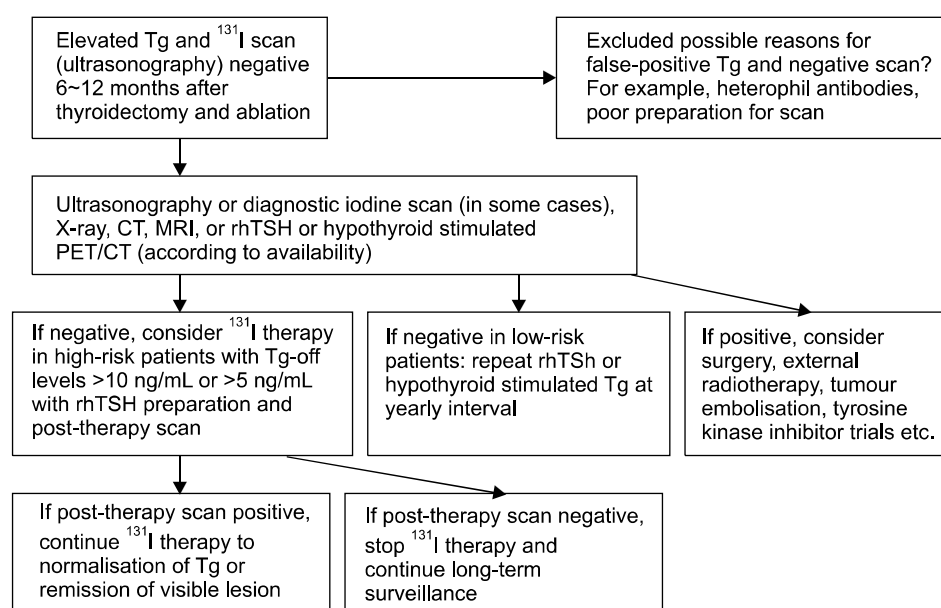


Fig. 2. Management algorithm for patients with the Tg-positive iodine-131 scans negative metastases (Fig. from Chao M. Clin Oncol 2010; 22:443).

I-131 THERAPY OF PATIENTS WITH NEGATIVE IODINE SCAN

At present, there is no consensus regarding radioiodine therapy for Tg-positive and radioiodine-negative disease. A preference for empirical I-131 therapy in patients with DTC with raised Tg and negative scan results is based on the reduction in Tg level and the increased likelihood of positive scan results after a high dose of radioiodine. Objections to empirical I-131 therapy include: some metastases may not concentrate or retain enough radioiodine to achieve a therapeutic benefit; the reductions in serum Tg levels or elimination of radioiodine uptake, visible only on posttherapy scan, are not thought to be associated with improved patient outcome. The reliability of results from current studies is limited. The management of elevated serum Tg and radioiodine negative scan is outlined in Fig. 2.(27)

Before evidence is gained from well-designed trials, in the clinical setting, it is necessary to perform noninvasive techniques to localize recurrent or metastatic lesions in patients with DTC with raised serum Tg and negative scan results. This is to enable the recommendation of surgery or external radiotherapy of the lesions when appropriate. Other diagnostic techniques such as I-123, ac-

cording to availability, are primarily useful in raised Tg and negative radioiodine metastases. The location of the Tg producing tissue should be sought using methods other than I-131 scanning, with F-18 FDG positron emission tomography under TSH stimulation being a possible first choice.(22,23) Exactly which imaging modalities should be used and when has remained uncertain.(24) When positive results are obtained from other imaging techniques, treatments such as surgery, external radiotherapy, tumor embolization or molecular targeted therapy within a trial may be considered. If the results from other imaging techniques are negative, I-131 treatment may be considered in high-risk patients with serum Tg >10 ng/mL after hypothyroid stimulation or >5 ng/mL under recombinant human TSH stimulation, which has a high predictive value for recurrence that is accepted by many investigators.(25-27) No further I-131 therapy is indicated for patients with a negative post-therapy radioiodine scan.

The definitive role of F-18 FDG PET in patients with DTC, high Tg serum levels, and negative radioiodine scan is still controversial. No consensus has been reached about Tg levels that assures high diagnostic accuracy and cost-effectiveness of F-18 FDG PET, thereby justifying the need for a PET study on a clinical basis.(28) Moreover, there is not sufficient consensus on the possible incremental value of the off-therapy state or on

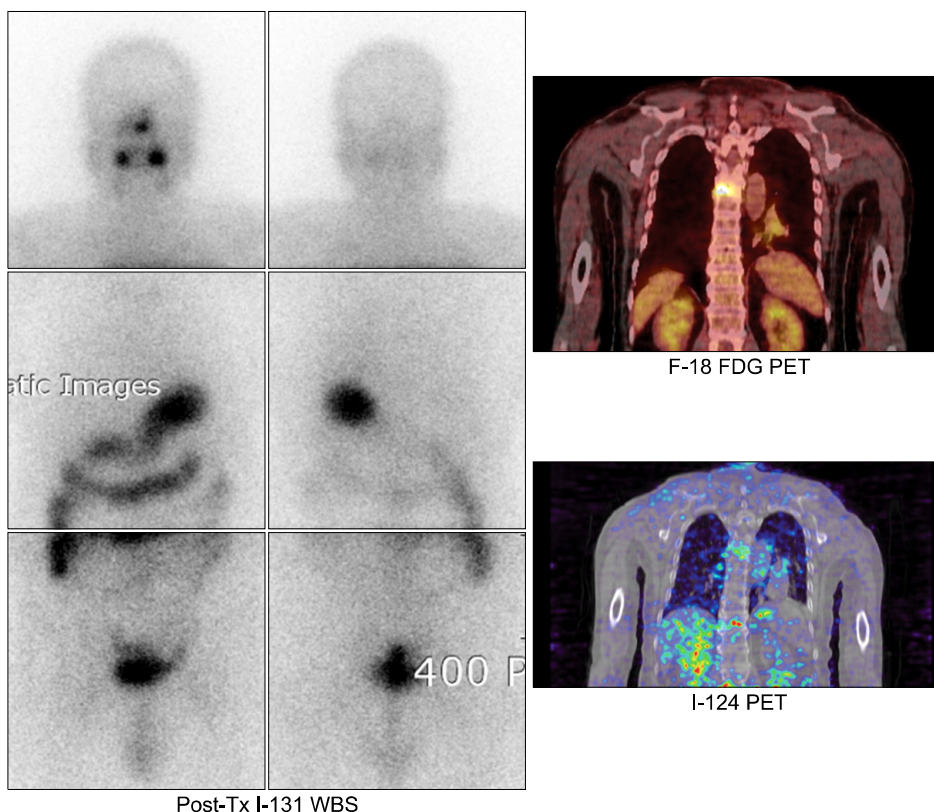


Fig. 3. Iodine scan negative and FDG PET positive metastasis. A patient with differentiated thyroid cancer after the total thyroidectomy had a bone pain in the back. Iodine scan shows negative findings. On F-18 FDG PET scan, there is a focal hypermetabolic bone lesion on the contrary, suggesting malignant tumors. Iodine-124, a PET radiotracer of isotopes of iodine, demonstrate the faint iodine uptake on PET scans. This discrepancy between the I-131 scan and I-124 PET may be caused by the difference of the resolution of the instruments. This patient underwent the following high dose radioiodine treatment with improvement of bone pain.

the use of recombinant thyrotropin stimulating hormone (rTSH) to improve the sensitivity of PET/CT imaging.(29) From the basic molecular mechanism point of view, although glucose metabolism and its relation to the mechanisms of signal transduction involved in radioiodine-negative/glucose-avid metastases of differentiated thyroid carcinomas are not completely understood, it is well established that F-18 FDG uptake by differentiated thyroid cancer is associated with more aggressive biological behavior of the tumor and a worse prognosis.(30) Moreover, high glucose transporter type 1 (GLUT-1) gene expression supports the use of PET with specific tracers in the clinical management of such cancers, and BRAF-V600E point mutations may lead to less differentiated phenotypes, less expression of NIS, suggesting a worse prognosis.(31) However, discordant findings between PET and traditional nuclear medicine radioiodine imaging (the "flip/flop phenomenon": uptake of I-131 with no FDG uptake, and vice versa) is frequently observed (Fig. 3).(32-35)

SIDE EFFECTS

The side effects of RAI therapy may occur in many areas and organ systems. These can be categorized by their time of occurrence after therapy; the early or immediate, intermediate, and late

(Table 2).(6) Although some use the categories early or later, the above periods are closer to the major clinical periods in which patients are observed. This is immediately after therapy to ~10 days after therapy, the remainder of the first year after therapy, and the long-term follow-up period. A discussion of the side effects of I-131 is complicated because so many factors affect the frequency and severity of side effects.

CONCLUSIONS

Patients with extracervical metastatic thyroid cancer present unique management challenges. Approaches to these patients may require monitoring and therapeutic tools not used in patients with typical localized disease. Radioiodine remains a mainstay of therapy in patients with radioiodine-avid metastatic disease, and this can be complemented with directed therapy.(3) The benefits of I-131 include the following: [1] facilitating the interpretation of subsequent serum thyroglobulin levels, [2] increasing the sensitivity of metastatic disease detection on subsequent RAI whole-body scans, [3] maximizing therapeutic effect of subsequent therapies, [4] decreasing recurrence and disease specific mortality for unknown and known locoregional and distant metastatic disease, and [5] palliating complications of metastatic disease.

Table 2. Side effects of I-131 treatment

	Early (~10 days)	Intermediate (~1 year)	Late (>1 year)
Salivary	Acute sialoadenitis Xerostomia	Chronic sialoadenitis Xerostomia Salivary duct obstruction	Chronic sialoadenitis Xerostomia Salivary duct obstruction
Nasal/ Eye	Abnormalities in smell Epistaxis	Xerophthalmia Epiphoria Conjunctivitis	Xerophthalmia Epiphoria Conjunctivitis
Thyroid/Parathyroid Vocal cord	Thyroiditis	Hypoparathyroidism (very rare) Recurrent laryngeal nerve injury (very rare)	
Gastrointestinal	Ageusia Nausea Vomiting Stomatitis and/or ulcers	Ageusia Abnormalities in smell	
Pulmonary		Acute radiation pneumonitis (very rare when guidelines followed) Pulmonary fibrosis (very rare when guidelines followed)	Pulmonary fibrosis
Genital Hematopoietic		Transient decreased ovarian or testicular function Neutropenia Low platelet count Anemia	Infertility Aplasia
Malignancy			Second primary malignancies

*Adopted from Van Nostrand D, Thyroid 2009.

Patients with progressive, radioiodine-resistant metastatic disease should be considered for entry into clinical trials, whereas patients with asymptomatic, stable metastatic disease may be monitored closely on levothyroxine suppression therapy. Newer targeted agents, such as sorafenib or sunitinib, may be useful in patients with progressive metastatic disease.(6)

ACKNOWLEDGEMENTS

This article was partly presented in the 1st Asian Master class of Thyroid Cancer, held in Seoul in 2011.

REFERENCES

- 1) Sampson E, Brierley JD, Le LW, Rotstein L, Tsang RW. Clinical management and outcome of papillary and follicular (differentiated) thyroid cancer presenting with distant metastasis at diagnosis. *Cancer* 2007;110:1451-6.
- 2) Shaha AR, Shah JP, Loree TR. Differentiated thyroid cancer presenting initially with distant metastasis. *Am J Surg* 1997;174:474-6.
- 3) Haq MS, Harmer C. Non-surgical management of thyroid cancer. In: Mazzaferri EL, Harmer C, Mallick UK, Kendall-Taylor P, editors. *Practical Management of Thyroid Cancer*. London: Springer; 2006. p.171-91.
- 4) Haugen BR, Kane MA. Approach to the thyroid cancer patient with extracervical metastases. *J Clin Endocrinol Metab* 2010;95:987-93.
- 5) Seidlin SM, Marinelli LD, Oshry E. Radioactive iodine therapy; effect on functioning metastases of adenocarcinoma of the thyroid. *J Am Med Assoc* 1946;132:838-47.
- 6) Van Nostrand D. The benefits and risks of I-131 therapy in patients with well-differentiated thyroid cancer. *Thyroid* 2009;19:1381-91.
- 7) Muresan MM, Olivier P, Leclère J, Sirveaux F, Brunaud L, Klein M, et al. Bone metastases from differentiated thyroid carcinoma. *Endocr Relat Cancer* 2008;15:37-49.
- 8) Haigh PI, Urbach DR, Rotstein LE. Extent of thyroidectomy is not a major determinant of survival in low- or high-risk papillary thyroid cancer. *Ann Surg Oncol* 2005;12:81-9.
- 9) Haq M, Harmer C. Differentiated thyroid carcinoma with distant metastases at presentation: prognostic factors and outcome. *Clin Endocrinol (Oxf)* 2005;63:87-93.
- 10) Qiu ZL, Luo QY. Erector spinae metastases from differentiated thyroid cancer identified by I-131 SPECT/CT. *Clin Nucl Med* 2009;34:137-40.
- 11) Sherman SI, Brierley JD, Sperling M, Ain KB, Bigos ST, Cooper DS, et al. Prospective multicenter study of thyroid carcinoma treatment: initial analysis of staging and outcome. National Thyroid Cancer Treatment Cooperative Study Registry Group. *Cancer* 1998;83:1012-21.
- 12) Sampson E, Brierley JD, Le LW, Rotstein L, Tsang RW. Clinical management and outcome of papillary and follicular (differentiated) thyroid cancer presenting with distant metastasis at diagnosis. *Cancer* 2007;110:1451-6.
- 13) Taylor T, Specker B, Robbins J, Sperling M, Ho M, Ain K, et al. Outcome after treatment of high-risk papillary and non-Hürthle-cell follicular thyroid carcinoma. *Ann Intern Med* 1998;129:622-7.
- 14) Van Nostrand D. Radioiodine treatment of distant metastases. In: Wartofsky L, Van Nostrand D, editors. *Thyroid Cancer: A Comprehensive Guide to Clinical Management*. 2nd ed. Totowa, NJ: Humana Press; 2006. p.411-27.
- 15) Massin JP, Savoie JC, Garnier H, Guiraudon G, Leger FA, Bacourt F. Pulmonary metastases in differentiated thyroid carcinoma. Study of 58 cases with implications for the primary tumor treatment. *Cancer* 1984;53:982-92.
- 16) Schlumberger M, Arcangeli O, Piekarski JD, Tubiana M, Parmentier C. Detection and treatment of lung metastases of differentiated thyroid carcinoma in patients with normal chest X-rays. *J Nucl Med* 1988;29:1790-4.
- 17) Wang W, Larson SM, Fazzari M, Tickoo SK, Kolbert K, Sgouros G, et al. Prognostic value of [¹⁸F]fluorodeoxyglucose positron emission tomographic scanning in patients with thyroid cancer. *J Clin Endocrinol Metab* 2000;85:1107-13.
- 18) Joensuu H, Ahonen A. Imaging of metastases of thyroid carcinoma with fluorine-18 fluorodeoxyglucose. *J Nucl Med* 1987;28:910-4.
- 19) Chiu AC, Delpassand ES, Sherman SI. Prognosis and treatment of brain metastases in thyroid carcinoma. *J Clin Endocrinol Metab* 1997;82:3637-42.
- 20) McWilliams RR, Giannini C, Hay ID, Atkinson JL, Stafford SL, Buckner JC. Management of brain metastases from thyroid carcinoma: a study of 16 pathologically confirmed cases over 25 years. *Cancer* 2003;98:356-62.
- 21) Chao M. Management of differentiated thyroid cancer with rising thyroglobulin and negative diagnostic radioiodine whole body scan. *Clin Oncol (R Coll Radiol)* 2010;22:438-47.
- 22) Alzahrani AS, Mohamed G, Al Shammari A, Aldasouqi S, Abdal Salam S, Shoukri M. Long-term course and predictive factors of elevated serum thyroglobulin and negative diagnostic radioiodine whole body scan in differentiated thyroid cancer. *J Endocrinol Invest* 2005;28:540-6.
- 23) Gutiérrez Cardo AL, Rodríguez Rodríguez JR, Borrego Dorado I, Navarro González E, Tirado Hospital JL, Vázquez Albertino R. Patients treated for differentiated thyroid cancer with negative 131I whole-body scans and elevated thyroglobulin levels: a possible course. *Rev Esp Med Nucl* 2007;26:138-45.
- 24) Ma C, Kuang A, Xie J, Ma T. Possible explanations for patients with discordant findings of serum thyroglobulin and ¹³¹I whole-body scanning. *J Nucl Med* 2005;46:1473-80.
- 25) Schlumberger MJ. Papillary and follicular thyroid carcinoma. *N Engl J Med* 1998;338:297-306.
- 26) Schlumberger M, Arcangeli O, Piekarski JD, Tubiana M, Parmentier C. Detection and treatment of lung metastases of differentiated thyroid carcinoma in patients with normal chest X-rays. *J Nucl Med* 1988;29:1790-4.
- 27) Ozata M, Suzuki S, Miyamoto T, Liu RT, Fierro-Renoy F, DeGroot LJ. Serum thyroglobulin in the follow-up of patients with treated differentiated thyroid cancer. *J Clin Endocrinol Metab* 1994;79:98-105.
- 28) Bertagna F, Biasotto G, Orlando E, Bosio G, Giubbini R. Role of ¹⁸F-fluorodeoxyglucose positron emission tomography/computed

- tomography in patients affected by differentiated thyroid carcinoma, high thyroglobulin level, and negative ^{131}I scan: review of the literature. *Jpn J Radiol* 2010;28:629-36.
- 29) Robbins RJ, Wan Q, Grewal RK, Reibke R, Gonen M, Strauss HW, et al. Real-time prognosis for metastatic thyroid carcinoma based on 2-[^{18}F]fluoro-2-deoxy-D-glucose-positron emission tomography scanning. *J Clin Endocrinol Metab* 2006;91:498-505.
- 30) Schönberger J, Rüschoff J, Grimm D, Marienhagen J, Rümmele P, Meyringer R, et al. Glucose transporter 1 gene expression is related to thyroid neoplasms with an unfavorable prognosis: an immunohistochemical study. *Thyroid* 2002;12:747-54.
- 31) Melck AL, Yip L, Carty SE. The utility of BRAF testing in the management of papillary thyroid cancer. *Oncologist* 2010;15:1285-93.
- 32) Feine U, Lietzenmayer R, Hanke JP, Wöhrle H, Müller-Schauenburg W. ^{18}F FDG whole-body PET in differentiated thyroid carcinoma. Flipflop in uptake patterns of ^{18}F FDG and ^{131}I . *Nuklearmedizin* 1995;34:127-34.
- 33) Feine U, Lietzenmayer R, Hanke JP, Held J, Wöhrle H, Müller-Schauenburg W. Fluorine-18-FDG and iodine-131-iodide uptake in thyroid cancer. *J Nucl Med* 1996;37:1468-72.
- 34) McDougall IR, Davidson J, Segall GM. Positron emission tomography of the thyroid, with an emphasis on thyroid cancer. *Nucl Med Commun* 2001;22:485-92.
- 35) Khan N, Oriuchi N, Higuchi T, Zhang H, Endo K. PET in the follow-up of differentiated thyroid cancer. *Br J Radiol* 2003;76:690-5.